



Review Article

Anatomical Variations of the Portal Vein in Ruminants

Reda Mohamed^{1,2*}

¹Department of Basic Veterinary Sciences, School of Veterinary Medicine, Faculty of Medical Sciences, The University of the West Indies, St. Augustine Campus, St. Augustine, Trinidad and Tobago; ²Anatomy and Embryology Department, Faculty of Veterinary Medicine, Beni-Suef University, Beni-Suef 62511, Egypt.

Abstract | The anatomical variations of the extrahepatic ramifications of the portal vein were analysed. The portal vein gives off the gastroduodenal, splenic and cranial mesenteric veins. The splenic vein continues as the left gastric vein. The right ruminal and reticular veins originate from the splenic vein. The epiploic branch originates either for the splenic or right ruminal veins. The left ruminal vein originates either from the splenic or left gastric veins. The accessory reticular and left gastroepiploic veins originate from the left gastric vein. The cranial pancreaticoduodenal, right gastric and right gastroepiploic veins detach from the gastroduodenal vein. The caudal duodenal or caudal pancreaticoduodenal, jejunal, ileal, ileocolic and caudal mesenteric veins originate from the cranial mesenteric vein. The caecal vein is considered as either as a branch of the ileocolic vein or as its direct continuation. The middle colic vein arises from either the cranial mesenteric vein, the caudal mesenteric vein or the right colic vein. The left colic and cranial rectal veins are considered branches from the caudal mesenteric vein or as its direct continuations. The sigmoid veins arise from either the left colic vein or the caudal mesenteric vein.

Editor | Muhammad Abubakar, National Veterinary Laboratories, Park Road, Islamabad, Pakistan.

Received | March 23, 2020; **Accepted** | April 13, 2020; **Published** | April 29, 2020

***Correspondence** | Reda Mohamed, Department of Basic Veterinary Sciences, School of Veterinary Medicine, Faculty of Medical Sciences, The University of the West Indies, St. Augustine Campus, St. Augustine, Trinidad and Tobago; **Email:** kkidareda@gmail.com

Citation | Mohamed, R., 2020. Anatomical variations of the portal vein in ruminants. *Veterinary Sciences: Research and Reviews*, 6(2): 64-72.

DOI | <http://dx.doi.org/10.17582/journal.vsr/2020/6.2.64.72>

Keywords | Anatomical variations, Portal vein, Ruminants

Introduction

Ruminants can successfully accommodate to different environmental conditions, which can include hot climatic conditions as well as low nutritional levels. Ruminants are of great economic value providing a good source of meat, milk and some industrial substances. The study of the pattern of the blood supply is important to gain information in the interest of pharmacology and toxicology and from a surgical perspective in ruminants (King, 1974). Metabolic wastes are carried from the tissue by thin-walled venules to the capillaries, and then the venules connect with each other thus forming the veins (Mutus, 2001). The venous blood of all unpaired abdominal organs, except the terminal part of the

rectum, is collected via the portal vein (König and Liebich, 2004). The venous drainage of the stomach and intestine of ruminates by the external root of the portal vein is described by some authors. The current work aimed to review the findings on the variability of the portal vein and its external branches among small and large ruminants. The results can be used for correlating diagnostic and surgical procedures of the liver of ruminants and in possible future publications in ruminants.

Materials and Methods

The data from 16 research papers, five on goat, one on sheep, three on ox, two on ruminants and five on camel, including full text original articles, theses and

Table 1: *Branches of the portal vein in the goat, ruminants and camel.*

Species	Author and year of publication	Main finding (A)
Goat	Horowitz and Venzke, (1966), Yadm et al. (1992), Tipidamaz et al. (1997), Constantinescu (2001) and Mohamed et al. (2016)	A. Splenic, cranial mesenteric and gastroduodenal veins
Ruminants	Ghoshal et al. (1981)	
Camel	Smuts and Bezuidenhout (1987)	

Table 2: *Branches of the splenic vein in the goat, ruminants, sheep and camel.*

Species	Author and year of publication	Main findings (A, B, C, D and E)
Goat	Horowitz and Venzke, (1966)	A. Right ruminal and reticular veins
	Mohamed et al. (2016)	B. Right ruminal, reticular and left gastric veins and as well as an epiploic branch
	Yadm et al. (1992)	C. Right ruminal, left ruminal, reticular and left gastric veins
Ruminants	Ghoshal et al. (1981)	
Sheep	Heath (1968)	D. Right ruminal vein and an epiploic branch
Camel	Smuts and Bezuidenhout (1987)	E. Left gastric and gastroduodenal veins

Table 3: *Branches of the right ruminal vein in the goat and ruminants.*

Species	Author and year of publication	Main findings (A and B)
Goat	Horowitz and Venzke, (1966) and Mohamed et al. (2016)	A. Dorsal, ventral and deep ruminal branches as well as the right ventral coronary vein
Goat	Yadm et al. (1992)	B. Dorsal and ventral branches
Ruminants	Ghoshal et al. (1981)	

Table 4: *Origin of the epiploic branch in the goat, sheep and ruminants.*

Species	Author and year of publication	Main findings (A and B)
Goat	Mohamed et al. (2016)	A. Splenic vein
Sheep	Heath (1968)	
Ruminants	Wilkens and Munster (1981)	
Goat	Horowitz and Venzke, (1966)	B. Right ruminal vein

Table 5: *Branches of the reticular vein in the goat and ruminants.*

Species	Author and year of publication	Main findings (A, B and C)
Goat	Horowitz and Venzke, (1966) and Mohamed et al. (2016)	A. Ruminal, reticular and deep branches
Goat	Yadm et al. (1992)	B. Twigs to the cardiac orifice, ruminal atrium, in addition to the adjacent portion of the dorsal ruminal sac
Ruminants	Ghoshal et al. (1981)	C. Drains the reticulum, the left wall of the rumen and the ruminal atrium

Table 6: *Branches of the left gastric vein in the goat and ruminants.*

Species	Author and year of publication	Main findings (A and B)
Goat	Horowitz and Venzke, (1966) and Mohamed et al. (2016)	A. Left ruminal, accessory reticular and left gastroepiploic veins, in addition to omasal and omasoabomasal branches
Goat	Yadm et al. (1992)	B. Right and left branches. The right branch gives off reticular branch and gastric branches while, the left branch continues as left gastroepiploic vein.
Ruminants	Ghoshal et al. (1981)	

Table 7: *Branches of the left ruminal vein in the goat and ruminants.*

Species	Author and year of publication	Main findings (A and B)
Goat	Horowitz and Venzke, (1966) and Mohamed et al. (2016)	A. Left gastric vein
Goat	Yadm et al. (1992)	B. Splenic vein
Ruminants	Ghoshal et al. (1981) in	

Table 8: *Branches of the accessory reticular vein in the goat.*

Species	Author and year of publication	Main findings (A)
Goat	Horowitz and Venzke, (1966) and Mohamed et al. (2016)	A. An omasal branch which continues to the diaphragmatic surface of the reticulum

Table 9: *Branches of the left gastroepiploic vein in the goat and ruminants.*

Species	Author and year of publication	Main findings (Aand B)
Goat	Horowitz and Venzke, (1966) and Mohamed et al. (2016)	A. Reticular, omasal, abomasal, omasoabomasal, and omental branches
Goat	Yadm et al. (1992)	B. Gastric branches to drain the omasum and abomasum as well as epiploic branches to drain the omentum
Ruminants	Ghoshal et al. (1981)	

Table 10: *Origin of the gastroduodenal vein in the goat, sheep, ox, ruminants and camel.*

Species	Author and year of publication	Main findings (Aand B)
Goat	Horowitz and Venzke, (1966), Mohamed et al. (2016) and Mohamed et al. (2017)	A. Portal vein
Sheep	Heath (1968)	
Ox	Sisson and Grossman (1969)	
Ruminants	Ghoshal et al. (1981)	
	Wilkens and Munster (1981)	
Camel	Wally (1986)	
	Smuts and Bezuidenhout (1987)	B. Splenic vein

Table 11: *Branches of the gastroduodenal vein in the goat, ruminants and camel.*

Species	Author and year of publication	Main findings (A, B and C)
Goat	Yadm et al. (1992), Tipidamaz et al. (1997), Mohamed et al. (2016) and Mohamed et al. (2017)	A. Cranial pancreaticoduodenal, right gastric and right gastroepiploic veins
Ruminants	Ghoshal et al. (1981)	
Camel	Moustafa et al. (1986)	
	Smuts and Bezuidenhout (1987)	B. Cranial pancreaticoduodenal and right gastric veins.
Goat	Horowitz and Venzke, (1966)	C. Cranial pancreaticoduodenal and right gastroepiploic veins

Table 12: *Branches of the right gastric vein in the goat, ruminants and camel.*

Species	Author and year of publication	Main findings (Aand B)
Goat	Horowitz and Venzke, (1966), Yadm et al. (1992) and Mohamed et al. (2016)	A. Abomasal and duodenal branches
Ruminants	Ghoshal et al. (1981)	
Camel	Smuts and Bezuidenhout (1987)	B. Omasal, abomasal and reticular branches

Table 13: *Branches of the right gastroepiploic vein in the goat and ruminants.*

Species	Author and year of publication	Main finding (A)
Goat	Horowitz and Venzke, (1966), Yadm et al. (1992) and Mohamed et al. (2016)	A. Abomasal, duodenal and omental branches
Ruminants	Ghoshal et al. (1981)	

Table 14: *Branches of the cranial mesenteric vein in the goat, ruminants and camel.*

Species	Author and year of publication	Main findings (A, B, C, D and E)
Goat	Mohamed et al. (2017)	A. Duodenal, jejunal, ileal, ileocolic and caudal mesenteric veins
	Yadm et al. (1992)	B. Caudal pancreaticoduodenal and caudal mesenteric veins then it trifurcates into jejunal vein, right colic vein and ileocolic vein.
	Tipidamaz et al. (1997)	C. Caudal pancreaticoduodenal, jejunal, ileal, ileocolic and right colic vein
Ruminants	Ghoshal et al. (1981)	D. Caudal mesenteric vein then it terminates by dividing into the ileocolic, right colic and ileal veins
Camel	Wally (1986)	E. Jejunal and caudal mesenteric veins

Table 15: *Number of the jejunal veins in the goat and camel.*

Species	Author and year of publication	Main findings (A, B, C and D)
Goat	Mohamed et al. (2017)	A. 24-27
	Yadm et al. (1992)	B. 17-18
	Tipidamaz et al. (1997)	C. 18-22
Camel	Wally (1986)	D. 5

Table 16: *Branches of the ileocolic vein in the goat and ruminants.*

Species	Author and year of publication	Main findings (A, B, C and D)
Goat	Mohamed et al. (2017)	A. A common trunk for both colic branches and right colic veins, in addition to last right colic vein, mesenteric ileal vein and a colic branch
	Yadm et al. (1992)	B. A colic branch, small caecal veins and ileal vein
	Tipidamaz et al. (1997)	C. Colic branches, right colic veins and caecal vein
Ruminants	Wilkins and Munster (1981)	D. A common trunk for both colic branches, and right colic veins, in addition to caecal and ileal veins

Table 17: *Origin of the common trunk for colic branches and right colic veins in the goat, ruminants and camel.*

Species	Author and year of publication	Main findings (A, B and C)
Goat	Mohamed et al. (2017)	A. Ileocolic vein
Ruminants	Wilkins and Munster (1981)	
	Ghoshal et al. (1981)	B. Cranial mesenteric vein
Camel	Smuts and Bezuidenhout (1987)	
	Wally (1986)	C. Caudal mesenteric vein

Table 18: *Origin of the caecal vein in the goat, ruminants and camel.*

Species	Author and year of publication	Main findings (A and B)
Oat	Yadm et al. (1992) and Mohamed et al. (2017)	A. Ileocolic vein
Ruminants	Ghoshal et al. (1981)	
Camel	Wally (1986)	
	Smuts and Bezuidenhout (1987)	
	Omar, 1978	B. Ileocecal vein

Table 19: *Branches of the caecal vein in the goat, ox and camel.*

Species	Author and year of publication	Main findings (A and B)
Goat	Mohamed et al. (2017)	A. Caecal and antimesenteric ileal branches
Ox	Maala and Sack (1983)	
Camel	Wally (1986)	
Goat	Yadm et al. (1992)	B. Caecal branches

Table 20: *Branches of the caudal mesenteric vein of the goat, ruminants and camel.*

Species	Author and year of publication	Main findings (A and B)
Goat	Yadm et al. (1992) and Mohamed et al. (2017)	A. Middle colic, left colic and cranial rectal veins
Ruminants	Wilkins and Munster (1981)	
Camel	Smuts and Bezuidenhout (1987)	B. Left colic and cranial rectal veins

Table 21: *Origin of the middle colic vein in the goat, ruminants, ox and camel.*

Species	Author and year of publication	Main findings (A, B and C)
Goat	Mohamed et al. (2017) and Tipidamaz et al. (1997)	A. Caudal mesenteric vein
Ruminants	Ghoshal et al. (1981)	
Camel	Omar (1978)	
	Wally (1986)	B. Right colic vein
Ox	Levine et al. (1987)	C. Cranial mesenteric vein

Table 22: *Origin of the sigmoid veins in the goat.*

Species	Author and year of publication	Main findings (A and B)
Goat	Mohamed et al. (2017)	A. Left colic vein
	Tipidamaz et al. (1997)	B. Caudal mesenteric vein

Table 23: *Origin of the cranial rectal vein in the goat, ruminants and camel.*

Species	Author and year of publication	Main findings (A and B)
Goat	Mohamed et al. (2017), Yadm et al. (1992)	A. Left colic vein
Ruminants	Ghoshal et al. (1981)	
Camel	Wally (1986)	
Goat	Tipidamaz et al. (1997)	B. Caudal mesenteric vein
Camel	Saber (1979)	

textbooks were collected either via hard copies or electronic search. The pattern of the external roots of the portal vein in the goat, sheep, ox, and camel was reviewed, organized and discussed.

Results and Discussion

The results were presented using Tables 1 to 23 which shows the type of animals (goat, sheep, ox, ruminants and camel), author, year of publication (1966-2017) and their main findings (A, B, C, D and E) and Figures 1 to 24.

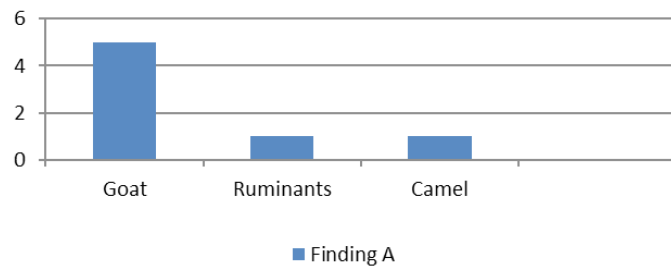


Figure 1: A graph showing the number of publications and the findings about the branches of the portal vein.

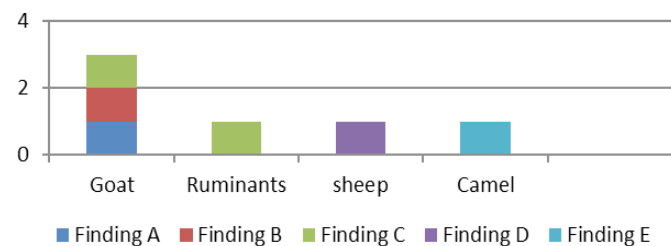


Figure 2: A graph showing the number of publications and the findings about the branches of the splenic vein.

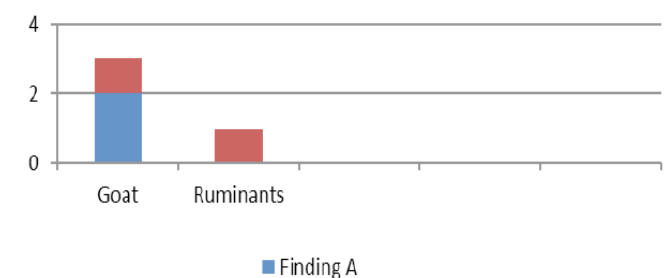


Figure 3: A graph showing the number of publications and the findings about the branches of the right ruminal vein.

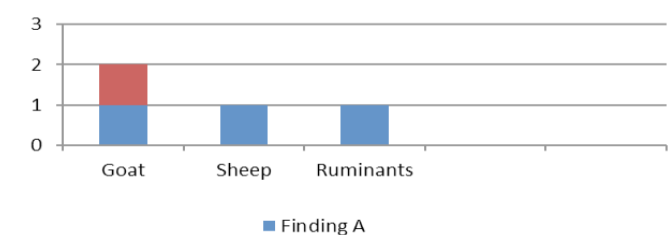


Figure 4: A graph showing the number of publications and the findings about the origin of the epiploic branch.

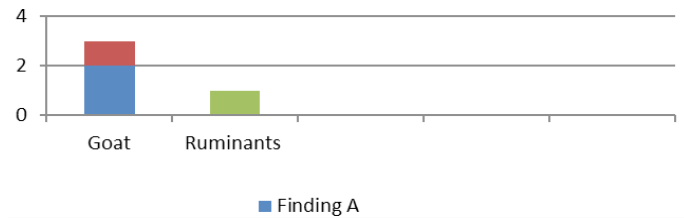


Figure 5: A graph showing the number of publications and the findings about the branches of the reticular vein.

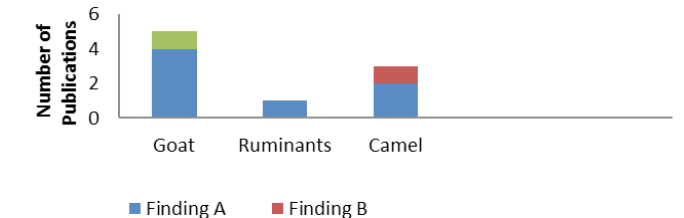


Figure 6: A graph showing the number of publications and the findings about the branches of the left gastric vein.

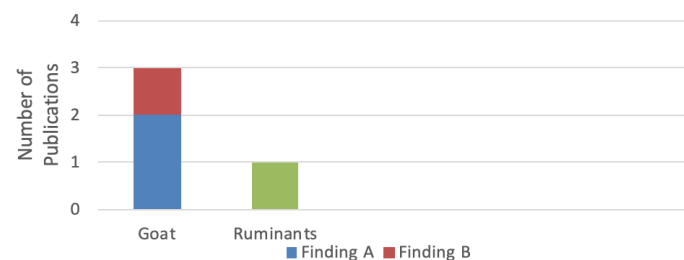


Figure 7: A graph showing the number of publications and the findings about the branches of the left ruminal vein.

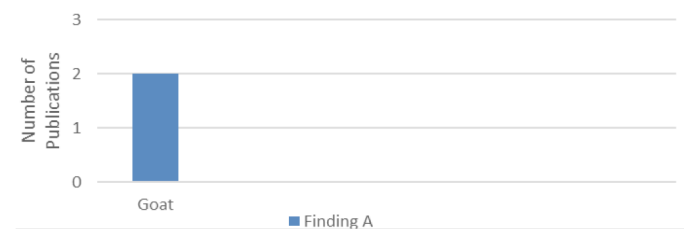

Figure 8: A graph showing the number of publications and the findings about the branches of the accessory reticular vein.

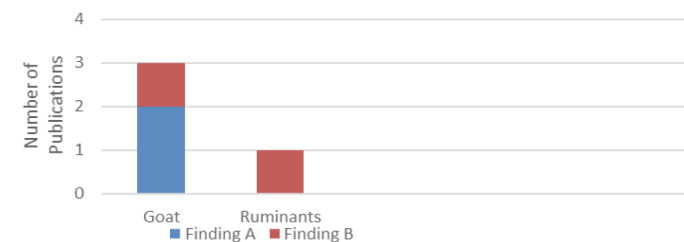


Figure 9: A graph showing the number of publications and the findings about branches of the left gastroepiploic vein.

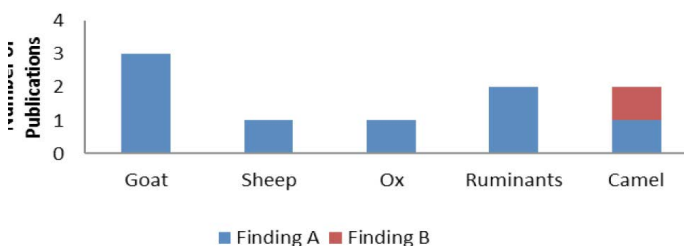


Figure 10: A graph showing the number of publications and the findings about origin of the gastroduodenal vein.

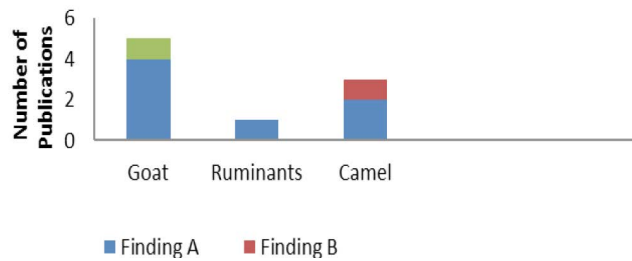


Figure 11: A graph showing the number of publications and the findings about branches of the gastroduodenal vein.

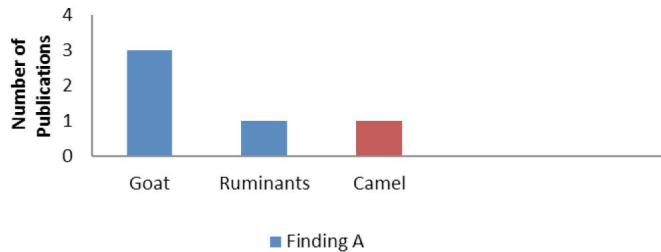


Figure 12: A graph showing the number of publications and the findings about branches of the right gastric vein.

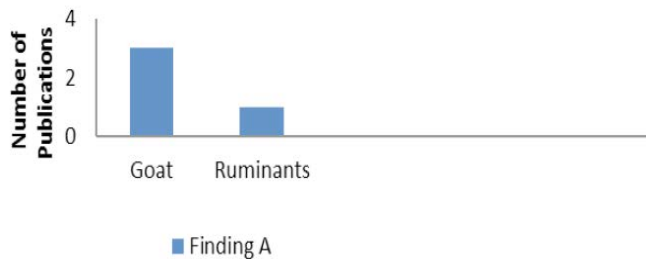


Figure 13: A graph showing the number of publications and the findings about branches of the right gastroepiploic vein.

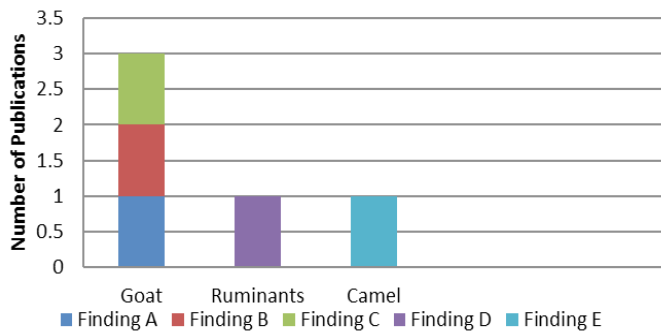


Figure 14: A graph showing the number of publications and the findings about branches of the cranial mesenteric vein.

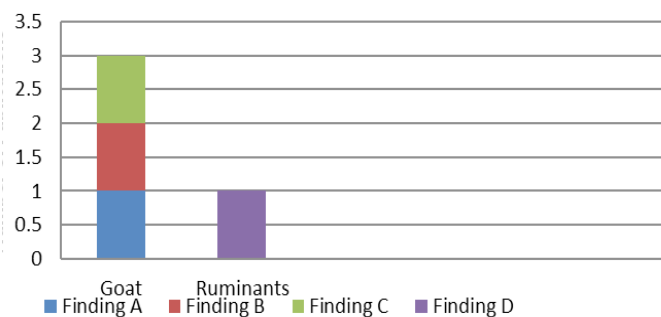


Figure 15: A graph showing the number of publications and the findings about the number of the jejunal veins.

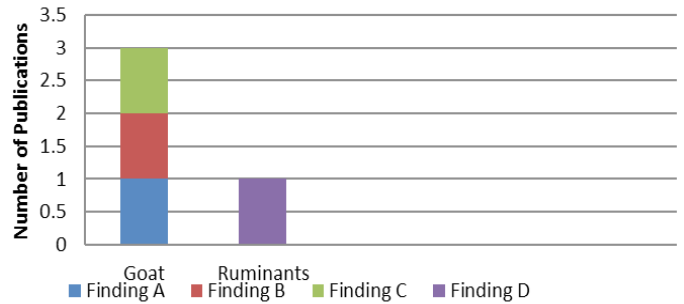


Figure 16: A graph showing the number of publications and the findings about branches of the ileocolic vein.

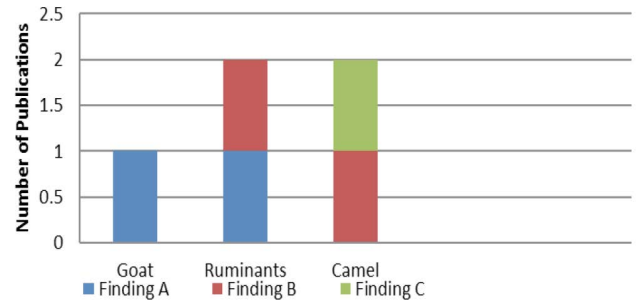


Figure 17: A graph showing the number of publications and the findings about origin of the common trunk for colic rami and right colic veins.

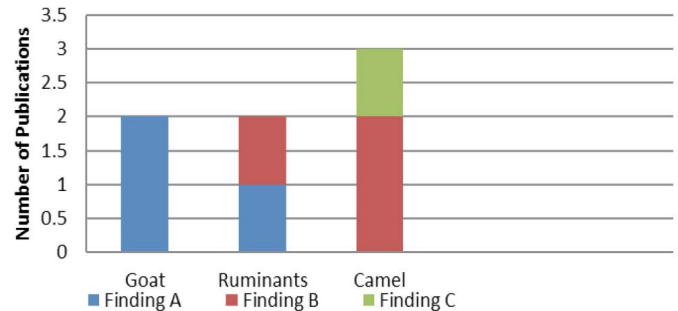


Figure 18: A graph showing the number of publications and the findings about the origin of the caecal vein.

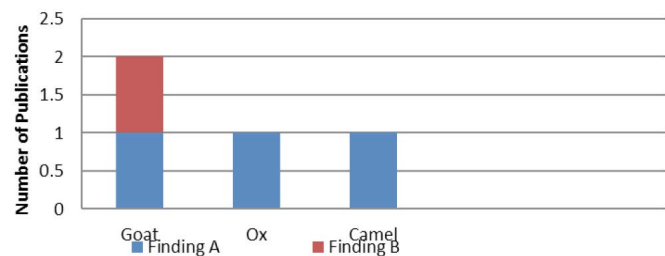


Figure 19: A graph showing the number of publications and the findings about branches of the caecal vein.

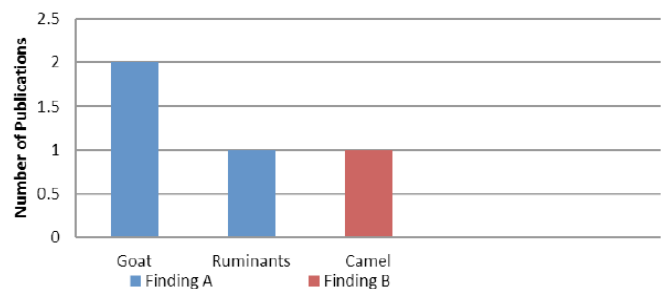


Figure 20: A graph showing the number of publications and the findings about branches of the caudal mesenteric vein.

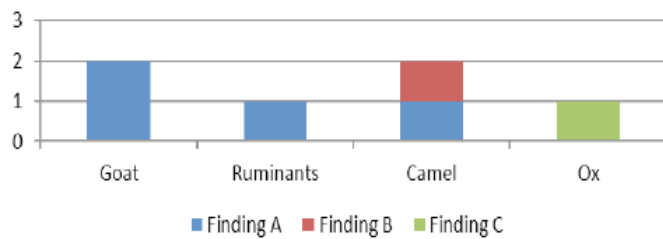


Figure 21: A graph showing the number of publications and the findings about origin of the middle colic vein.



Figure 22: A graph showing the number of publications and the findings about origin of the sigmoid veins colic.

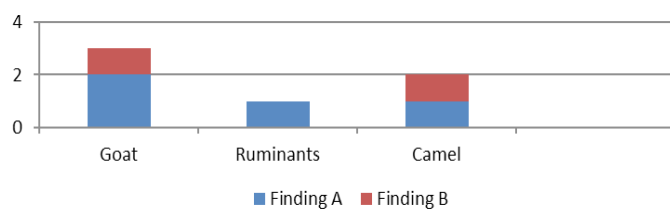


Figure 23: A graph showing the number of publications and the findings about origin of the cranial rectal vein.

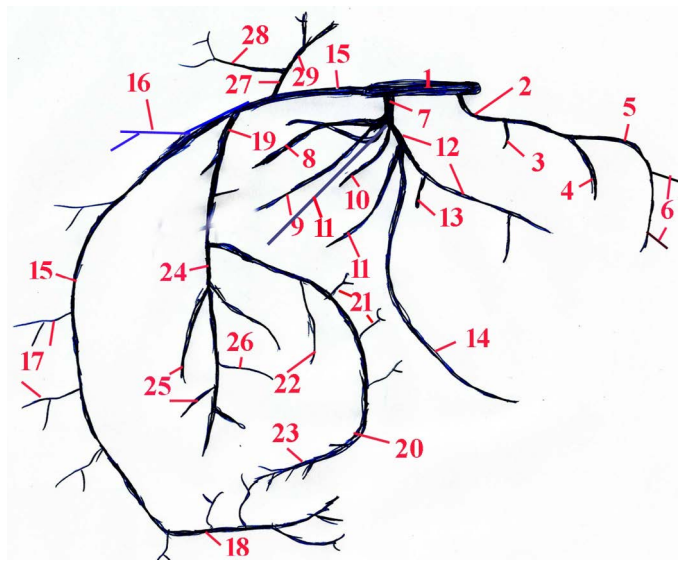


Figure 24: Schematic drawing showing the external hepatic branches of the portal vein in ruminants. 1: Portal vein; 2: Gastroduodenal vein; 3: Cranial pancreaticoduodenal vein; 4: Right gastric vein; 5: Right gastroepiploic vein; 6: Omental branches; 7: Splenic vein; 8: Epiploic branch; 9: Right ruminal vein; 10: Reticular vein; 11: Left ruminal vein; 12: Left gastric vein; 13: Accessory reticular vein; 14: Left gastroepiploic vein; 15: Cranial mesenteric vein; 16: Caudal duodenal (Caudal pancreaticoduodenal) vein; 17: Jejunal veins; 18: Ileal vein; 19: Ileocolic vein; 20: Caecal vein; 21: Caecal branches; 22: Mesenteric ileal vein; 23: Antimesenteric ileal vein; 24: A common trunk of colic branches and right colic veins; 25: Right colic veins; 26: Colic branches; 27: Caudal mesenteric vein; 28: Middle colic vein; 29: Left colic vein.

The main extrahepatic branches of the portal vein are the splenic, cranial mesenteric and gastroduodenal in the goat, ruminants and camel. The right ruminal vein originates from the splenic vein and it gives off either the right ventral coronary vein as well as the ventral, dorsal and deep ruminal branches in the goat or it gives off the ventral and dorsal branches only in the goat and ruminants. The reticular vein originates from the splenic vein and gives off the ruminal, reticular and deep branches in the goat or it gives off small branches to the ruminal atrium, cardiac orifice and the adjacent portion of the dorsal ruminal sac in the goat and ruminants. The epiploic branch arises either from the splenic vein in the goat, sheep and ruminants or from the right ruminal vein in the goat. The left ruminal vein originates either from the splenic in the goat and ruminants or from the left gastric vein in the goat. Furthermore, the left ruminal vein detaches the ventral, dorsal and deep ruminal branches in the goat.

The left gastric vein originates from the splenic vein in the goat and ruminants and it gives off the accessory reticular and left gastroepiploic veins as well as the omasal and omasoabomasal branches in the goat and ruminants. The left gastric vein terminates as a parietal and a visceral omasoabomasal branch in the goat. The accessory reticular vein originates from the left gastric vein and it detaches an omasal branch and continued to the diaphragmatic surface of the reticulum in the goat. The left gastroepiploic vein detaches the reticular, omasal, abomasal, omasoabomasal, and omental branches in the goat while, it detaches epiploic branches to drain the omentum and gastric branches to drain the omasum and abomasum in the goat and ruminants.

The gastroduodenal vein arises from the portal vein in the goat, sheep, ruminants, ox and camel, while, it arises also from the splenic vein in the camel. The cranial pancreaticoduodenal, right gastric and right gastroepiploic veins originate from gastroduodenal vein in the goat, ruminants and camel. The right gastric vein gives off the abomasal, duodenal and omental branches in the goat and ruminants while, the right gastric vein drains the lesser curvatures of the omasum, abomasum and the reticulum in the camel. Furthermore, the right gastroepiploic vein gives off the abomasal, omental and duodenal and omental branches in the goat and ruminants.

The cranial mesenteric vein detaches the caudal

duodenal, jejunal, ileal, ileocolic and caudal mesenteric veins or it gives off the caudal pancreaticoduodenal and caudal mesenteric veins then it divides into the jejunal, right colic and ileocolic veins or the cranial mesenteric detaches the caudal pancreaticoduodenal, jejunal, ileal, ileocolic and right colic veins in the goat. The cranial mesenteric vein detaches the caudal mesenteric vein then it terminates by dividing into the ileocolic, right colic and ileal veins in ruminants. However, the cranial mesenteric vein gives off the jejunal and caudal mesenteric veins in the camel. The number of the jejunal veins is either from 24-27 or 17-18 or 18-22 in the goat, while they are 5 jejunal veins in the camel.

The ileocolic vein gives off the common trunk for both colic branches and right colic veins, mesenteric ileal vein, small caecal veins and ileal vein or it gives off the colic branches, right colic veins and caecal vein in the goat, while the ileocolic vein detaches the common trunk for the colic branches and right colic veins as well as the caecal and ileal veins in the ruminants. However, the right colic vein arises also directly from the cranial mesenteric vein in the ruminants and camel, while it originates also from the caudal mesenteric vein in the camel.

The caecal vein is considered as the direct continuation of the ileocolic vein in the goat and camel. However, the caecal vein arises from the ileocolic vein in the goat, ruminants and camel, while the caecal vein arises also from the ileocecal vein in the camel. The caecal vein gives off the caecal and antimesenteric ileal branches in the goat, ox and camel. Furthermore, the caecal vein terminates as the antimesenteric ileal vein in the goat and ruminates, while the caecal vein terminates as a small branch on the free border of the jejunum in the camel.

The caudal mesenteric vein gives off the middle colic vein, and then it passes along the descending colon as the left colic vein, which detaches the sigmoid veins and terminates as the cranial rectal vein in the goat and ruminates. On the other hand, the caudal mesenteric vein gives off the left colic and cranial rectal veins in the camel. The middle colic vein arises from the caudal mesenteric vein in the goat, ruminants and camel. However, the middle colic vein originates from the right colic vein in the camel, while it originates from the cranial mesenteric vein in the ox.

The left colic vein is the direct continuation of the caudal mesenteric vein the goat and ruminants, while it arises from the caudal mesenteric vein in the goat. However, the caudal mesenteric vein becomes the left colic vein after giving off the right colic vein in the camel. The sigmoid veins arise from either the left vein or the caudal mesenteric veins in the goat. The left colic vein continues as the cranial rectal vein in the goat, ruminants and camel. However, the cranial rectal vein originates directly from the caudal mesenteric vein in the goat and camel.

Conclusion

Variation in the extrahepatic branches of the portal vein is very common in small and large ruminants. It is important to emphasize the possible variations of the extrahepatic branches of the portal vein to veterinary surgeons, as it may have implications for imaging studies and surgical interferences of the liver in ruminants.

Acknowledgments

The author is thankful to the technical staff and lab-assistants in the Veterinary Anatomy Department for their support and help.

Author Contribution

The author collected the data, carried out the research, wrote, and revised the review paper.

Conflict of interest

The author declared no conflicts of interest

References

- Constantinescu, G., 2001. Guide to regional ruminant anatomy based on the dissection of the goat. 1st ed., Iowa State Univ. Press / Ames. pp. 104 -131.
- Ghoshal, N.G., Koch, T. and Popesko, P., 1981. The venous drainage of the domestic animals. W.B. Saunders Company, Philadelphia, Toronto, Sydney. pp. 139-140; 145-147.
- Heath, T., 1968. Origin and distribution of portal vein in the sheep. Am. J. Anat. 122: 95-106. <https://doi.org/10.1002/aja.1001220106>
- Horowitz, A. and Venzke, W.G., 1966. The distribution of blood vessels of the

- postdiaphragmatic digestive tract of the goat, coeliac trunk gastroduodenal and splenic tributaries of the portal vein. *Am. J. Vet. Res.* 27: 1293-1315.
- King, A.S., 1974. A guide to the physiological and clinical anatomy of the thorax, 3rd Ed. Dep. Vet. Anat., Univ. Liverpool, Liverpool.
- König, H.E. and Liebich, H.G., 2004. Veterinary anatomy of domestic mammals. Stuttgart: Parey Buchverlag.
- Levine, S.A., Smith, D.F., Wilsman, J. and Kolb, D.S., 1987. Arterial and venous supply to the bovine jejunum and proximal part of the ileum. *Am. J. Vet. Res.* 8: 1295-1299.
- Maala, C.M. and Sack, W.O., 1983. The venous supply of the cecum, ileum and the proximal loop of the ascending colon in the ox. *Anat. Histol. Embryol.* 12: 154-166. <https://doi.org/10.1111/j.1439-0264.1983.tb01011.x>
- Mohamed, R., Adam, Z. and Gad, M., 2017. Gross anatomical studies on the venous drainage of the intestinal tract of the goat. *Int. J. Agric. Sci. Vet. Med.* 5(1): 78-86.
- Mohamed, R., Adam, Z., Gad, M. and Soliman, S., 2016. Morphological studies on the venous drainage of the stomach in goat. *Int. J. Adv. Res. Biol. Sci.* 3(8): 79-88.
- Moustafa, M.S., Abu-Zaid, S.M., EL-Nahla, S.M. and Wally, Y.R., 1986. Some anatomical observations on the venous drainage of the intestinal tract of the one humped camel (*camelus deomedarius*), Alex. J. Vet. Sci. pp. 257-269.
- Mutus, R., 2001. Macroanatomical and morphometric investigation on the maxillary vein in rabbits. *Turk. J. Vet. Anim. Sci.* 25: 803-809.
- Omar, A.M., 1978. Some anatomical studies on the portal vein of the one humped camel (*camelus dromedaries*). MVSc thesis, Zagazig Univ. Egypt.
- Saber, A.S.M., 1979. The arteries and veins of the pelvic limb of the camel with special reference to the angioarchitecture of the foot pad. PhD thesis, Assuit Univ., Egypt.
- Sisson, S. and Grossman, H., 1969. The anatomy of the domestic animals. 4th ed., W.B. Saunders Company, Philadelphia and London. pp. 726-730.
- Smuts, M.M.S. and Bezuidenhout, A.J., 1987. Anatomy of the dromedary. Clarendon Press, Oxford. pp. 156-177.
- Tipidamaz, S., Dasci, Z., Yalcin, H. and Besoluk, K., 1997. Macroanatomic investigations on the formation of the portal veins and it's intrahepatic in angora goat. *Vet. Bil. Derg.* 13: 133-138.
- Wally, Y.R., 1986. Some anatomical observations on the intestinal tract of the one humped camel (*camelus dromedarius*) MVSc thesis, Cairo Univ. Egypt.
- Wilkins, H. and Munster. 1981. The circulatory system. In Nickel, R., Schummer, A., Sieferle, E. 1981. The anatomy of the domestic animals, Berlin- Hamburg, Verlag. pp. 159-1268.
- Yadm, Z.A., Gad, M.R. and Ragab, G.A., 1992. Venous drainage of the gastrointestinal tract in the goat. *Beni-Suef Vet. Med. J.* 40: 129-136.