



Growth Performance of *Labeo rohita* Fingerlings Fed with Probiotic Added Plant By-Products Based Feeds

Sadaf Aman¹, Fouzia Tabssum², Ali Hussain³, Shamsa Jabeen¹ and Javed Iqbal Qazi^{1*}

¹Institute of Zoology, University of the Punjab, Lahore 54590, Pakistan

²Department of Zoology, University of Education, Bank-Road Campus, Lahore, Pakistan

³Department of Wildlife and Ecology, University of Veterinary and Animal Sciences, Lahore, Pakistan

ABSTRACT

The current study was carried out to investigate growth performance of *Labeo rohita* fingerlings fed with *Lactobacillus rhamnosus* supplemented plant by products based feeds. The study comprised of two experimental and one control groups. In treatment 1 (T₁), fish were fed with soybean meal along with *L. rhamnosus*. In treatment 2 (T₂), fish were fed with sunflower meal along with *L. rhamnosus*. The control group was served with commercial feed. Initial mean weights of the experimental fish was recorded as 40.00 ± 1.00, 40.33 ± 0.76 and 40.01 ± 1.00 g for T₁, T₂ and control groups, respectively. The highest weight gain was found in T₁ (747.96 ± 1.9 g) and control group (479.35 ± 1.8 g). Significant differences were found in the feed conversion ratio between control group (2.02 ± 0.07), T₁ (1.48 ± 0.03) and T₂ (1.47 ± 0.02). Survival remained 100% in all the treatments. Water quality parameters differed insignificantly for different treatment groups and remained in favorable range throughout the study period. All the treatments showed lower values of fat contents and higher values of crude protein. No negative change was observed in the histological parameters of the liver and intestinal tissues for the fishes fed with plant based feeds added with probiotics. Conclusively, fish production can be enhanced with the addition of probiotics in the feed derived from plants.

Article Information

Received 24 February 2022

Revised 25 April 2022

Accepted 11 May 2022

Available online 30 August 2022
(early access)

Published 25 February 2023

Authors' Contribution

SA performed all experiments. FT worked on collecting and arranging data. AH drafted manuscript. SJ helped in statistical analysis and compilation of data. JIQ supervised the work.

Key words

Economical aquaculture, Feed formulation, Fish feed, Microbial biotechnology, Probiotics

INTRODUCTION

Aquaculture sector is facing difficulty in development due to expensive feed stuff which is vital to increase the fish production. Feed cost in aquaculture industry represents over 50% of the total cost which in turn depends on different factors like source, kind of ingredients, crude protein level and formulation practices which affect the lipid profile, vitamins and mineral content of fish produced and ultimately the consumer demand (Prabu *et al.*, 2017). Cost-effective feed ingredients which are easily available on demand from market and well suited for fish types to be cultured can play vital role in the development of aquaculture sector (Iqbal *et al.*, 2015; Mishra *et al.*, 2022).

Suitable plants-based by-products can replace expensive animal-based feed ingredients without compromising the growth, enzymatic efficiency, survival rate of fish and its resistance against various infectious diseases (Fraga-Corral *et al.*, 2022). Probiotics as biotherapeutic agents have been used to promote health benefits since long. Reported health benefits associated with daily consumption of probiotics include their anticancer, antioxidant, hypoglycaemic, immunomodulatory potential amelioration of arthritis and cholesterol reduction (El-Kady *et al.*, 2022; Thatcher *et al.*, 2022; Tran *et al.*, 2022).

Probiotics can reduce the cost and can easily improve the growth and feed conversion efficiency of fish (Swain *et al.*, 1996; Bogut *et al.*, 1998; Ghosh *et al.*, 2003; Carnevali *et al.*, 2006; Yanbo and Zirong, 2006; Mazurkiewicz *et al.*, 2007; Kesarcodi-Watson *et al.*, 2008). Many probiotics are being used in aquaculture but lactic acid bacteria (LAB) are the most prominent one as they build natural intestinal microflora of a healthy fish (Noh *et al.*, 1994; Brunt and Austin, 2005; Nayak *et al.*, 2007; Wang, 2007, 2011; Yin *et al.*, 2007; Ramakrishnan *et al.*, 2008). Keeping in view the health benefits and productive utility of probiotics in aquaculture, the current study was planned to explore benefits of *Lactobacillus rhamnosus* (NR-113332.1)

* Corresponding author: qazi.zool@pu.edu.pk
0030-9923/2023/0003-1059 \$ 9.00/0



Copyright 2023 by the authors. Licensee Zoological Society of Pakistan.

This article is an open access article distributed under the terms and conditions of the Creative Commons Attribution (CC BY) license (<https://creativecommons.org/licenses/by/4.0/>).

supplementation in plant based feeds on growth, feed conversion ration and intestinal health of *Labeo rohita* fingerlings. The findings of this study will be helpful for replacing the commercial expensive feed with the experimentally validated feed with higher yields.

MATERIALS AND METHODS

Experimental design

The fish fingerlings for the experimental trial were obtained from Fisheries Research Institute, Manava, Lahore and the experimental trial was carried out in Microbial Biotechnology Laboratory, Institute of Zoology, University of the Punjab, Lahore. The fishes were divided into two different treatment groups on the basis of feeding with and without different diets made from different kinds of plant based ingredients with the addition of probiotic (*L. rhamnosus*) in soybean and sunflower based feeds. Control group was fed with commercial feed. One hundred and eighty fish individuals were stocked in 9 aquaria ($60.96 \times 55.88 \times 40.64$ cm). Twenty fishes (weighing between 25 to 40 g) were stocked in each group. Before stocking, the fish were treated with KMnO_4 . In treatment group 1 (T_1), fish were fed with soybean meal along with *L. rhamnosus* (NR-113332.1). In treatment group 2 (T_2), fish were fed with sunflower meal along with *L. rhamnosus*. The control group was served with commercial feed. All the fish were carefully weighed during the trial to verify the result of feed on growth. Feed was readjusted after every fortnight sampling.

Feed formulation

Plant based feeds; soybean meal and sunflower meal having 30% CP level with the addition of probiotics *L. rhamnosus* (NR-113332.1) were used (Table I). The control group was fed with commercial feed. The fish were fed for three months at rate of 3% fish wet body weight twice a day.

Feeding procedure

Fish were fed twice a day (morning and afternoon) at the rate of 3% of body weight of fish. Fish feed quantity was recalculated after fortnight sampling.

Growth study

Before stocking the fish, initial weight and length were measured. At the end of the experimental trial, final gain in weight, feed conversion ratio (FCR), percentage weight gain, net gain in weight and specific growth rate (SGR) were calculated.

Table I. Percentage ingredient contribution of different plant based experimental feeds.

Ingredients	Control group (Commercial feed)	Treatment 1 (Soybean based feed + <i>L. rhamnosus</i>)	Treatment 2 (Sunflower based feed + <i>L. rhamnosus</i>)
Fish meal	25	12	12
Sunflower meal	--	-	60
Soybean meal		56	-
Rice polish	30	12	8
Wheat flour	30	10	10
Fish oil	5	3	3
Vitamin premix	2	1	1
Minerals	2	1	1
Ascorbic acid	2	1	1
Chromic oxide	2	1	1
Citric acid	2	3	3
<i>L. rhamnosus</i>	-	3×10^8 C.F.U/g of feed	3×10^8 C.F.U/g of feed
Total	100	100	100

The mixed feed ingredients were formulated in pelleted form to a particulate size of 2mm by a pelleting machine. The air-dry product was packed in opaque and well-sealed plastic zipper packets till further use.

Histological analysis

The fish were dissected to get liver and gut (intestine). Both these samples were preserved in 4% formalin. Histology was carried out to determine the effects of probiotic on liver and intestine of fish. The tissues were routinely dehydrated through different ethanol grades, absolute ethanol and xylene. The tissue sections were prepared following Qin *et al.* (2018). The wax embedded tissues' sections (8 μm) were cut with the help of a microtome. The sections were subsequently stained with hematoxylin and eosin and studied microscopically. Photomicrographs of the representative sections were taken with the help of a camera fitted microscope.

Periodic physicochemical analysis

Dissolved oxygen, temperature and pH were recorded on daily basis by using multi meter. Nitrates and phosphates were recorded using HANNA Nitrate Test Kit HI3874.

Statistical analysis

Analysis of variance ANOVA was applied on the data obtained to compare the means by using statistical software SAS 9.1.

RESULTS AND DISCUSSION

Fish growth analysis

The highest weight gain 747.96 ± 1.9 was observed in T_1 , followed by T_2 (657.01 ± 1.6) as compared to the control value of 479.3 ± 1.8 (Table II). Maximum gain in length was measured as 5.33 ± 0.29 , 5.67 ± 0.43 , 3.83 ± 0.29 for T_1 , T_2 and control group, respectively. Statistically significant differences of length increase were observed among the control group, T_1 and T_2 (Table II). Our results were similar with Saghaei *et al.* (2015) who described the effect of garlic (*Allium sativum*) on Oscar fish (*Astronotus ocellatus*) growth performance and body compositions. They reported that highest protein content was attained in the fish fed with 10 g/kg of garlic powder. Our results were also supported by Tihamiyu *et al.* (2016) who reported that feeding *Oreochromis niloticus* with 55% substitution of *Moringa oleifera* meal for soybean meal presented the best growth results and nutrients utilization. Gradual decrements in the growth performance suggested that *M. oleifera* should be added less than 7.34%. Mohanty *et al.* (1996) showed feeding with addition of probiotics and yeast resulted in higher survival rate, better immunity and increase in body weight gain and nutrient utilization in thaila (*Catla catla*). Yanbo and Zirong (2006) reported that the survival of fish, gain in weight and nutrient utilization of fish depend on the type of probiotics used in fish feed.

Table II. Growth of *L. rohita* fed with *L. rhamnosus* supplemented soybean based meal and sunflower based meal.

Parameter (%)	Control	Treatment 1	Treatment 2
Initial weight (g)	$40.01^a \pm 1.00$	$40.00^a \pm 1.00$	$40.33^a \pm 0.76$
Final weight (g)	$231.67^a \pm 1.08$	$339.00^c \pm 1.07$	$305.00^c \pm 0.78$
%Gain in weight	$479.35^a \pm 1.8$	$747.96^c \pm 1.9$	$657.01^c \pm 1.6$
Initial length (cm)	$13.17^a \pm 0.29$	$13.83^c \pm 0.28$	$13.33^b \pm 0.58$
Final length (cm)	$17.00^a \pm 0.01$	$19.17^c \pm 0.02$	$19.01^c \pm 0.01$
Increase in length (cm)	$29.16^a \pm 1.79$	$38.58^c \pm 2.2$	$42.67^c \pm 1.03$
FCR	$2.02^c \pm 0.07$	$1.48^a \pm 0.03$	$1.47^a \pm 0.02$
SGR (%)	$0.64^a \pm 0.02$	$0.81^c \pm 0.01$	$0.75^c \pm 0.01$

Values represent Mean \pm S.D. of triplicates. Those having different superscripts in a row are significantly different from each other $P \leq 0.05$

Physicochemical parameters

Non-significant differences were recorded in all the treatment groups. Temperature in all the treatment groups as well as control group fluctuated between 25 to 27°C throughout the experimental period. Throughout the experiment, DO remained within favorable range from

6.5 to 7 mg/L. During the whole experimental period, pH remained neutral. Non-significant differences were also observed for the nitrates and phosphates contents of water among all the treatment groups.

Body composition of fish

At the end of the experimental trial, fish were processed for proximate analysis. Maximum crude protein (66.49 ± 0.14) was observed in T_2 and was remarkably different from that of control group. Significantly higher fat contents up to 9.15 ± 0.05 were found in control group, whereas the respective values for T_1 and T_2 were 6.23 ± 0.15 and 6.67 ± 0.12 . Ash contents were appeared as 23.40 ± 0.06 , 21.33 ± 0.21 and 21.57 ± 0.06 in control group, T_1 and T_2 , respectively. Moisture contents were appeared as 8.74 ± 0.21 , 8.66 ± 0.17 and 9.35 ± 0.09 in control group, T_1 and T_2 , respectively. Dry matter of fish sample showed non-significant ($P > 0.05$) differences among all the treatment groups (Table III).

Table III. Whole-body composition of *L. rohita* fed with *L. rhamnosus* supplemented soybean based meal and sunflower based meal.

Parameter (%)	Control	T_1	T_2
CP	$63.87^a \pm 0.40$	$66.22^c \pm 0.02$	$66.49^c \pm 0.14$
Fat	$9.15^c \pm 0.05$	$6.23^a \pm 0.15$	$6.67^a \pm 0.12$
Ash	$23.40^c \pm 0.06$	$21.33^a \pm 0.21$	$21.57^a \pm 0.06$
Moisture	$8.74^b \pm 0.21$	$8.66^a \pm 0.17$	$9.35^b \pm 0.09$
Dry matter	$91.26^b \pm 0.21$	$91.34^b \pm 0.17$	$90.65^a \pm 0.09$

Values represent Mean \pm S.D. of triplicates. Those having different superscripts in a row are significantly different from each other $P \leq 0.05$

Histological analysis

Normal pattern of hepatocytes was observed in the control as well both the experimental groups. Whereas, normal appearance of tunica mucosa, serosa layers and villi made the folds thicker in the probiotics supplemented fish. Intestines of the fish fed with probiotics showed relatively well-developed villi and epithelial layers (Figs. 1-3).

In control group, the intestine showed normal appearance of serosa layers and villi structure (Fig. 3). Bamidele *et al.* (2015) observed the liver and intestine health by replacing soybean meal (T_1) 0, (T_2) 25, (T_3) 50, (T_4) 75 and (T_5) 100% with moringa meal at 40 % CP. He reported T_1 group showed no visible degeneration with normal intestine and liver. T_2 and T_3 showed degeneration of hepatocytes in liver. T_4 and T_5 showed severe degeneration and intestinal necrosis which had been explained due to excessive work required by the fish liver to get rid of the plant toxicant from its body during

the process of detoxification. It is well known that liver is the main organ for detoxification. No negative change in the histological parameters of the liver tissue as well as the intestinal tissue for the fishes fed with probiotic plant based feeds was observed in the present study.

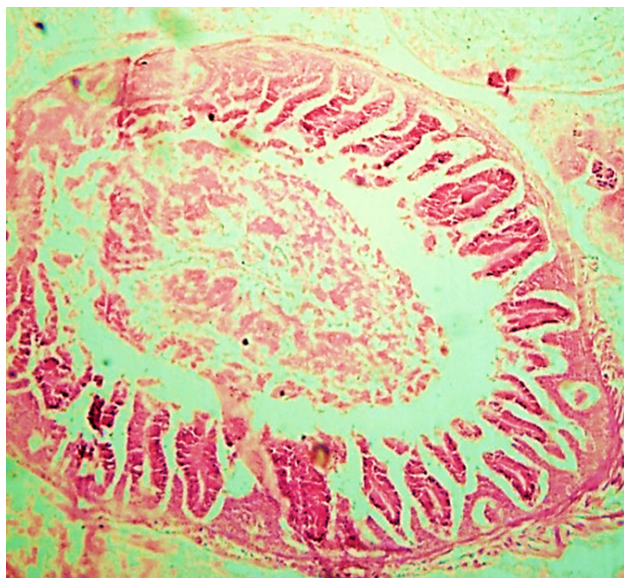


Fig. 1. Cross section of intestine of *L. rohita* fed with Soybean based feed supplemented with *L. rhamnosus* showing normal appearance of tunica mucosa, serosa layers and villi (100X).

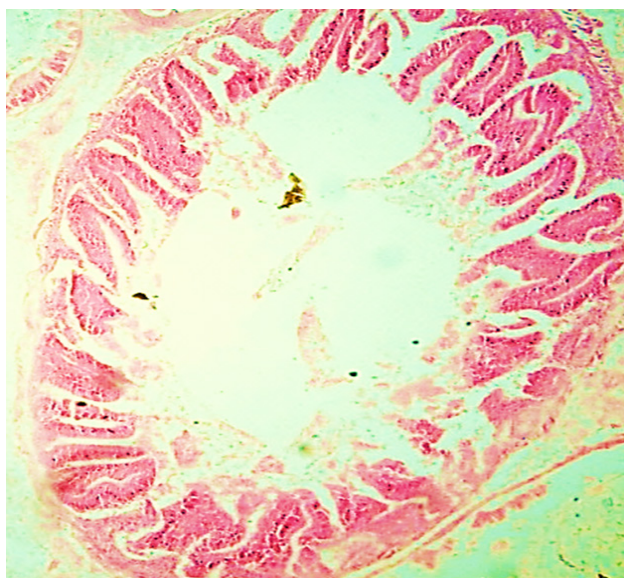


Fig. 2. Cross section of intestine of *L. rohita* fed with Sunflower based feed supplemented with *L. rhamnosus* showing normal appearance of connective tissues of villi, tunica mucosa, muscularis and serosa layers (100X).

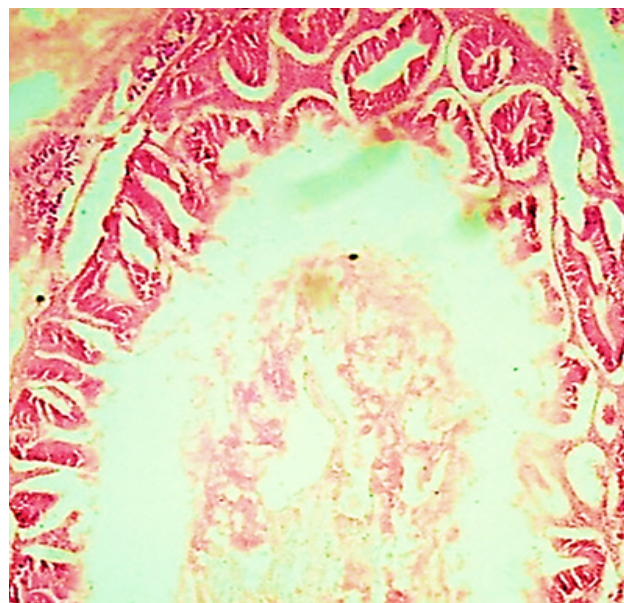

Fig. 3. Cross section of intestine of *L. rohita* fed with commercial feed showing normal appearance of serosa layers and villi (100X).

CONCLUSIONS

Our research suggested that *L. rhamnosus* can be used safely for employing plant based products feeds for sustaining or even escalating growth without any harmful and damaging effect on body composition of *L. rohita*.

ACKNOWLEDGEMENTS

The institutional support of Fisheries Research Institute, Manava, Lahore, for providing fish fingerlings is highly acknowledged.

Statement of conflict of interest

The authors have declared no conflict of interest.

REFERENCES

- Bamidele, N.A., Obasa, S.O., Ikeiwenwe, N.B., Abdulraheem, I., Adeoye, A.A. and Odebiyi, O.C., 2015. Effect of dried moringa (*Moringa oleifera*) seed meal-based diets on the growth, hematology, biochemical parameters and histopathology of the African catfish, *Clarius gariepinus* fingerlings. *Int. J. Fish. aquat. Stud.*, 2: 27-34.
- Bogut, I., Milakovic, Z., Bukvic, Z., Brkic, S. and Zimmer, R., 1998. Influence of probiotic *Streptococcus faecium* M74 on growth and content

- of intestinal micro-flora in carp *Cyprinus carpio*. *Czech J. Anim. Sci.*, **43**: 231-235.
- Brunt, J. and Austin, B., 2005. Use of a probiotic to control *Lactococcosis* and *Streptococcosis* in rainbow trout *Oncorhynchus mykiss*. *J. Fish Dis.*, **28**: 693-701. <https://doi.org/10.1111/j.1365-2761.2005.00672.x>
- Carnevali, O.D., Sulpizio, L., Gioacchini, R., Olivotto, I.G. and Silvi, S., 2006. Growth improvement by probiotic in European sea bass juveniles with particular attention to IGF-1, myostatin and cortisol gene expression. *Aquaculture*, **258**: 430-438. <https://doi.org/10.1016/j.aquaculture.2006.04.025>
- El-Kady, A.A., Magouz, F.I., Mahmoud, S.A. and Abdel-Rahim, M.M., 2022. The effects of some commercial probiotics as water additive on water quality, fish performance, blood biochemical parameters, expression of growth and immune-related genes, and histology of Nile tilapia (*Oreochromis niloticus*). *Aquaculture*, **546**: 737249. <https://doi.org/10.1016/j.aquaculture.2021.737249>
- Fraga-Corral, M., Ronza, P., Garcia-Oliveira, P., Pereira, A.G., Losada, A.P., Prieto, M.A., Quiroga, M.I. and Simal-Gandara, J., 2022. Aquaculture as a circular bio-economy model with Galicia as a study case: How to transform waste into revalorized by-products. *Trends Fd. Sci. Technol.*, **119**: 23-35. <https://doi.org/10.1016/j.tifs.2021.11.026>
- Ghosh, K., Sen, S.K. and Ray, A.K., 2003. Supplementation of an isolated fish gut bacterium, *Bacillus circulans*, in formulated diets for Rohu (*Labeo rohita*) fingerlings. *Isr. J. Aquacult.*, **55**: 13-21. <https://doi.org/10.46989/001c.20335>
- Iqbal, K.J., Ashraf, M., Qureshi, N.A., Javid, A., Abbas, F., Hafeez-ur-Rehman, M., Rasool, F., Khan, N. and Abbas, S., 2015. Optimizing growth potential of *Labeo rohita* fingerlings fed on different plant origin feeds. *Pakistan J. Zool.*, **47**: 31-36.
- Kesarcodi-Watson, A., Kaspar, H., Lategan, M.J. and Gibson, L., 2008. Probiotics in aquaculture: the need, principles and mechanisms of action and screening process. *Aquaculture*, **274**: 1-14. <https://doi.org/10.1016/j.aquaculture.2007.11.019>
- Mazurkiewicz, J., Przybyl, A., Sip, A. and Grajek, W., 2007. Effect of *Carnobacterium divergens* and *Enterococcus hirae* as probiotic bacteria in feed for common carp (*Cyprinus carpio* L). *Arch. Polish Fish.*, **15**: 93-102.
- Mishra, B., Tiwari, A. and Mahmoud, A.E.D., 2022. Microalgal potential for sustainable aquaculture applications: Bioremediation, biocontrol, aqua-feed. *Clean Technol. Environ. Policy*, pp. 1-13. <https://doi.org/10.1007/s10098-021-02254-1>
- Mohanty, S.N., Swain, S.K. and Tripathi, S.D., 1996. Rearing of Catla (*Catla catla*) spawn on formulated diets. *J. Aquacult. Trop.*, **11**: 253-258.
- Nayak, S.K., Swain, P. and Mukherjee, S.C., 2007. Effect of dietary supplementation of probiotic and vitamin C on the immune response of Indian major carp, *Labeo rohita*. *Fish Shellfish Immunol.*, **23**: 892-896. <https://doi.org/10.1016/j.fsi.2007.02.008>
- Noh, H., Han, K.I., Won, T.H. and Choi, Y.J., 1994. Effect of antibiotics, enzymes, yeast culture and probiotics on growth performance of Israeli carp. *Kor. J. Anim. Sci.*, **36**: 480-486.
- Prabu, E., Felix, S., Felix, N., Ahilan, B. and Ruby, P., 2017. An overview on significance of fish nutrition in aquaculture industry. *Int. J. Fish aquat. Stud.*, **5**: 349-355.
- Qin, C., Bai, Y., Zeng, Z., Wang, L., Luo, Z., Wang, S. and Zou, S., 2018. The cutting and floating method for paraffin-embedded tissue for sectioning. *J. Vis. Exp.*, **139**: e58288. <https://doi.org/10.3791/58288>
- Ramakrishnan, C.M., Haniffa, M.A., Manohar, M., Dhanaraj, M., Arockiaraj, A.J., Seetharaman, S. and Arunsingh, S.V., 2008. Effects of probiotics and spirulina on survival and growth of juvenile common carp (*Cyprinus carpio*). *Isr. J. Aquacult.*, **60**: 128-133. <https://doi.org/10.46989/001c.20484>
- Saghaei, A., hotbeddin, N. and Ghatrami, E.R., 2015. Evaluation of growth performance and body composition of Oscar fish (*Astronotus ocellatus*) in response to the consumption of dietary intake of garlic (*Allium sativum*). *Int. J. Bioflux Soc.*, **8**: 485-490.
- Swain, S.K., Rangacharyulu, P.V., Sarkar, S. and Das, K.M., 1996. Effect of a probiotic supplement on growth, nutrient utilization and carcass composition in *Cirrhinus mrigala* fry. *J. Aquacult.*, **4**: 29-35.
- Thatcher, C., Høj, L. and Bourne, D.G., 2022. Probiotics for coral aquaculture: Challenges and considerations. *Curr. Opin. Biotechnol.*, **73**: 380-386. <https://doi.org/10.1016/j.copbio.2021.09.009>
- Tiamiyu, L.O., Victor, T.O. and Athanasius, A., 2016. Growth performance of *Oreochromis niloticus* fingerlings fed *Moringa oleifera* leaf as replacement for soybean meal. *Turk. J. Fish. aquat. Sci.*, **2**: 61-66. <https://doi.org/10.3153/JAEFR16008>
- Tran, N.T., Yang, W., Nguyen, X.T., Zhang, M., Ma, H., Zheng, H., Zhang, Y., Chan, K.G. and Li, S., 2022. Application of heat-killed probiotics in aquaculture. *Aquaculture*, **548**: 737700. <https://doi.org/10.1016/j.aquaculture.2021.737700>
- Wang, Y., 2007. Effect of probiotics on growth

- performance and digestive enzyme activity of the shrimp. *Aquaculture*, **269**: 259-264. <https://doi.org/10.1016/j.aquaculture.2007.05.035>
- Wang, Y., 2011. Use of probiotics *Bacillus coagulans*, *Rhodopseudomonas palustris* and *Lactobacillus acidophilus* as growth promoters in grass carp (*Ctenopharyngodon idella*) fingerlings. *Aquacult. Nutr.*, **17**: 372-378.
- Yanbo, W. and Zirong, X., 2006. Effect of probiotics for common carp (*Cyprinus carpio*) based on growth performance and digestive enzyme activities. *Anim. Feed Sci. Technol.*, **127**: 283-292. <https://doi.org/10.1016/j.anifeedsci.2005.09.003>
- Yin, J.X., Chen, Y. and Meng, L.L., 2007. The influences of probiotics on intestinal microflora in crucian carp (*Carassius auratus*). *Fish. Sci.*, **26**: 610-612.