



# Effect of Chitosan on Induced Skin Wound Healing in Rabbits: Histopathological Evaluation

FALAH MAHMOOD HAMEED<sup>1\*</sup>, ASSAD KHALAF TALAL AL-SHUWAILI<sup>2</sup>, EMAN JAWAD JABBER<sup>3</sup>, MAYADA SAHIB HASSAN<sup>1</sup>

<sup>1</sup>*Surgery and Obstetric department, Veterinary medicine Faculty, University of Kerbala, Iraq;* <sup>2</sup>*Internal and Preventive Medicine department, Veterinary medicine Faculty, University of Kerbala, Iraq;* <sup>3</sup>*Pathology and Poultry department, Veterinary medicine Faculty, University of Kerbala, Iraq.*

**Abstract** | The objective of the current study was to assess how chitosan affects the capacity of rabbits to heal full-thickness cutaneous lesions, 24 clinically healthy adult male rabbits weighing 1.5 to 2 kg were utilized in the experiment. The interplay between intramuscular of 5 mg/kg xylazine hydrochloride, 35 mg/kg ketamine hydrochloride, and 1 mg/kg diazepam were carried out. Based on the sort of treatment applied, these animals were allocated into three groups (A, B, and C). Chitosan powder was applied locally to wounds in group (A), as well as administered orally in group (B), and the wounds were left untreated in group (C) as a standard group. Each group was split into four subgroups, each consisting of two wounds, for histological analysis at the 0, 3, 7, and 14-day post-wound production and treatment durations. The findings showed that the speed of wound healing in treated rabbits were faster than non-treated rabbits. Additionally, the findings showed that treated groups had improved cellularity and expanded angiogenesis compared to non-treated group. Conclusion: The histological results supported the hypothesis that chitosan enhances and promotes the development of wound healing on the skin.

**Keywords** | Chitosan, Skin, Wounds healing, Rabbits, Histopathology, Crustacean, Anaesthesia

**Received** | April 19, 2023; **Accepted** | May 10, 2023; **Published** | May 30, 2023

**\*Correspondence** | Falah Mahmood Hameed, Surgery and Obstetric department, Veterinary medicine Faculty, University of Kerbala, Iraq; **Email:** falah.m@uokerbala.edu.iq

**Citation** | Hameed FM, Al-Shuwaili AKT, Jabber EJ, Hassan MS (2023). Effect of chitosan on induced skin wound healing in rabbits: histopathological evaluation. *Adv. Anim. Vet. Sci.* 11(7): 1090-1096.

**DOI** | <https://doi.org/10.17582/journal.aavs/2023/11.7.1090.1096>

**ISSN (Online)** | 2307-8316



**Copyright** | 2023 by the authors. Licensee ResearchersLinks Ltd, England, UK.

This article is an open access article distributed under the terms and conditions of the Creative Commons Attribution (CC BY) license (<https://creativecommons.org/licenses/by/4.0/>).

## INTRODUCTION

The skin serves as the body's biggest organ and its first line of defense against the outside environment because of its thick surface and corneous layer (Shamloo et al., 2018). Skin and soft tissue disorders include trauma, infections, and cancers of the skin, subcutaneous tissue, and fascia (Peetermans et al., 2020). Chitosan and its derivatives can be used to treat wounds as they accelerate the healing process for injuries to the skin, muscles, blood vessels, and nerves. (Alven and Aderibigbe, 2020; Zhao et al., 2021). Chitin, a fundamental component of the protective

cuticles of many crustaceans like crabs, shrimps, prawns, and lobsters, is converted into chitosan through an alkaline deacetylation process (Kimbonguila et al., 2019). A lot of research has been done on chitosan to examine its possible application in medicine, food, and agriculture (Ghormade et al., 2017). Chitosan is biodegradable, biocompatible, hydrophilic, nontoxic and has antibacterial properties (Jin et al., 2015). Because of these properties, it is very useful for wound treatment, drug carrier, food packaging, dietary supplement, chelating agent, pharmaceutical, and biomaterial purposes, among other things (Gijiu et al., 2022). Additionally, it facilitates cell migration, stimulates

granulation and angiogenesis, encourages fibroblast proliferation, controls fiber deposition and organization, and improves wound healing (Naseri-Nosar and Ziora, 2018). Chitosan has several benefits, but it also degrades quickly and has a poor chemical strength (Gautam et al., 2014). Commercially, chitosan is available in different forms with variation in degree of de acetylation (50%–95%) and molecular weight (~300 to 1000 kDa) (Liu et al., 2011). Numerous chitosan derivatives have been discovered since chitosan is unstable and poorly soluble in water (Shahid and Butola, 2019). These derivatives were created chemically, retaining the parent chitosan's useful biological qualities while enhancing its morphology and composition (Ardean et al., 2021). Chitosan and its derivatives have been made into hydrogels, sponges, microspheres, nanoparticles, and thin films for use as medicinal materials. Due to the vast range of qualities of these compounds, they are frequently employed to treat many disorders, particularly those of the skin and soft tissues. (Zhang N. et al., 2020; He et al., 2021). Numerous investigations revealed that chitosan had the ability to heal wounds. Biocompatible carboxyethyl chitosan/poly(vinyl alcohol) (CECS/PVA) nanofibres were made by electrospinning an aqueous solution for use as a wound dressing material. According to cell culture results, fibrous mats were effective at encouraging L929 cell adhesion and proliferation (Zhou et al., 2008). A non-toxic, non-allergenic wound dressing is ideal, maintain a moist environment, permit gas exchanges, protect the site from microorganisms, and remove exudates from wounds (Croisier and Jérôme, 2013). The study parameters were determined using rabbits as an animal model following oral or local administration of the chitosan formulation once a day. The purpose of this study was to evaluate the effect of chitosan uses with method of treatment on cutaneous wound healing and compare it with a control group.

## MATERIALS AND METHODS

### EXPERIMENTAL ANIMALS

In the study, twenty-four adult male rabbits weighing between 1.5 and 2 kg were separated into three groups of eight each. Throughout the duration of the trial, the animals were housed in individual cages at the College of Veterinary Medicine, University of Kerbala, with free access to food and water (Pellets). Animals were given anti-coccidiosis injections for four weeks to help them adjust to the experimental conditions.

### ETHICAL APPROVAL

Each and every experimental technique was authorized by the College of Veterinary Medicine of kerbala and complied with the ethical approval number (UOK.VET.SU.2022.056).

## METHODS

### ANIMALS PREPARATION AND ANESTHESIA

Prior to receiving anesthesia, food was avoided for six hours. After shaving and cleaning the area along the dorsal back, diazepam was used to induce general anesthesia. After 10 minutes, xylazine and ketamine were then injected. These medicines were all administered intramuscularly. The dorsal side of the rabbits' backs was prepared for aseptic surgery while they were held in ventral recumbency. (Albozachri et al., 2017).

### EXPERIMENTAL DESIGN AND SURGICAL OPERATION

On each animal, a one square centimeter (1cm<sup>2</sup>) full-thickness skin wounds were created in dorsal aspect back region. The animals were divided into three groups, group (A) wounds were treated locally with chitosan daily for 7 days after creating the wound, while, at the same time in group (B), the wounds were treated locally and orally daily with chitosan, and group (C) the wounds were left without treatment as a control group.

### TISSUE PROCESSING

The samples were dehydrated using increasing concentrations of ethyl alcohol (50–100%), cleaned in xylene, and then embedded in melted paraffin wax (59c), after being fixed in 10% neutral buffered formalin for 24 hours, blocked and finally cutted with an ordinary microtome with 3–6 micrometer thickness, placed on clean slides. Tissue sections were stained with routine dyeing hematoxylin and eosin and were examined using light microscope (Shi et al., 2006, Gür et al., 2023).

## RESULTS

### BEHAVIOIRAL AND WOUND HEALING EVALUATION

All animals were noted to eat and behave normally in the first three days after surgery, the wound healing processes were evaluated histologically in treatment and control wounds during two weeks of study as following;

### HISTOPATHOLOGICAL RESULTS

As stated in the study, a histopathological evaluation of all groups was done on days 3, 7, and 14 following treatment. Full-thickness incisional biopsy samples were obtained (5–6 mm wide), and they contained 3–4 mm of uninjured skin on either side of the wound. These samples were then embedded in paraffin, fixed in neutral formalin solution (10%), sectioned into 5- to 7-micron sections on a rotary microtome, and stained with hematoxylin-eosin (H&E) stains. The animals showed no signs of infection in the post-operative period and continued to be healthy. The aseptic circumstances surrounding the wounds in all groups were further confirmed by the microscopic inspection.

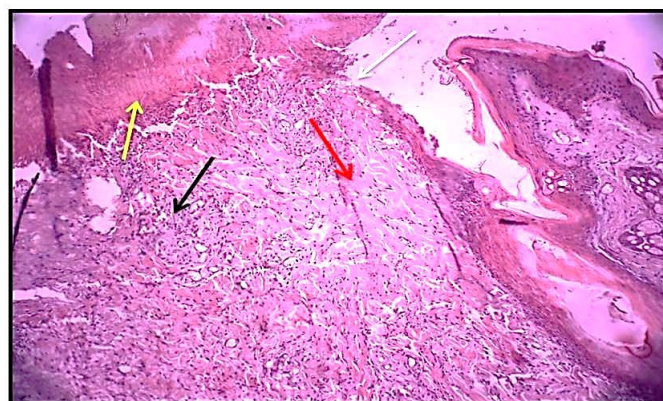


tion. A complex biological process called wound healing occurs in all tissues and organs of the body. Various cell types, including keratinocytes, neutrophils, macrophages, lymphocytes, fibroblasts and endothelial cells, are involved in this process.

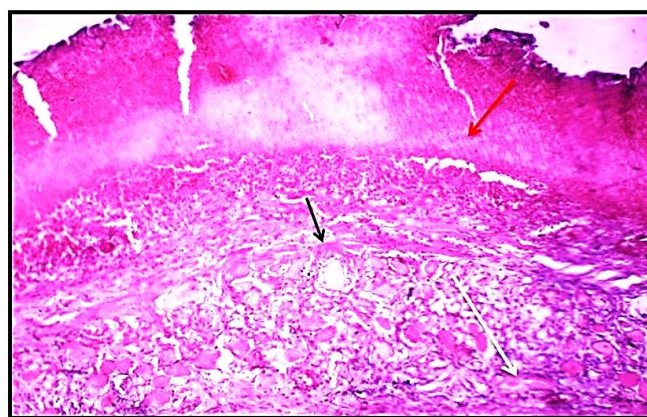
The inflammatory response predominated on the third day of skin wound healing in groups A and B (the treated group). Necrosis of skin tissue was observed on the skin's surface as a result of mechanical injury. This stage was also characterized by hemostasis, RBCs (red arrow), mild fibrosis (black arrow) and significant angiogenesis (new emerging blood vessels) (white arrow), slight granulation, slight edema, and significant formation of new hair follicles (white arrow) (Fig. 2,3). In the treated group, inflammatory cells thickened the epidermis near the cut edges, whereas in the control group, inflammatory responses were absent (Fig. 1). The inflammatory response is initiated very soon after the trauma on wound event, it's the first phase of the wounds healing. During this response the wound and surrounding tissues become inflamed and cells, mainly neutrophils and monocytes, are mobilized to penetrate the clot and begin the processes involved in granulation tissue formation.

In the 7<sup>th</sup> day of skin wound healing group (A, B) showed hemostasis, edema (red arrow), mild fibrosis, significant numbers of fibrocytes (black arrow) and slight hyperkeratosis (white arrow). slight inflammatory cell infiltration (red arrow), mild fibrosis (collagen fibers) (black arrow) (Fig. 5,6), and significant keratinocyte proliferation, slight granulation tissue that was revealed as compared with group C (Fig. 4). This is because the chitosan used in the formulation also has antibacterial properties, which further enhance the antibacterial activity.

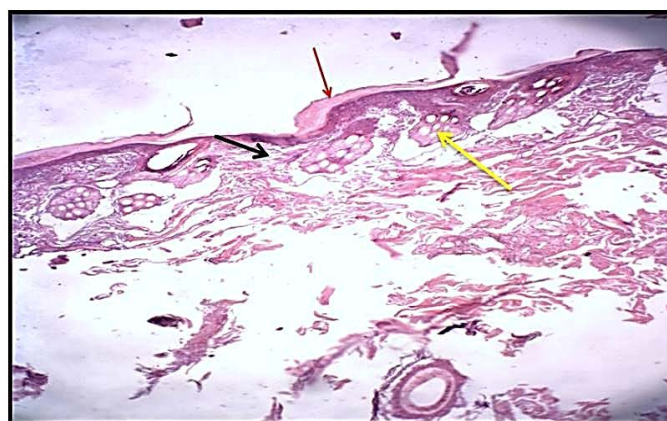In the 14<sup>th</sup> day of skin wound healing, group (A,B) (the treated group) showed re-epithelialization (red arrow), mild fibrosis (black arrow), and mild hyperplasia of the epidermis (white arrow) (Fig. 8,9). At the same period, the histological sections of control group were showed the fully epithelized surfaces (white arrow), less collagen fibers proliferation (red arrow). Granulation tissue less cellularity (black arrow) and tissue structure resemble normal (Fig. 7). Wound healing is a process for promoting rapid dermal regeneration and accelerated wound healing. A chitosan membrane consisting of a skin surface on the top layer supported A chitosan membrane with a skin surface on top and a macro-porous sponge-like sublayer has been created. The chitosan membrane demonstrated regulated evaporative water loss, high oxygen permeability, and improved fluid drainage while efficiently suppressing exogenous microbe invasion.



**Figure 1:** Histological section 3<sup>rd</sup> day of wound healing control group showed the non – epithelialization surfaces (white arrow), collagen fibers proliferation forming a matrix (red arrow). Granulation tissue formation (black arrow) with the presence of red blood cells (yellow arrow). (Hematoxylin and Eosin ,10 X).

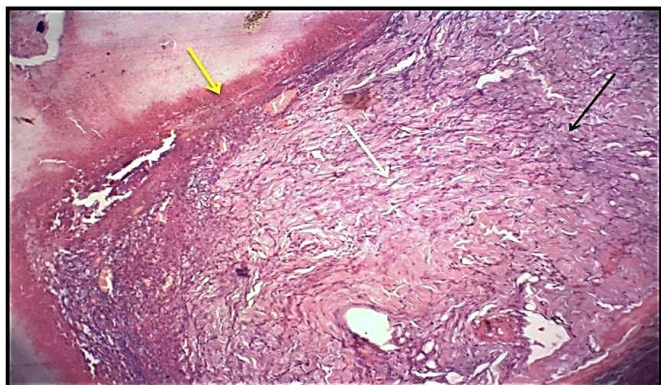


**Figure 2:** Histological section 3<sup>rd</sup> day of wound healing for the treated group (locally) showed hemostasis, RBCs (red arrow), mild fibrosis (black arrow) and significant angiogenesis (new emerging blood vessels) (white arrow) Slight granulation tissue. (Hematoxylin and Eosin ,10 X).

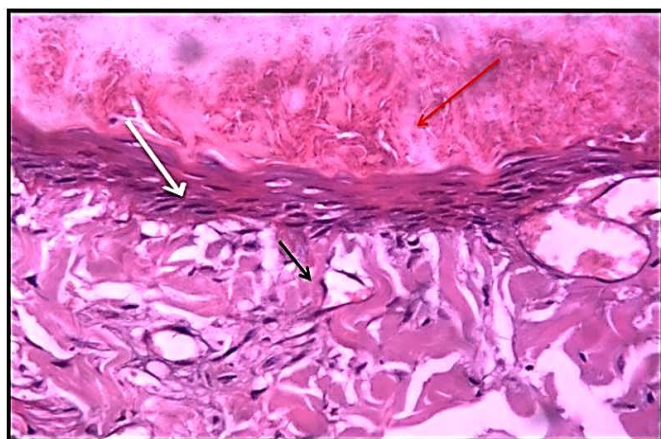


**Figure 3:** Histological section 3<sup>rd</sup> day of healing in wound for treated group(local, oral) showed slight edema and hemostasis (red arrow), mild fibrosis (collagen fibers) (black arrow) and significant formation of new hair follicles (white arrow) (Hematoxylin and Eosin ,10 X).

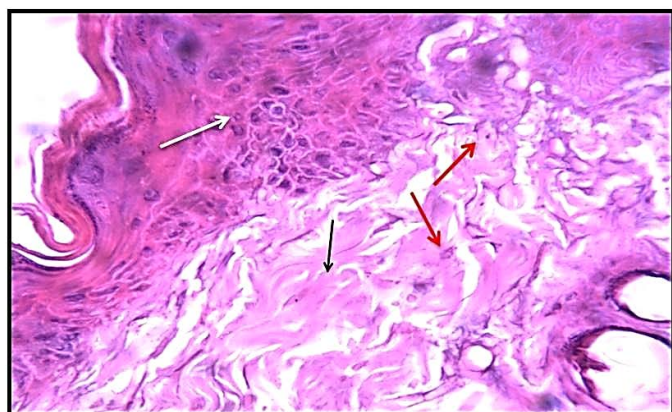




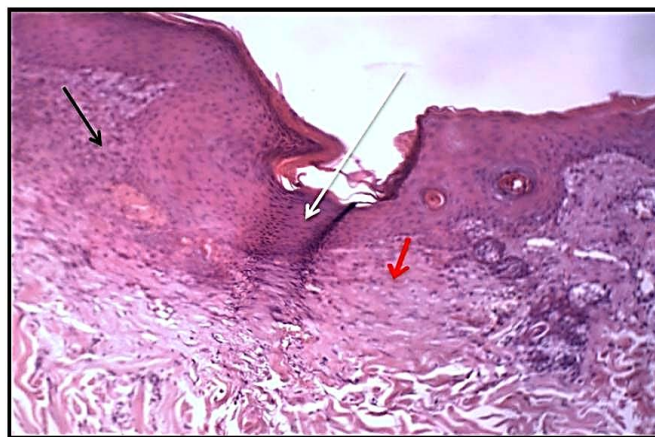**Figure 4:** Histological section of wound healing control group at days 7, showed significant highly collagen fibers proliferation ( white arrow). Granulation tissue more cellularity (black arrow) with less presence hemostasis (red blood cells) (yellow arrow). (Hematoxylin and Eosin, 10 X).



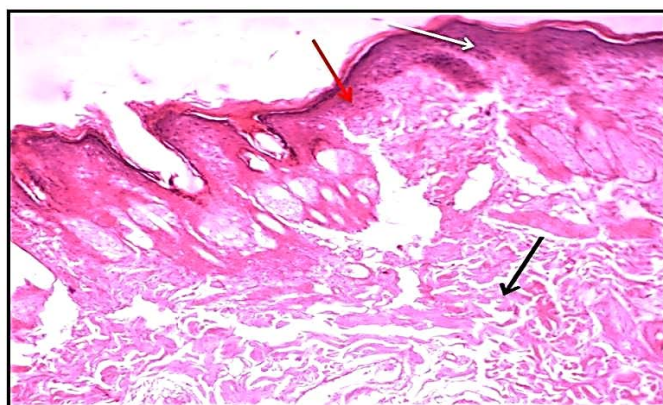
**Figure 5:** Histological section of 7<sup>th</sup> day wound healing for treated group (locally) showed hemostasis, edema (red arrow), mild fibrosis and significant numbers of fibrocytes (black arrow) and slight hyperkeratosis (white arrow) slight granulation tissue. (Hematoxylin and Eosin ,10 X).



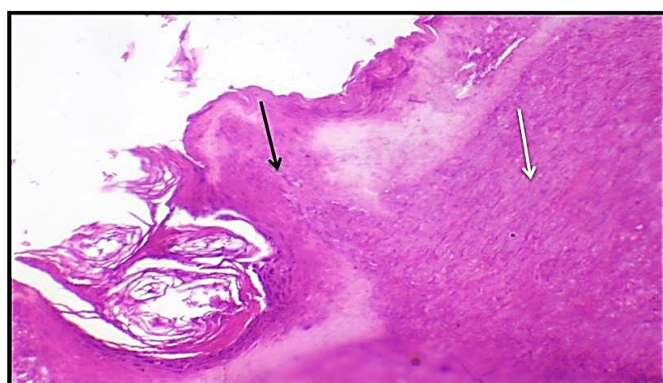
**Figure 6:** Histological section of of 7<sup>th</sup> day healing in wound treated group (locally, orally) showed the slight inflammatory cells infiltration (red arrow), mild fibrosis (collagen fibers) (black arrow) and significant keratocytes proliferation (white arrow). (Hematoxylin and Eosin, 10 X).



**Figure 7:** Histological section of 14<sup>th</sup>day wound healing control group showed the fully epithelized surfaces (white arrow), less collagen fibers proliferation (red arrow). Granulation tissue less cellularity (black arrow) and tissue structure resemble normal. (Hematoxylin and Eosin, 10 X).



**Figure 8:** Histological section of 14<sup>th</sup> day of wound healing treated group (locally) showed re-epithelization (red arrow), mild fibrosis (black arrow) and mild hyperplasia of epidermis (white arrow). slight granulation tissue. (Hematoxylin and Eosin, 10 X).



**Figure 9:** Histological section of 14<sup>th</sup>day, of wound healing treated group (locally, orally) showed significant re-epithelialization in epidermis (black arrow) and extensive granulation tissue formation in dermis (white arrow) (Hematoxylin and Eosin, 10 X).



Haemostasis, inflammation, proliferation, and remodeling are the four steps that make up the complicated and dynamic regeneration process of wound healing (Hani and Satya, 2013). The tissue-regenerating properties of chitosan present a novel approach to skin reconstruction. (Wei et al., 2022). This study shows the enhancement of inflammation chitosan reaction. This reinforcement may be due to the increase in inflammatory cells in the first three days in both number and more specifically due to their high capacity to secrete more chemical factors, unlike the natural recovery process, so the process appeared faster and took shorter period to complete it compared With control. This conclusion is in agreement with many studies (Ahamed and Sastry., 2011, Rodrigues., 2019). These cytokines play an important role in recovery mechanism (Okamoto et al, 2003). It was reported that fibrous cells stimulated by chitosan molecules secrete Intercin -8 (IL -8) and other cytokines that in turn can stimulate blood vessels, fibrosis and epithelium. (Mori et al., 1997) It is known that IL-8 is from Al-Wa'i and chemical attractiveness to both lining and skin cells. Koch et al. (1992) Chitosan has a free active group (N-Acetyl-D-Glucosamine) that has a pioneering role in the healing process. Song and Park (2001) Despite having a sewing machine It is regarded as the infection's origin. (Javed et al., 2012) The chitosan antimicrobial property plays an important role in accelerating wound healing and preventing infection (Zhou et al., 2016). Graduate studies indicate that the amino groups are from chitosan when calling it Physiological fluids are protonated and they are associated with anonymous groups of microorganism microbial cells and growth (Mi et al., 2001, Kumirska et al., 2011).

Topical application of chitosan in burning wound management can stimulate forming the tissues of the granulation in the early stages of healing wounds and activation one of the fibrous cells that produce collagenase, this enzyme responsible for re-present it stimulates re-appearance and aids in wound healing (Alsarra, 2009, Wilkinson and Hardman, 2020). Re-preparation did not show any significant variation between groups in this investigation, even when the top groups dealt with chitosan. The study's usage of chitosan could be to blame for this outcome, chitosan not have enough molecular weight and the degree of permissible removal to enhance the epithelium to treat (Aranza et al., 2009). As the effects of healing the wound chitosan can be affected by factors Periodic molecular weight (Park et al., 2011). The degree of removal of acetyl (Kojima et al 2004). Also, the chitosan concentration that has been used may not be sufficient stimulating the revival of the epithelium, effect chitosan was influenced by a concentration chitosan itself, the top chitosan concentration is

a higher initial effect, however lower chitosan concentration for him the time of influence is longer (Chen et al., 2002). It may also be to reduce rehabilitation due A short period of chitosan application, due to the plaster that was placed after surgery. The procedure does not remain for a long time after surgical work, about 15 minutes remained a maximum due to the natural activity of animals after waking up from the anesthesia that led to the removal of plaster from the back of the animal easily when they are running, jumping and digging their tunnels, this chitosan wash from wounds when applied in the form of powder.

## CONCLUSIONS AND RECOMMENDATIONS

Chitosan's antibacterial and anti-inflammatory properties give it the potential to be an efficient wound healing accelerator. Effective dressings should have properties tailored to a certain type of wound, be reasonably affordable, and cause the least amount of discomfort to patients. Numerous findings have been made public, however these materials still require a thorough and uniform classification. In order to accomplish these goals, it is necessary to modify the physical characteristics of the recognized systems.

## ACKNOWLEDGEMENTS

I would like to thank staff of department of veterinary Surgery College of Veterinary Medicine, University of Kerbala.

## CONFLICT OF INTEREST

The authors state that they have no conflicts of interest.

## NOVELTY STATEMENT

The current work uses histopathological testing to evaluate the Chitosan on induced skin wound healing in rabbits, providing insights into its histological and physiological features of the skin wound healing process. All authors read, reviewed, and revised the manuscript and approved the final version.

## AUTHORS CONTRIBUTION

Assad AL-shuwaili developed the offered concept and prepared the experiments. Falah Mahmood Hameed and Mayada S. Hassan formulated the theory and did the surgery, carried out the experiment, and authored the report with input and support from all authors. Eman J. Jabber worked out the histological processing, slide preparation, Imaging, as well as the data analysis. Falah Mahmood

Hameed worked out nearly all of the technical aspects and ran the numerical computations for the proposed experiment. All authors discussed the findings, provided critical comments, aided in the development of the research, and contributed to the final publication.

## REFERENCES

- Ahamed NM, Sastry TP (2011). An In vivo study on the wound healing activity of cellulose-chitosan composite incorporated with silver nanoparticles in albino rats. *I. J. R. A. P.*, 2(4):1203-1209.
- Albozachri JMK, Hameed FM, AL-Tomah HM, Muhammad HA (2017). Evaluation of two general anesthetic regime by use xylazine and ketamine with atropine and diazepam in rabbits. *University of Kerbala*. 15(1):21-30.
- Alsarra IA (2009). Chitosan topical gel formulation in the management of burn wounds. *Int. J. Biolog. Macromolecules*. 45(1):16-21. <https://doi.org/10.1016/j.ijbiomac.2009.03.010>.
- Alven S., Aderibigbe, B. A. (2020). Chitosan and Cellulose-Based Hydrogels for Wound Management. *Int. J. Mol. Sci.* 21 (24): 9656. <https://doi.org/10.3390/ijms21249656>
- Aranza I, Mengibar M, Harris R, Paños I, Miralles B, Acosta N., et al. (2009). Functional Characterization of Chitin and Chitosan. *Curr. Chem. Biol.* 3(2):203-230. <https://doi.org/10.2174/2212796810903020203>
- Ardean C., Davidescu C. M., Nemeş N. S., Negrea A., Ciopec M., Duteanu N., et al. (2021). Factors Influencing the Antibacterial Activity of Chitosan and Chitosan Modified by Functionalization. *Int. J. Mol. Sci.* 22 (14): 7449. <https://doi.org/10.3390/ijms22147449>
- Chen XG, Wang Z, Liu S, Park HJ (2002). The effect of carboxymethyl-chitosan on proliferation and collagen secretion of normal and keloid skin fibroblasts. *Biomaterials*. 23(23):4609-4614. [https://doi.org/10.1016/S0142-9612\(02\)00207-7](https://doi.org/10.1016/S0142-9612(02)00207-7)
- Croisier F., Jérôme C. (2013). Chitosan based biomaterial for tissue engineering. *Eur. Polym. J.* 49: 780-792.
- Gautam S, Chou CF, Dinda AK, Potdar PD, Mishra NC (2014). Fabrication and characterization of PCL/gelatin/chitosan ternary nanofibrous composite scaffold for tissue engineering applications. *J. Mater. Sci.* 49(3):1076-1089. <https://doi.org/10.1007/s10853-013-7785-8>
- Ghormade V, Pathan EK, Deshpande M.V. (2017). Can fungi compete with marine sources for chitosan production? *Int. J. Biol. Macromol.* 104(Pt B):1415-1421. <https://doi.org/10.1016/j.ijbiomac.2017.01.112>.
- Gijiu CL, Isopescu R, Dinculescu D, Memecică M, Apetroaei M-R, Anton M. et al. (2022). Crabs Marine Waste—A Valuable Source of Chitosan: Tuning Chitosan Properties by Chitin Extraction Optimization. *Polymers*. 14(21):4492. <https://doi.org/10.3390/polym14214492>.
- Gür R, Büyükkayüz N, Aydil BA, Ayhan M (2023). Histopathological investigation of the effect of chitosan on oral mucous wound healing in experimentally established diabetic rats. *Ulus Travma Acil Cerrahi Derg* 29:140-148 <https://doi.org/10.14744/tjtes.2022.55726>.
- Hani S., Satya P. (2013). Complements and the wound healing cascade: an updated review. *Plast. Surg. Int.* 1-7.
- He Y., Zhao W., Dong Z., Ji Y., Li M., Hao Y., et al. (2021). A Biodegradable Antibacterial Alginate/Carboxymethyl Chitosan/Kangfuxin Sponges for Promoting Blood Coagulation and Full-Thickness Wound Healing. *Int. J. Biol. Macromol.* 167: 182-192. <https://doi.org/10.1016/j.ijbiomac.2020.11.168>
- Javed F, Al-Askar M, Almas K, Romanos GE, Al-Hezaimi K. (2012). Review article: tissue reactions to various suture materials used in oral surgical interventions. *ISRN Dentistry*. 2012:762095. <https://doi.org/10.5402/2012/762095>
- Jin RM, Sultana N, Baba S, Hamdan S, Ismail AF (2015). Porous PCL/Chitosan and nHA/PCL/chitosan scaffolds for tissue engineering applications: Fabrication and evaluation. *J. Nanometer. Article ID357372*, 8pages. <https://doi.org/10.1155/2015/357372>
- Kimbonguila A., Matos L., Petit J., Scher J., Nzikou J. M. (2019). Effect of Physical Treatment on the Physicochemical, Rheological and Functional Properties of Yam Meal of the Cultivar “Ngumvu” From Dioscorea Alata L. of Congo. *Int. J. Recent Sci. Res.*, 8(3): 15773- 15776.
- Koch AE, Polverini PJ, Kunkel SL, Harlow LA, Dipietro LA, Elner VM., et al (1992). Interleukin-8 as macrophage derived mediator of angiogenesis. *Science*. 258(5089):1798-801. <https://doi.org/10.1126/science.1281554>
- Kojima K, Okamoto Y, Kojima K, Miyatake K, Fujise H, Shigemasa Y. et al. (2004). Effects of chitin and chitosan on collagen synthesis in wound healing. *Vet. Med. Sci.* 66(12):1595-1598. <https://doi.org/10.1292/jvms.66.1595>
- Kumirska J, Weinhold MX, Thöming J, Stepnowski P (2011).. Biomedical Activity of Chitin/Chitosan Based Materials—Influence of Physicochemical Properties Apart from Molecular Weight and Degree of N-Acetylation. *Polymers*. 3(4):1875-1901. <https://doi.org/10.3390/polym3041875>
- Liu X, Ma L, Mao Z, Gao C (2011). Chitosan-based bio materials for tissue repair and regeneration. *Adv Polym Sci.* 244:81-127. [https://doi.org/10.1007/12\\_2011\\_118](https://doi.org/10.1007/12_2011_118)
- Mi FL, Shyu SS, Wu YB, Lee ST, Shyong JY, Huang RN (2001). Fabrication and characterization of a sponge-like asymmetric chitosan membrane as a wound dressing. *Biomaterials*. 22(2):165-73. [https://doi.org/10.1016/S0142-9612\(00\)00167-8](https://doi.org/10.1016/S0142-9612(00)00167-8)
- Mori T, Okumura M, Matsuura M, Ueno K, Tokura S, Okamoto Y. et al (1997). Effects of chitin and its derivatives on the proliferation and cytokine production of fibroblasts in vitro. *Biomaterials*. 18(13):947-51. [https://doi.org/10.1016/S0142-9612\(97\)00017-3](https://doi.org/10.1016/S0142-9612(97)00017-3)
- Naseri-Nosar M, Ziora ZM (2018). Wound dressings from naturally-occurring polymers: A review on homopolysaccharide based composites. *Carbohydr Polym.* 189,379-398. <https://doi.org/10.1016/j.carbpol.2018.02.003>
- Okamoto Y, Yano R, Miyatake K, Tomohiro I, Shigemasa Y, Minamia S. (2003). Effects of chitin and chitosan on blood coagulation. *Carbohydrate Polymers*. 53(3):337-342. [https://doi.org/10.1016/S0144-8617\(03\)00076-6](https://doi.org/10.1016/S0144-8617(03)00076-6)
- Park JK, Chung MJ, Choi HN, Park YI. (2011). Effects of the Molecular Weight and the Degree of Deacetylation of Chitosan Oligosaccharides on Antitumor Activity. *Int. J. Mol. Sci.*, 12(1):266-277. <https://doi.org/10.3390/ijms12010266>
- Peetermans M., de Prost, N., Eckmann, C., Norrby-Teglund, A., Skrede, S., De Waele, J. J. (2020). Necrotizing Skin and Soft-Tissue Infections in the Intensive Care Unit. *Clin. Microbiol. Infect.* 26 (1): 8-17. [July 2023 | Volume 11 | Issue 7 | Page 1095](https://doi.org/10.1016/j.</a></p>
</div>
<div data-bbox=)

- Rodrigues M, Kosaric N, Bonham CA, Gurtner GC (2019). Wound Healing: A Cellular Perspective. *Physiol Rev.* 99(1):665-706. <https://doi.org/10.1152/physrev.00067.2017>
- Shahid UI, I., Butola B. S. (2019). Recent Advances in Chitosan Polysaccharide and its Derivatives in Antimicrobial Modification of Textile Materials. *Int. J. Biol. Macromol.* 121: 905–912. <https://doi.org/10.1016/j.ijbiomac.2018.10.102>
- Shamloo A., Sarmadi M., Aghababae Z., Vossoughi M (2018). Accelerated full-thickness wound healing via sustained bFGF delivery based on a PVA/chitosan/gelatin hydrogel incorporating PCL microspheres. *Int. J. Pharm.* 537: 278. [CrossRef] [PubMed]
- Shi C, Zhu Y, Ran X, Wang M, Su Y, Cheng T (2006). Therapeutic potential of chitosan and its derivatives in regenerative medicine. *J. Surg. Res.*, 133(2):185-192. <https://doi.org/10.1016/j.jss.2005.12.013>
- Song KW, Park MH (2001). Studies on gelatin-based sponges. Part III: A comparative study of cross-linked gelatin/alginate, gelatin/hyaluronate and chitosan/hyaluronate sponges and their application as a wound dressing in full thickness skin defect of rat. *J. Mater. Sci. Mater. Med.* 12(1):67-73. <https://doi.org/10.1023/a:1026765321117>.
- Wei L., Tan J., Li L., Wang H., Liu S., Chen J., et al. (2022). Chitosan/Alginate Hydrogel Dressing Loaded FGF/VE-

- Cadherin to Accelerate Full-Thickness Skin Regeneration and More Normal Skin Repairs. *Int. J. Mol. Sci.* 23 (3): 1249. <https://doi.org/10.3390/ijms23031249>
- Wilkinson HN, Hardman MJ (2020). Wound healing: cellular mechanisms and pathological outcomes. *Open Biol. Sep*;10(9):200223. <https://doi.org/10.1098/rsob.200223>
- Zhang N., Gao T., Wang Y., Liu J., Zhang J., Yao R., et al. (2020). Modulating Cationicity of Chitosan Hydrogel to Prevent Hypertrophic Scar Formation during Wound Healing. *International Journal of Biological Macromolecules* 154: 835–843. <https://doi.org/10.1016/j.ijbiomac.2020.03.161>
- Zhao Y., Hao J., Chen Z., Li M., Ren J., Fu X. (2021). Blood-clotting Model and Simulation Analysis of Polyvinyl Alcohol-Chitosan Composite Hemostatic Materials. *J. Mat. Mater. Chem. B* 9 (27): 5465–5475. <https://doi.org/10.1039/d1tb00159k>
- Zhou H, Liu X, Wu F, Zhang J, Wu Z, Yin H., et al (2016). Preparation, Characterization and Antitumor Evaluation of Electrospun Resveratrol Loaded Nanofibers. *J. Nanomater.* vol. 2016, Article ID5918462, 11 pages. <https://doi.org/10.1155/2016/5918462>
- Zhou Y., Yang D., Chen X., Xu Q., Lu F., Nie J. (2008). Electrospun water-soluble carboxyethyl chitosan/poly(vinyl alcohol) nanofibrous membrane as potential wound dressing for skin regeneration. *Biomacromolecules.* 9: 349–354.