



Antifertility Efficacy of Testosterone on Male and Female Albino Mice

Maha Mostafa¹, Sohail Soliman¹, Reham I. Mohamed² and Wael M. El-Sayed^{1*}

¹Department of Zoology, Faculty of Science, Ain Shams University, Abbassia 11566, Cairo, Egypt.

²Pesticide Chemistry Department, Chemical Industries Research Institute, National Research Centre, Dokki, Giza, Egypt

ABSTRACT

One of the approaches to the control of rodent pests is the use of anti-fertility compounds such as synthetic steroids, estrogens, progestins, androgens, chemical compounds, and natural plant extracts. The aim of this approach is to lower the population size of pests by reducing the natality rather than by increasing mortality. Male (20) and female (40) albino mice were orally administered testosterone at 25 mg/kg for 35 days. The males were allowed to mate with females to estimate the fertility index. After the end of treatment, mice were sacrificed, blood was collected for biochemical analysis, and sex organs were dissected out for histological preparations. Administration of testosterone has significantly increased the body weight and decreased the gonad weight in both sexes. It drastically affected the histology of testes and ovaries, causing a reduction in the sperm count and motility with a parallel reduction in the acid phosphatase activity. It also directly reduced the concentration of free testosterone and estradiol in both sexes without any apparent effect on LH or FSH hormones. It increased the total cholesterol in males only and elevated the triacylglycerols and glucose levels in both sexes. The administration of testosterone to males, females, or both reduced the fertility index to zero. The mating success was also reduced from 80 to zero when both the males and females were administered with testosterone. The synthetic testosterone had antifertility effects on both sexes of albino mice and therefore, it could be used in the pest control of mice.

Article Information

Received 10 November 2021

Revised 26 December 2021

Accepted 19 January 2022

Available online 14 March 2022

(early access)

Published 19 December 2022

Authors' Contribution

MM and RI carried out the experimental work, analysed the data, and prepared the first draft of the manuscript. WME and SS designed and supervised the work. WME critically read and approved the final version of the manuscript. All authors have approved the final manuscript.

Key words

Acid phosphatase, Estradiol, Fertility index, Pest control, Sperm count, Sperm motility

INTRODUCTION

The inefficiency of the traditional lethal methods used in the control of vertebrate pests as well as the moral debate associated with the use of such methods, has forced pest managers to look for non-lethal alternatives. One of the alternatives of lethal methods of pest control is the use of compounds that induce sterility. The final goal of this approach is to reduce the size of pest populations through the suppression of natality rather than through the increase of mortality (Miller, 2002). This approach of pest control, also known as biogenetic control, is therefore more humane and more acceptable by animal welfare groups than traditional lethal methods. Moreover, the anti-fertility compounds could be used in areas where the use of lethal

techniques is not preferred such as in food stores. The anti-fertility substances may disrupt spermatogenesis in males, prevent ovulation and fertilization, prevent implantation, destroy zygotes, or cause abortion in females (Kumar et al., 2013).

The list of anti-fertility compounds used to induce sterility in vertebrate pests included synthetic steroids, estrogens, progestins, androgens, chemical compounds, and natural plant extracts (Fagerstone et al., 2002). Testosterone is the primary male hormone responsible for regulating sex differentiation, producing male sex characteristics, spermatogenesis, and fertility (Basaria, 2013). It is responsible for the development of primary sexual development, which includes testicular descent, spermatogenesis, enlargement of the penis and testes, and increasing libido (Kalfa et al., 2019). The investigation of testosterone as a potential male contraceptive was suggested by (Steinberger and Smith, 1977). This suggestion was considered to be a promising approach to the development of a relatively simple and safe male contraceptive. Several years later, Steinkampf and Marizia (2011) indicated that the treatment of men with testosterone had suppressed the production of FSH and LH, and caused an atrophy of their testes. Patel et al. (2018) similarly found that the exogenous testosterone therapy had negatively affected

* Corresponding author: wael_farag@sci.asu.edu.eg, waelhalawany@hotmail.com
0030-9923/2023/0002-609 \$ 9.00/0



Copyright 2023 by the authors. Licensee Zoological Society of Pakistan.

This article is an open access article distributed under the terms and conditions of the Creative Commons Attribution (CC BY) license (<https://creativecommons.org/licenses/by/4.0/>).

the hypothalamic-pituitary gonadal axis and inhibited the production of FSH and LH in men.

The present study aims at evaluating the efficacy of synthetic exogenous testosterone as anti-fertility agent in both sexes of albino mice as a prelude to pest control of the house mice.

MATERIALS AND METHODS

Compliance with ethical standards

Experimental animals were humanely treated in accordance with the rules of laboratory animal care of the National Institute of Health (NIH publication No. 86-23, revised 1985). The study design including animal experiments was approved by the Research Ethics Committee at Faculty of Science, Ain Shams University (9/2018) prior to the commencement of the study.

Animals and experimental design

Twelve-week-old Swiss albino mice of ~ 25 g body weight were purchased from the National Research Centre, (Cairo). Mice were transported to the animal house of the Department of Zoology, Faculty of Science, Ain Shams University. They were housed in polypropylene cages (26 cm x 20 cm x 6 cm) provided with wood shavings as a harbourage material. Mice were provided with standard diet and water ad libitum. A group of 20 male albino mice and 40 female albino mice were divided into four experimental groups:

Group 1 (control group): five untreated males + 10 untreated females were allowed to mate. Individuals of this group received distilled water.

Group 2: five treated males + 10 untreated females. Males received daily oral doses of 25 mg/kg of synthetic testosterone (3 times per week for five consecutive weeks) (Callies *et al.* (2003). Each treated male mated with two untreated females.

Group 3: five untreated males + 10 treated females. Before mating, females received daily oral doses of 25 mg/kg of synthetic testosterone (3 times per week for three consecutive weeks). After mating, females continued to receive the same dose for only two consecutive weeks. Each untreated male was allowed to mate with two treated females.

Group 4: five treated males + 10 treated females. Males received the oral doses of testosterone like group 2, and females received the oral doses of testosterone like group 3. Individuals of both sexes were allowed to mate together.

Each male mouse was allowed to mate with two female mice in a separate cage overnight. Successful mating was confirmed by the presence of a vaginal plug as well as the presence of sperms in a vaginal smear. The

following percentages were determined (Tatli-Cankaya *et al.*, 2014):

Mating success (%) = number of mated females/ number of paired females X 100

Fertility success (%) = number of pregnant females/ number of paired females X 100

Fertility index (%) = number of pregnant females/ numbers of mated females X 100

Blood and tissue harvesting

At the end of the experiment, the animals were anesthetized with isoflurane. Blood was collected and serum was immediately separated and kept at -20°C for the biochemical analyses. Epididymis, testes, and ovaries were harvested. Testes and ovaries were randomly selected from left or right sides of the mice of each group.

Body weight, testes and ovaries weight, sperm count and motility

The body weight of individual mice was recorded before and after treatment. Testes and ovaries were dissected out from treated animals and weighed after removing blood and adhering tissues. The epididymis was removed, put in 2 ml normal saline solution, and then incubated for 15 minutes at 38°C. The sperm number was counted using hemocytometer and expressed as 10⁶/ml of suspension. The motility was assessed using a hemocytometer under a high power lens of a light microscope.

Biochemical measurements

Testosterone level was assayed in the serum by ELISA kit (Diametra, Italy). Serum FSH and LH levels were assayed by ELISA kits purchased from Bioactive Diagnostica, (Germany). Estradiol was measured in serum using ELISA kit (DRG, Germany). Determination of total cholesterol and triacylglycerols level in serum was estimated colorimetrically according to the method of Ellefson and Caraway (1976) and Bucolo and David (1973), respectively using Spectrum kit (Cairo, Egypt). Serum glucose concentration was estimated as described by Trinder (1969). The activity of serum acid phosphatase was estimated to the method of Kind and King (1954) using a colorimetric assay kit (Spectrum, Egypt).

Histological preparations

Small pieces of testis and whole ovary were fixed in Bouins solution for 24 h. The tissues were dehydrated in ascending grades of ethyl alcohol, and then cleared in terpineol for three days. The organs were then embedded in three changes of paraffin wax one hour each. The paraffin blocks were sectioned at 5 µm and mounted on clean slides. The sections were stained with Harris haematoxylin and eosin.

Statistical analyses

Statistical evaluation was conducted with Instat Program GraphPad (software Inc, San Diego, USA) version 3.6. Results were expressed as mean \pm SEM. The data distribution was tested by the Kolmogorov-Smirnov test. The results were analysed by ANOVA followed by Tukey-Kramer multiple comparisons tests. Values of $p < 0.05$ were considered significant.

RESULTS

The body weight of male and female mice significantly increased compared with that of the relevant control group. The relative weight of testes and ovaries significantly decreased compared with the control group (Table I). Exogenous testosterone significantly ($p < 0.001$) decreased the sperm count and motility.

The administration of testosterone significantly decreased the concentration of testosterone in male ($p < 0.001$) and female mice ($p < 0.05$) compared with the control group (Table I). The estradiol level was also reduced in male ($p < 0.05$) and female ($p < 0.01$) mice. However, the concentration of FSH and LH did not show significant changes in both sexes after the treatment with the testosterone compared with the control (Table I).

The administration of testosterone significantly ($p < 0.01$) increased the serum total cholesterol level in males, and the levels of triacylglycerols in both males and females ($p < 0.05$). It also resulted in the elevation of glucose level

in both male and female mice (Table I). The activity of acid phosphatase was significantly ($p < 0.01$) reduced in male mice.

Mating tests indicated that exogenous testosterone had affected the fertility of both sexes of mice. In control females, the mating success, fertility success, and fertility index were 80%, 60%, and 75%, respectively (Table II). In group 2, when males treated with testosterone were paired with untreated females, the mating success, fertility success, and fertility index were 20%, 0%, and 0%, respectively. In group 3, when untreated males were paired with treated females, the number of successfully mated females was 1 out of 10 females (10%) with both fertility success and fertility index at 0% (Table II). In group 4, when both males and females were treated with exogenous testosterone, no females of this group were successfully mated.

The testes from treated males showed small-sized tubules with thickened basement membrane, thin mildly edematous germinal lining with scattered spermatogonia and primary spermatocytes with vacuolated cytoplasm and scattered apoptotic cells. No sperms were found in some tubules, and markedly edematous interstitium with Leydig cells showing dark black cytoplasmic inclusions were identified (Fig. 1). Ovaries from treated females showed primordial, primary and secondary follicles with degenerated oocyte, and multiple corpora lutea in cellular stroma with scattered large cells with vacuolated cytoplasm (Fig. 2).

Table I. Effect of exogenous testosterone on the body weight, gonad weight, sperm count, and sperm motility sex hormones (free testosterone, estradiol, FSH, LH) some biochemical components of blood serum (cholesterol, triacylglycerols, glucose, AP) of male and female albino mice.

	Male		Female	
	Control	Experimental	Control	Experimental
Body weight	31.6 \pm 1.0	35.0 \pm 0.9*	29.8 \pm 1.2	35.7 \pm 0.8*
Relative gonad weight (g)	0.082 \pm 0.003	0.023 \pm 0.001*	0.054 \pm 0.002	0.035 \pm 0.001**
Sperm count (X10 ⁶ /ml)	10.0 \pm 0.6	1.4 \pm 0.4**	--	--
Sperm motility (%)	70.5 \pm 3.0	1.0 \pm 0.3**	--	--
Free testosterone (pg/ml)	472 \pm 76.0	0.51 \pm 0.01**	0.17 \pm 0.01	0.12 \pm 0.01*
Estradiol (pg/ml)	38.7 \pm 3.6	19.0 \pm 2.7*	46.0 \pm 3.0	27.0 \pm 3.0**
FSH (mIU/ml)	0.44 \pm 0.06	0.47 \pm 0.05	0.56 \pm 0.02	0.54 \pm 0.01
LH (mIU/ml)	0.65 \pm 0.01	0.66 \pm 0.02	0.66 \pm 0.01	0.65 \pm 0.01
Total cholesterol (mg/dl)	92.5 \pm 4.4	209 \pm 29**	96.8 \pm 5.1	102.0 \pm 27.0
Triacylglycerol (mg/dl)	198.0 \pm 7.1	245 \pm 24*	265.8 \pm 22.6	315.2 \pm 20.1*
Glucose (mg/dl)	119.0 \pm 3.0	150.0 \pm 6.0*	123.0 \pm 3.1	144.0 \pm 7.8*
Acid phosphatase (U/l)	12.9 \pm 0.8	1.18 \pm 6.0**	--	--

* Significant difference ($p < 0.05$) as compared to control. ** Highly significant ($p < 0.01$) as compared to the relevant control. The data are expressed as mean \pm SEM

Table II. Effect of oral administration of exogenous testosterone on mating success, fertility success and fertility index of albino mice. The number of paired females in each group was 10 females.

Groups	No. of mated females (2)	Mating success (%)	No. of pregnant females (3)	Fertility success (%)	Fertility index (%) (3/2) X 100
Group1 (control)	8/10	80	6/10	60	75
Group 2	2/10	20**	0/10	0**	0**
Group 3	1/10	10**	0/10	0**	0**
Group 4	0/10	0**	0/10	0**	0**

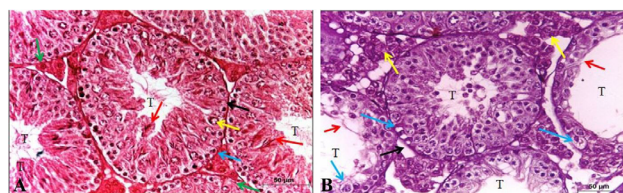
** Highly significant ($P < 0.001$)

Fig. 1. Effect of oral administration of exogenous testosterone on testes of albino rat. Histological structure of transverse section of testis of control male albino mouse showing **A:** average-sized seminiferous tubules (T) with average basement membranes (black arrow), spermatogonia (blue arrow), primary spermatocyte (yellow arrow), many sperm (red arrow) and average interstitium showing Leydig cells (green arrow). **B:** small-sized and dilated tubules (T) with thickened basement membrane (black arrow), thin germinal lining with scattered spermatogonia and primary spermatocytes with vacuolated cytoplasm (blue arrow), no sperm (red arrow), and excess interstitium with average Leydig cells (yellow arrow). Stain and Magnification H and E, X 400.

DISCUSSION

In the present study, the 25 mg/kg of synthetic testosterone (proviron drug) was orally administered to male and female albino mice for 35 days. Testosterone caused a significant increase in the body weight of both male and female treated mice. The increase in the body weight could be attributed to the increase of lipid (triacylglycerols and total cholesterol) retention in the body (Wang *et al.*, 2002) or the increase in food consumption (Swinburn *et al.*, 2004). In the current study, testosterone administration caused a significant elevation in triacylglycerols (~24% in males and ~18.5% in females), and cholesterol (~56%) in males only. It was previously reported, however, that testosterone did not cause significant changes in the body weight gain (Shittu *et al.*, 2009). Since testosterone is mainly made from cholesterol and as the synthesis of endogenous testosterone was reduced, cholesterol is expected to build up. The testosterone plays a role in the regulation of hepatic microsomal triglyceride transfer protein (MTP) expression in rats and mice (Han *et al.*,

2013). In the current study, testosterone significantly increased the level of glucose in both sexes of treated mice. Rao *et al.* (2013) found that testosterone deficiency is associated with insulin resistance and hence an elevation in the glucose level is expected. Testosterone may have direct effects on the insulin sensitivity and metabolism of glucose by increasing the expression of insulin receptors as well as by potentiating insulin signalling, resulting in enhanced glucose intake into muscle and adipose tissue (Huang *et al.*, 2018).

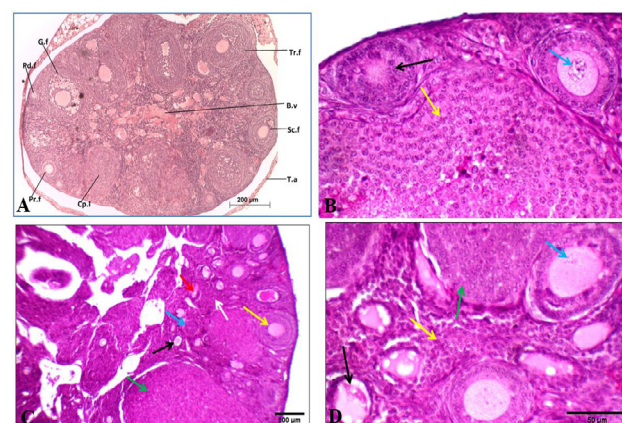


Fig. 2. Effect of oral administration of exogenous testosterone on ovary of albino mouse. A shows histological structure of transverse section of the ovary of control female albino mice showing different stages of follicles. B.v: blood vessel, Cp.l: corpus luteum Pd. f: Primordial follicle, Pr. f: primary follicle, Sc. f: secondary follicle, G.f: Graffian follicle, T.a: tunica albuginea, Tr.f: tertiary follicle. B shows control ovary showing primary (black arrow) and secondary follicles with average oocyte (blue arrow), and corpus luteum (yellow arrow). C shows primordial (black arrow), primary (blue arrow), secondary follicles (yellow arrow), and multiple corpora lutea (green arrow) in cellular stroma (white arrow). D shows ovary from treated mouse showing primordial (black arrow) and secondary follicles with degenerated oocyte (blue arrow), and multiple corpora lutea (green arrows) in cellular stroma (yellow arrow). Stain: H and E. Magnification: A: 100X; B: 400X; C: 200X; D: 400X

In the present study, testosterone caused a significant decrease in the testis weight of the treated mice which agrees with the results of previous studies (Jezek *et al.*, 1993; Shittu *et al.*, 2007). The decrease in testis weight was correlated with the decrease in the size/diameter of seminiferous tubules in testis of treated mice in the present study as was also previously reported (Jezek *et al.*, 1993; Shittu *et al.*, 2009). In the present study, testosterone has caused a significant decrease in the ovary weight of the treated female mice, a result which is similar to that reported by Sipe *et al.* (2009). They attributed the reduction in ovary weight to the degeneration of the ovary or its follicular atresia in treated mice.

In the present work, testosterone caused histopathological changes in the testis of treated male mice. These changes include thickened basement membranes, thin mildly edematous germinal lining, scattered spermatogonia, and primary spermatocytes with vacuolated cytoplasm, scattered apoptotic cells, absence of sperms in some tubules, and markedly edematous interstitium with Leydig cells showing dark black cytoplasmic inclusions. These findings were also reported by previous studies (Jezek *et al.*, 1993; Shittu *et al.*, 2006, 2007). These histopathological changes are the result of a series of hormonal interactions. The inhibition of FSH, LH, and testosterone hormones leads to a reduction in seminiferous tubules diameters and degeneration of spermatogenic cells. Testosterone acts on Sertoli and peritubular cells of the seminiferous tubules, thus affecting the process of spermatogenesis. The vacuolations observed in the cells of treated mice could be the result of disturbance of Sertoli cells which occurs under the effect of the decrease in testosterone level (Jezek *et al.*, 1993). However, in the present study, although endogenous testosterone level was drastically reduced in the males (-99%), the levels of FSH and LH did not show any significant difference. High levels of testosterone in the blood can lead to degeneration of testis and dysfunction of Leydig cells responsible for the production of testosterone. The reduction of endogenous free testosterone caused a highly significant decrease (~91%) in the activity of acid phosphatase in the treated male mice. The activity of this enzyme is synergistically controlled by testosterone (Ghosh *et al.*, 1983). When androgens decreased, the acid phosphatase level would be reduced.

In the present study, testosterone administration caused degeneration in the oocytes of the ovary or its follicular atresia in treated females. This was previously attributed to the reduction in FSH and LH levels (Tsutsumi and Webster, 2009). However, both hormones were not affected in the female mice in the present study. Another explanation is based on evidence of a direct role of androgen receptor-

mediated actions in ovarian function. Testosterone has been reported to enhance the follicle growth and development (Wang *et al.*, 2001). Any deficiency in androgens would, therefore, lead to depression in ovulation. It was also reported that androgens affected the follicle maturation stages because testosterone stimulates transition from primary to secondary follicles (Yang and Fortune, 2006). The endogenous free testosterone was significantly reduced (~27%) in the female mice in the current study. Similar results were found by Shittu *et al.* (2006). The exogenous testosterone caused a negative feedback mechanism resulting in the reduction of free testosterone (Shimon *et al.*, 2006).

Exogenous testosterone has caused a highly significant reduction in sperm count in male mice. A similar finding was reported before in rats by Shittu *et al.* (2006). The reduction in sperm count could be explained on the basis of the microscopic examination of testicular tissues that showed a significant reduction in the number of spermatogonia and spermatocytes. The above finding could be the result of reduction in the proliferation of stem cells or in spermatogenesis since large masses of seminiferous tubule epithelium appeared to be sloughed off into the tubular lumen of treated males. This is the result of the action of proviron on the androgen receptors (AR) in the testes that caused a reduction in sperm count (Shittu *et al.*, 2006). It is well known that spermatogenesis in adult males is controlled by a complex hormonal interplay of FSH and androgens. An ablation of either hormone has deleterious effects on the function of Sertoli cells and the progression of germ cells through spermatogenesis. A reduction of intratesticular androgen is, therefore, an essential factor needed for the inhibition of spermatogenesis (Shittu *et al.*, 2006). Exogenous testosterone therapies can suppress the intratesticular testosterone levels (ITT) production to such a degree that spermatogenesis can be dramatically compromised at ITT concentrations less than 20 ng/mL, and can even resulting in azoospermia (Crosnoe *et al.*, 2013). In the present study, testosterone caused a highly significant decrease (-98%) in the percentage of motile sperms in treated males. This was similar to the results of other studies where testosterone was administered into rats and humans (Van-dekerckhove *et al.*, 2000; Yang *et al.*, 2004). Testosterone is a steroid hormone synthesized from cholesterol and secreted by leydig cells under the effect of LH. Low testosterone levels led to decline in the quality of sperms (Cornwall, 2009). The reduction of testosterone without any significant changes in the levels of LH and FSH in the current study needs further investigations.

Testosterone caused a significant decrease in the concentration of estradiol in the treated males and females. Androgens are capable of inhibiting both the estrogenic

induction and the on-going stimulation of Progesterone Cytosol Receptor (PRc) synthesis (MacIndoe and Etre, 1981). The degeneration in the ovary tissue led to reduction in the level of estradiol hormone in female mice. In males, the reduction in the activity of aromatase enzyme which is responsible for the conversion of testosterone into estrogen is probably the reasonable explanation (Cooke *et al.*, 2017). Testosterone in the body is converted into two active metabolites; 17-beta estradiol (E_2) and 5-alpha dihydrotestosterone (DHT). The concentrations of E_2 and DHT have, therefore, been reduced in androgen deficient animal (Lakshman *et al.*, 2010).

In present study, untreated males were paired with untreated female; the fertility index in this group was 75%. In group 2, males treated with exogenous testosterone were paired with untreated females; the fertility index of this group was 0%. In group 3, females treated with exogenous testosterone were paired with untreated males; the fertility index of this group was 0%. In group 4, treated females were paired with treated males; the fertility index of this group was 0%. The low endogenous testosterone in the treated males causes a reduction in libido, and erectile dysfunction in males (Samplaski *et al.*, 2014). Androgens also play an important role in healthy female sexual function, especially in stimulating libido and sexual interest and in maintaining desire. There have been a number of studies that have shown a correlation between testosterone levels and sexuality of women (Bolour and Braunstein, 2005; Turna *et al.*, 2005). Female mice treated with exogenous testosterone showed aggressive behaviour against male mice which might make them less attractive or even refused by males. This aggressive behaviour is aggravated by the low concentration of estradiol in females (Denson *et al.*, 2018). Therefore, away from inducing sterility in treated mice, exogenous testosterone can also be used in provoking aggression in the populations of treated mice. Aggression behaviour is believed to ultimately cause a breakdown of the population and, consequently, a decrease in its size. It is known that female mice escape attack from males because they lack the odour; an androgen-dependent pheromone, that elicits aggression (Mertens *et al.*, 2019). When females are injected with androgens, they might stimulate an aggressive reaction by fighter males, even though they have peaceful behavior (Martin-Sanchez *et al.*, 2014). Increasing doses of androgens was accompanied by increasing weights of the clitoral (preputial in males) gland of treated female mice (Martin-Sanchez *et al.*, 2014). It is believed that this gland is the source of the pheromone which signals aggression in rodents (Donnelly and Welberg, 2011). It is thus supposed that the preputial (clitoral) gland has a possible role in controlling rodent populations. The odour from a strange male mouse (and females injected

with exogenous androgens) could increase the adrenal size and activity of other males. The aggression signal might thus play an important role in the creation of population stress and hence in its breakdown.

CONCLUSIONS

Exogenous testosterone had antifertility effects on both sexes of albino mice represented by the decline in the sperm count and motility, and acid phosphatase activity (in males), and reduction in the testosterone and estradiol levels (in both sexes). It also caused severe histopathological deteriorations in the testis and ovary, and increased glucose level, total cholesterol, and triacylglycerols. It also reduced testes and ovary weights, and fertility index. Therefore, testosterone could be used to reduce the natality of the mice which would have significant insinuations on various fields including economics, agriculture, and health.

Statement of conflict of interest

The authors have declared no conflict of interest.

REFERENCES

- Basaria, S., 2013. Reproductive aging in men. *Endocrinol. Metab. Clin. North Am.*, **42**: 255-270. <https://doi.org/10.1016/j.ecl.2013.02.012>
- Bolour, S. and Braunstein, G., 2005. Testosterone therapy in woman: A review. *Int. J. Impact Res.*, **17**: 399-408. <https://doi.org/10.1038/sj.ijir.3901334>
- Bucolo, G. and David, H., 1973. Quantitative determination of serum triglycerides by the use of the enzyme. *Clin. Chem.*, **19**: 475-480. <https://doi.org/10.1093/clinchem/19.5.476>
- Callies, F., Kollenkrichen, U., Vonzurmuhlen, C., Tomazewski, M., Beer, S. and Allolio, B., 2003. Testosterone undecanoate: A useful tool of testosterone administration in rats. *Exp. Clin. Endocrinol. Diabetes*, **111**: 203-208. <https://doi.org/10.1055/s-2003-40464>
- Cooke, P.S., Nanjappa, M.K., Chemyong, K.O., Gail, S. and Hess, R.A., 2017. Estrogens in male physiology. *Physiol. Rev.*, **97**: 995-1043. <https://doi.org/10.1152/physrev.00018.2016>
- Cornwall, G.A., 2009. New insight into epididymal biology and function. *Hum. Reprod.*, **15**: 213-227. <https://doi.org/10.1093/humupd/dmn055>
- Crosnoe, L.E., Grober, E., Ohl, D. and Kim, E.D., 2013. Exogenous testosterone: A preventable cause of male infertility. *Transl. Androl. Urol.*, **2**: 106-113.
- Denson, T.F., Dean, S.M., Blake, K.R. and Beames, J.R., 2018. Aggression in woman: Behaviour, brain

- and hormones. *Behav. Neurosci.*, **12**: 1-20. <https://doi.org/10.3389/fnbeh.2018.00081>
- Donnelly, T.M. and Welberg, J., 2011. Enlarged mouse preputial glands. *Lab. Anim.*, **40**: 69-71. <https://doi.org/10.1038/labani0311-69>
- Ellefson, R.D. and Caraway, W.T., 1976. *Fundamentals of clinical chemistry*. 6th ed Tietz, N.W. pp.506-516
- Fagerstone, K.A., Coffey, M.A., Curtis, P.D., Dolbeer, R.A., Killian, G.L., Miller, L.A. and Wilmot, L.M., 2002. Wildlife fertility control. *Wildl. Soc. Tech. Rev.*, **2**: 29.
- Ghosh, S.P., Chatterjee, T.K. and Ghosh, J.J., 1983. Synergistic role of prolactin and testosterone in the regulation of acid phosphatase activity and isoenzyme pattern in the accessory sex organs of adult male rats. *J. Reprod. Fertil.*, **67**: 235-238. <https://doi.org/10.1530/jrf.0.0670235>
- Han, C.C., Wang, J.W., Pan, Z.X., Tang, H., Xiang, S.X., Wang, J., Li, L., Xu, F. and Wei, S.H., 2013. Effect of cholesterol on lipogenesis and VLDL-TG assembly and secretion in goose primary hepatocytes. *Mol. Cell Biochem.*, **374**: 163-172. <https://doi.org/10.1007/s11010-012-1516-3>
- Huang, G., Pencina, K., Zhuoying, L. and Bhasin, S., 2018. Long term testosterone administration on insulin sensitivity in older men with low or normal-low testosterone levels. *J. clin. Endocrinol. Metab.*, **4**: 1-7. <https://doi.org/10.1210/jc.2017-02545>
- Jezek, D., Simunic-Banek, L. and Pezerovic-Panijan, R., 1993. Effects of high doses of testosterone propionate and testosterone enanthate on rat seminiferous tubules a stereological and cytological study. *Arch. Toxicol.*, **67**: 131-140. <https://doi.org/10.1007/BF01973684>
- Kalfa, N., Gaspari, L., Ollivier, M., Philibert, P., Bergougnoux, A., Paris, S. and Sultan, C., 2019. Molecular genetics of hypospadias and cryptorchidism recent developments. *Clin. Genet.*, **95**: 122-131. <https://doi.org/10.1111/cge.13432>
- Kind, P.R.N. and King, E.J., 1954. Estimation of plasma phosphatase by determination of hydrolysed phenol with amino-antipyrine. *J. clin. Pathol.*, **7**: 322-326. <https://doi.org/10.1136/jcp.7.4.322>
- Kumar, S., Singh, J., Baghotia, A., Mehta, V. and Thukur, V., 2013. Antifertility potential of the ethanolic extract of *Caesalpinia pulcherrima* Linn leaves. *Asian Pac. J. Reprod.*, **2**: 90-92. [https://doi.org/10.1016/S2305-0500\(13\)60125-6](https://doi.org/10.1016/S2305-0500(13)60125-6)
- Lakshman, K.M., Keplan, B., Trivison, T.G., Kapp, P.E. and Shalender, B., 2010. The effects of injected testosterone dose and age on the conversion of testosterone to estradiol and dihydrotestosterone in young and older men. *J. clin. Endocrinol. Metab.*, **95**: 1-10. <https://doi.org/10.1210/jc.2010-0102>
- MacIndoe, J.H. and Etre, L.A., 1981. An antiestrogenic action of androgens in human breast cancer cell. *J. clin. Endocrinol. Metab.*, **53**: 836-842. <https://doi.org/10.1210/jcem-53-4-836>
- Martin-Sanchez, A., Mclean, L., Beynon, R.L., Hurst, J.L., Lanuza, E. and Martinez-Garcia, F., 2014. From sexual attraction to maternal aggression: when pheromones change their behavioural significance. *Horm. Behav.*, **2014**: 1-42.
- Mertens, S., Vogt, M.A., Gass, P., Palme, R., Hiebl, B. and Chourbaji, S., 2019. Effect of three different forms of handling on the variation of aggression-associated parameters in individually and group-housed male C57BL/6NCrl mice. *PLoS One*, **14**: 1-14. <https://doi.org/10.1371/journal.pone.0215367>
- Miller, L.A., 2002. Reproductive control methods. In: *Encyclopedia of pest management* (ed. D. Pimental). Marcel Dekker, New York. pp. 701-707. <https://doi.org/10.1201/NOE0824706326.ch324>
- Patel, A.S., Leong, J.V., Ramos, L. and Ramasamy, R., 2018. Testosterone is a contraceptive and should not be used in men who desire fertility. *World J. Mens Hlth.*, **37**: 45-54. <https://doi.org/10.5534/wjmh.180036>
- Rao, P.M., Kelly, D.M. and Jones, T.H., 2013. Testosterone and insulin resistance in the metabolic syndrome and T2DM in men. *Nat. Rev. Endocrinol.*, **9**: 479-493. <https://doi.org/10.1038/nrendo.2013.122>
- Samplaski, M.K., Loai, Y., Wong, K., Grober, E.D. and Jarvi, K.A., 2014. Testosterone use in the male infertility population: prescribing patterns and effects on semen and hormonal parameters. *Fertil. Steril.*, **101**: 64-68. <https://doi.org/10.1016/j.fertnstert.2013.09.003>
- Shimon, I., Lubina, A., Gorfine, M. and Ilany, J., 2006. Feedback inhibition of gonadotropins by testosterone in men with hypogonadotropic hypogonadism: Comparison to the intact pituitary-testicular axis in primary hypogonadism. *J. Androl.*, **7**: 358-365.
- Shittu, L.A.J., Bankole, M.A., Oguntola, J.A., Ajala, O., Shittu, R.K., Ogundipe, O.A., Bankole, M.N., Ahmed, T. and Ashiru, O.A., 2007. The effect of the aqueous crude leaves extract of *Sesamum radiatum* compared to Mesterolone (proviron) on the adult male Sprague Dawley rats testis and epididymis. *Sci. Res. Essays*, **2**: 319-324.
- Shittu, L.A.J., Shittu, R.K., Osinubi, A.A. and Ashiru,

- O.A., 2006. Stereological evidences of epithelial hypoplasia of Seminiferous tubules induced by mesterolone in adult Sprague-Dawley rats. *Afr. J. Endocrinol. Metab.*, **7**: 21-25. <https://doi.org/10.4314/ajem.v7i1.57572>
- Shittu, L.A.J., Shittu, R.K., Osinubi, A.A. and Tayo, A.A. 2009. Mesterolone (proviron) induces low sperm quality with reduction in sex hormone profile in adult Sprague Dawley rats testis. *Sci. Res. Essays*, **4**: 320-327. <https://doi.org/10.2139/ssrn.3017596>
- Sipe, C.S., Thomas, M.R., Stegman, B.J. and Van voorhis, B.J., 2009. Effect of exogenous testosterone supplementation in gonadotrophin stimulated cycles. *Hum. Reprod.*, **25**: 690-696. <https://doi.org/10.1093/humrep/dep442>
- Steinberger, E. and Smith, K., 1977. Effect of chronic administration of testosterone enanthate on sperm production and plasma testosterone, follicle-stimulating hormone and luteinizing hormone levels; a preliminary evaluation of a possible male contraceptive. *Fertil. Steril.*, **4**: 1320-1329. [https://doi.org/10.1016/S0015-0282\(16\)42977-8](https://doi.org/10.1016/S0015-0282(16)42977-8)
- Steinkampf, M.P. and Malizia, B.A., 2011. Male infertility a common side effect of testosterone therapy. *Alabama*, **26**: 1-7.
- Swinburn, B.A., Caterson, I., Seidell, J.C. and James, W.P.T., 2004. Diet, nutrition, and the prevention of excess weight and obesity. *Publ. Hlth. Nutr.*, **7**: 123-146. <https://doi.org/10.1079/PHN2003585>
- Tatli-cankaya, I., Alqasoumi, S.I., Abdel-Rahman, R.F., Yusufoglu, H., Anul, S., Akaydin, G. and Soliman, G., 2014. Evaluating the antifertility potential of the ethanolic extracts of *Bupleurum sulphureum* and *Cichorium intybus* in male rats. *Asian J. Pharm. clin. Res.*, **7**: 211-218.
- Trinder, P., 1969. Determination of glucose in blood using glucose oxidase with an alternative oxygen receptor. *Ann. clin. Biochem.*, **6**: 24-28. <https://doi.org/10.1177/000456326900600108>
- Tsutsumi, R. and Webster, N.J., 2009. GnRH pulsatility, the pituitary response and reproductive dysfunction. *Endocrinol. J.*, **56**: 729-737. <https://doi.org/10.1507/endocrj.K09E-185>
- Turna, B., Apaydin, E., Semerci, B., Altay, B., Cikili, N. and Nazli, O., 2005. Woman with low libido: Correlation of decreased androgen levels and female sexual function index. *Int. J. Impact Res.*, **17**: 148-153. <https://doi.org/10.1038/sj.ijir.3901294>
- Van-dekerckhove, P., Lilford, R., Vail, A. and Huges, E., 2000. Androgen versus placebo or no treatment for idiopathic Oligo/asthenospermia, *Cochrane database system. Review*, **18**: CD000151.
- Wang, H. andoh, K., Hagiwara, H., Xiaowei, L., Kikuchi, N., Abe, Y., Yamada, K. and Mizunuma, H., 2001. Effect of adrenal and ovarian androgens on type 4 follicles unresponsive to FSH in immature mice. *Endocrinology*, **142**: 4930-4936. <https://doi.org/10.1210/endo.142.11.8482>
- Wang, H., Storlien, L.H. and Huang, X.F., 2002. Effects of dietary fat types on body fatness, leptin, and ARC leptin receptor, NPY, and AgRP mRNA expression. *Am. J. Physiol. Endocrinol. Metab.*, **282**: 1-8. <https://doi.org/10.1152/ajpendo.00230.2001>
- Yang, B., Wang, H., Gao, X.K., Chen, B.Q., Zhang, Y.Q., Liu, H.L., Wang, Y., Qin, W.J., Qin, R.L. and Shao, G.X., 2004. Expression and significance of Rap1A in testes of azoospermic subjects. *Asian J. Androl.*, **6**: 35-40.
- Yang, M.Y. and Fortune, J.E., 2006. Testosterone stimulates the primary to secondary follicle transition in bovine follicles *in vitro*. *Biol. Reprod.*, **75**: 924-932. <https://doi.org/10.1095/biolreprod.106.051813>