



Short Communication

Effect of Variable Degrees of Jejunal Resection on Clinical and Haematological Parameters of Cats

Tariq Mehmood¹, Muhammad Arif Khan¹, Ayesha Safder Chaudhry¹, Kamran Ashraf², Muhammad Mohsin Ali^{1,3}, Muhammad Faisal Ayoob^{3*}, Mudassir Hussain⁴, Farrukh Saleem³ and Muhammad Fayaz³

¹Department of Clinical Medicine and Surgery, University of Veterinary and Animal Sciences, Lahore 54000, Pakistan

²Department of Parasitology, University of Veterinary and Animal Sciences, Lahore 54000, Pakistan

³National Veterinary Laboratories, Ministry of National Food Security and Research, Islamabad 44000, Pakistan

⁴University of Turin, Italy

ABSTRACT

Abnormalities of intestines in carnivores such as blockage, peritonitis, tumors and diverse local injuries and lesions are corrected by resection of the intestine. Twelve cats were subjected to 3 variable degrees of jejunal resection, i.e. group A (20%) and group B (40%), while group C (0%). Sampling was performed on days 0, 15, and 30 to test various clinical and biochemical parameters. Results showed weight loss in all groups until day 15 post-surgery while in group A and C gradual weight gain was noted. Fecal consistency was observed in all the groups and noticed moist till day 15 post-surgery, which gradually turned to normal except in group B. The electrolyte parameters showed a significant difference ($P < 0.05$) in the concentration of sodium ions in group C compared to group A and B on day 15 and 30 of post-surgery. In contrast, the concentration of chloride, potassium, and bicarbonate ions was found to be insignificant. A significant difference ($P < 0.05$) was reported in various blood parameters in group A and B when compared with group C. However, all the observed values were within the normal range. It was concluded that resection of jejunum up to 20% in cats makes natural body weight gain while $\geq 40\%$ jejunal resection increases morbidity and mortality risk.

Article Information

Received 17 October 2020

Revised 24 November 2020

Accepted 24 November 2020

Available online 13 December 2021 (early access)

Published 19 July 2022

Authors' Contribution

MAK and KA designed the study and performed critical revision. TM, MMA and ASC conducted experiment and collected data. MFA, FS and MF analyzed the data. MFA, MH and MMA wrote the article.

Key words

Clinical parameters, Electrolytes, Haematological parameters, Jejunum, Resection

The alimentary tract provides different nutrients to the body. It consists of small and large intestines, performing various functions such as passageways, secretions of digestive juices, absorption of electrolytes, and food crashes while entire intestines are concerned with feed digestion and assimilation (Guyton and Hall, 2005; Dilawer *et al.*, 2011). The small intestine consists of three portions; the jejunum is the most extended linking piece between the duodenum and ileum and is free to move into whatever occupied space is available within the abdomen. In carnivores, coils of jejunum reside on the ventral part

of the abdomen between bladder and stomach stacked over the greater omentum. The extended meso-jejunum imposes little self-control which allows the gut to be in motion without restraint, in reaction to respiratory and other movements (Konig *et al.*, 2004).

Anastomosis and resection of the intestine very frequently performed in small animals kept as pets. In small animals, different lesions, and abnormalities of intestines like involuntary obstructions, local peritonitis, and tumors were corrected by resection of the intestine. Up to 80% jejunal resection in pets permits ordinary weight gain but above this leads to death (Bojrab *et al.*, 1998).

Short bowel syndrome is characterized by malabsorption and malnutrition, which happens after wide-ranging resection of the small intestine. Short bowel syndrome has been initiated in dogs with resection of 70% intestine without any special treatment. Due to invariably watery diarrhea weight loss is reported in many clinical cases. The prognosis for go back to satisfactory function with short bowel syndrome depends on the degree of

* Corresponding author: ayoob.faisal@yahoo.com
0030-9923/2022/0005-2465 \$ 9.00/0



Copyright 2022 by the authors. Licensee Zoological Society of Pakistan.

This article is an open access article distributed under the terms and conditions of the Creative Commons Attribution (CC BY) license (<https://creativecommons.org/licenses/by/4.0/>).

resection, degree of adaptation, the health of the remaining gastrointestinal system, and the postoperative condition of the animal (Slatter, 2002). Current research based on available reports to explore the effects of jejunal resection in cats at a diverse length of jejunum, i.e. 20% and 40% on particular clinical and biochemical parameters to observe the impact on general health, blood CBC, electrolytes, wound healing, and fecal parameters.

Materials and methods

The study was conducted on a total of 12 cats of both sexes, ranging from 1- 2 years of age and was purchased from the local market (Lahore-Pakistan). All cats were shifted to cages, ten days before the start of surgeries to acclimatize them friendly handling and physical examination. Cats were examined thoroughly to rule out any GIT abnormality and systemic ailment before the surgery. All cats were maintained on the same nutritional regimen, allowing the water ad libitum, and housed in a stress-free aseptic environment. The cats were allocated into three different groups viz A, B, and C having four cats in each group. Resection of jejunum was performed with varying percentages as in group A 20% and in group B 40%. Whereas group C serves the control group with only end to end anastomosis without resection, and all the parameters compared with resected groups. The surgical intervention was performed at the operation theatre of Clinical Medicine and Surgery (CMS) Department of University of Veterinary Sciences Lahore- Pakistan.

All the procedures in the present work were approved and performed in compliance with the institutional guidelines of the Ethical Review Committee. All the surgical equipment was autoclaved and sterilized one day before performing surgery. Cats off fed 10-12 hours before performing surgery. The surgical site of the patient was clipped and shaved with a razor to minimize the contamination, and then scrubbed with an antiseptic (Pyodine). Sterile surgical drapes were positioned around the surgical vicinity. Sterilized gown, disposable gloves, masks, and caps worn to carry out proper aseptic surgery.

A combination of anesthetic drugs Ketamine, Xylazine, and Atropine sulfate in a ratio of 7:2:1 (0.7 ml + 0.2 ml + 0.1 ml) used for the anesthesia, injected intramuscularly at the hind leg by using 1ml disposable insulin syringe. The dose rate was planned according to the body mass of the animal (Slatter, 2002). The patient was positioned in dorsal recumbency for the 'midline laparotomy incision' to expose the jejunum. An incision of 5-8 cm was made at the surgical site with the help of a surgical blade (No. 24), considered umbilicus as a landmark. Undermining was performed till an incision was made to 'linea alba' and reached into the abdominal cavity. Retractors were used to see the abdominal visceral

organs and the jejunum was manually exposed and handled gently to avoid shock by keeping moistened through the normal saline sponge. The jejunum in each cat ascertained through distinguishing coils of it. The length of jejunum was measured and then exteriorized in each group as mentioned (i.e. 20% Group A, 40% Group B, 0 % Group C) through the celiotomy incision. After performing jejunal resection, the incision site closed in three layers from inward to outward, i.e. linea alba with simple interrupted suture technique using 2/0 absorbable suture material, Sub-cut tissue with the simple continuous pattern using 3/0 chromic catgut absorbable suture material, and skin with simple interrupted suture technique using 3/0 non-absorbable silk material (Slatter, 2002). After the surgery, all the cats were kept on intravenous nutrition for 2-3 days, and after that soft oral feed was given.

A physical examination was performed to judge health with weight loss or gain at day 0, 15, and 30 postoperatively. Blood was collected in EDTA vacutainers at 0, 15, and 30 days post-surgery and was analyzed for various hematological parameters by auto hematological analyzer (SPHERA), and for

sodium, potassium, chloride, and bicarbonate ions concentration in serum by atomic absorption spectrometer (PerkinElmer Analyst 400) on day 0, 15 and 30 post-surgery. The consistency of feces was evaluated by grading as 1) watery 2) moist and 3) soft and firm to see the activity status of small intestines (Dilawer *et al.*, 2011). Wound healing was evaluated by scoring it as score 1 (poor healing), score 2. (partial healing) and score 3 (properly healing). The data analysis was done through a one-way analysis of variance (ANOVA) using IBM SPSS, ver.23 (Zar, 1999).

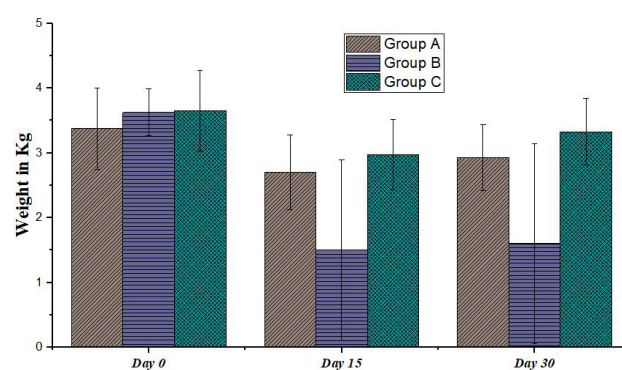


Fig. 1. Bodyweight of the studied groups at different days.

Results and discussion

Loss in weight (Debilitation) was observed in all the groups (Fig. 1), but gradually weight gain was noted except B group in which 40% jejunal resection was performed

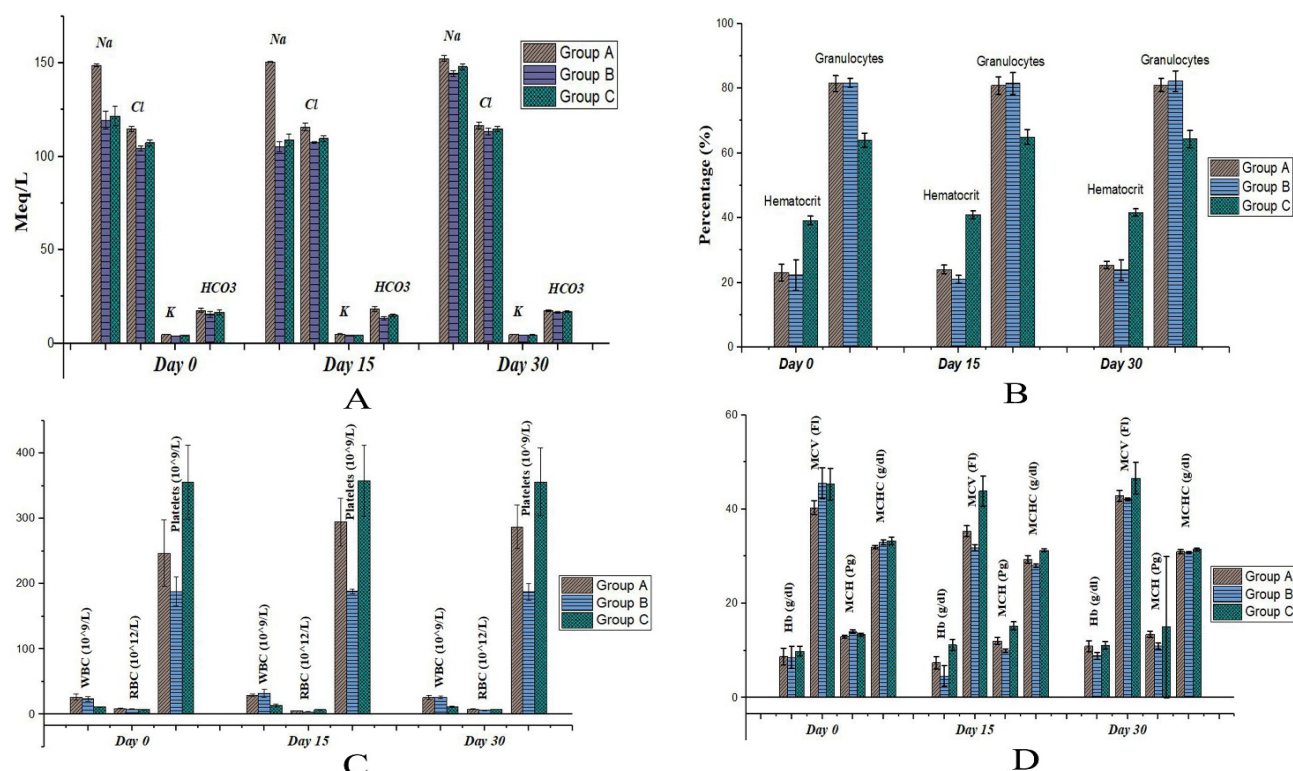


Fig. 2. Effect of jejunal resection on the (A) electrolytes, (B) hematocrit and granulocytes, (C) WBC, RBC and platelets, (D) hemoglobin, MCV, MCH and MCHC on different days after resection.

(Yamada *et al.*, 1978; Dilawer *et al.*, 2011). Fecal consistency remains moist in pets after having intestinal surgery and improved gradually over a period (Wolf *et al.*, 1979), which is in line with the results of the present study except in group B where fecal consistency remained moist till day 30 post-surgery. Gradual healing was observed in all animals except for two cats. All cats utterly healed at the end of the research. Resection showed no significant change in potassium, chloride, and bicarbonate ion's value throughout the study (Fig. 2A) which is in line with the studies of Fabritius *et al.* (1986) and Vazquez *et al.* (1988). The hematocrit of A and group B was significantly lower from control after surgery. WBCs and granulocytic count were significantly higher in A and B group from the control group on different study intervals (Fig. 2B). RBCs count of both groups A and B was substantially lesser than the control group, and the number increased over time (Fig. 2C). For platelets count, there was a significant difference in all the groups, all observed values; were within the normal range as also reported by Astre *et al.* (1992) and Dilawer *et al.* (2011). Hemoglobin, MCHC, and MCV values of both groups A and B were observed significantly lower than control at different intervals (Fig. 2D). At the same time, MCH was lower

throughout the research than group C. The sodium-ion concentration of A group was considerably higher from group B and C after jejunal resection (Nightingale, 2001). It was concluded in the present research that 20% jejunectomy had shown no injurious effect on the health of cats while 40% jejunal resection seriously affects physiology, clinical and biochemical parameters in cats.

Statement of conflict of interest

The authors have declared no conflict of interest.

References

- Astre, C., Gouttebel, M.C., Saint-Aubert, B., Girardot, P.M., Briand, D. and Joyeux, H., 1992. *Clin. Nutr.*, **11**: 30–34. [https://doi.org/10.1016/0261-5614\(92\)90060-4](https://doi.org/10.1016/0261-5614(92)90060-4)
- Bojrab, M.J., Ellison, G.W. and Slocum, B., 1998. *Current techniques in small animal surgery*. 4th eds., Williams and Wilkins, Baltimore, Md, London.
- Dilawer, M.S., Khan, M.A., Abidin, Z.U., Azeem, S., Majeed, K.A., Shahbaz, A. and Khan, A.R., 2011. *Korean J. Vet. Res.*, **51**: 309–313.
- Fabritius, J., Nell, G. and Loeschke, K., 1986. *Pfl. Arch. Eur. J. Physiol.*, **406**: 328–332. <https://doi.org/10.1007/BF01196400>

- [org/10.1007/BF00640923](https://doi.org/10.1007/BF00640923)
- Guyton, A.C. and Hall, J.E., 2005. *Textbook of medical physiology*. W.B. Saunders, Philadelphia.
- Konig, H.E., Liebich, H.G. and Bragulla, H., 2004. *Veterinary anatomy of domestic mammals: Textbook and colour atlas*. Schattauer. <https://books.google.com.pk/books?id=54RVGMmon10C>
- Nightingale, J.M.D., 2001. *World J. Gastroenterol.*, **7** (6): 741–751. <https://doi.org/10.3748/wjg.v7.i6.741>
- Slatter, D.H., 2002. *Textbook of small animal surgery*. PA, Saunders, Philadelphia.
- Vazquez, C.M., Molina, M.T. and Ilundain, A., 1988. *Rev. Esp. Fisiol.*, **44**: 141–145. <http://www.ncbi.nlm.nih.gov/pubmed/3194570>
- Wolf, S.A., Telander, R.L., Go, V.L.W. and Dozois, R.R., 1979. *J. Pediat. Surg.*, **14**: 441–445. [https://doi.org/10.1016/S0022-3468\(79\)80011-1](https://doi.org/10.1016/S0022-3468(79)80011-1)
- Yamada, S., Mayahara, T., Maruyama, I., Shibanoki, S., Tokuyoshi, K. and Iso, A., 1978. *Nih. Yakuri. Zass.*, **74**: 49–60. <https://doi.org/10.1254/fpj.74.49>
- Zar, J.H., 1999. *Biostatistical analysis*. Upper Saddle River, N.J, Prentice Hall.