



# Time-Based Effects of *Xanthium strumarium* Extract on Rats

Hakan Kececi<sup>1\*</sup>, Yasin Ozturk<sup>2</sup>, M. Bahaeddin Dortbudak<sup>3</sup>, Seda Yakut<sup>4</sup>, Gurdal Dagoglu<sup>5</sup> and Merve Ozturk<sup>1</sup>

<sup>1</sup>Division of Clinical Sciences, Faculty of Veterinary Medicine, Bingol University, Bingol 12000, Turkey.

<sup>2</sup>Department of Pharmacology and Toxicology,, Faculty of Veterinary Medicine, Bingol University, Bingol 12000, Turkey

<sup>3</sup>Department of Pathology, Faculty of Veterinary Medicine, Bingol University, Bingol 12000, Turkey

<sup>4</sup>Department of Histology, Faculty of Veterinary Medicine, Bingol University, Bingol 12000, Turkey

<sup>5</sup>Department of Pharmacology and Toxicology,, Faculty of Veterinary Medicine, Firat University, Elazig 23000, Turkey

## ABSTRACT

This study is aimed to determine the toxicity of *Xanthium strumarium* L. (cocklebur) or its seeds to human or an animal. Cocklebur, potentially toxic plants is found abundantly in meadows and pastures. One of the most significant ingredients that causes toxicity is atractyloside (ATR). In this study, the concentration of ATR in cocklebur seeds was determined as 4 mg/g seed. The study involved 54 rats which were divided into a total of 9 groups including one control group. A single dose of cocklebur seed extract was provided by gavage after being concentrated by 2 ml for each animal (80 mg ATR/kg) except for those in the control group, and time-dependent hepatotoxic, nephrotoxic, hematological and biochemical effects were analyzed. No histopathological change was detected in the liver and kidney tissues of the rats in the experimental groups. Both hematological and serum biochemical values (Ca, P, TBIL, ALT, AST, ALP, Urea, and Creatinine) were within the physiological limits in all groups. Consequently, in light of the obtained data, it was observed that the rats were not exposed to any toxic effect even when they consumed a stomach full of cocklebur fruit at once.

## Article Information

Received 04 June 2021

Revised 03 October 2021

Accepted 15 October 2021

Available online 15 April 2022

(early access)

Published 19 August 2022

## Authors' Contribution

HK, YÖ and GD designed the study. YÖ, MBD and SY executed the study. HK and MÖ implemented the study and involved in sampling as well as testing. MÖ, SY and GD drafted the manuscript.

## Key words

Cocklebur, *Xanthium strumarium*, Atractyloside, Toxication, Hepatotoxicity, Nephrotoxicity

## INTRODUCTION

*Xanthium strumarium* L. (cocklebur) is an annual plant, about 20-90 cm in height, with an upright, branched stem, usually with purple spots, and short white hairs scattered over its surface (Fig. 1). As a result of various studies, the plant was revealed to have biological effects such as antibacterial (Sato *et al.*, 1997), anti-inflammatory (Yeom *et al.*, 2015), antiparasitic (Talakai *et al.*, 2015), antidiabetic (Sridharamurthy, 2011), antioxidant (Ishwarya and Singh, 2010), and antiviral (Kumar *et al.*, 2016). Due to these biological effects, *Xanthium* species are used for the

treatment of bacterial infections, inflammatory diseases such as diabetes, skin itching, rhinitis, and rheumatoid arthritis, and cytotoxicity and antitumor activities (Fan *et al.*, 2019).

Until now, many phytochemical studies were carried out on *X. strumarium* and more than 170 compounds were isolated from this plant. Among these, sesquiterpenes and phenylpropanoids are the most abundant and the major bioactive components in the *X. strumarium* (Kamboj and Saluja, 2010; Fan *et al.*, 2019). Previous pharmacokinetic studies have generally focused on active compounds of toxic components such as xanthanthin, cryptochlorogenic acid, and atractyloside (ATR) (Yan *et al.*, 2014; Ozturk *et al.*, 2021). However, in 1990, ATR and carboxy-atractyloside (CATR), which have moderate or high allergenic and toxic effects of *X. strumarium*, were accepted as major toxic compounds (Piozzi, 1978).

In some literature, it was reported to be a well-known highly toxic plant or even for grazing animals such as cattle, pigs, horses, poultry (Witte *et al.*, 1990; Masvingwe and Mavengwa, 1998). In recent years, many studies

\* Corresponding author: [hkececi@bingol.edu.tr](mailto:hkececi@bingol.edu.tr)  
0030-9923/2022/0006-2681 \$ 9.00/0



Copyright 2022 by the authors. Licensee Zoological Society of Pakistan.

This article is an open access article distributed under the terms and conditions of the Creative Commons Attribution (CC BY) license (<https://creativecommons.org/licenses/by/4.0/>).

have demonstrated the toxic effects and mechanisms of *X. strumarium* extracts and monomers. Different doses of *X. strumarium* fruit extract were administered orally or intraperitoneally to rats and mice, and some biochemical parameters in serum were examined; of these animals, liver weight increased as a sign of liver damage, serum Alanine aminotransferase (ALT), aspartate aminotransferase (AST), alkaline phosphatase (ALP), activity and total bilirubin (TBIL) levels increased and the damage became more severe as the dose increased (Xue *et al.*, 2014).



Fig. 1. Leaves and seeds of *Xanthium strumarium* (cocklebur) plant.

It has been demonstrated that when ingested by animals in sufficient quantities through the digestive tract, it produces hypoglycemia and liver damage, and this damage is likely due to increased vascular permeability in response to severe hypoglycemia. It has been suggested that its mechanism of action is the disruption of oxidative phosphorylation, which is a necessary process for the cell's energy metabolism and transfer system (Vignais *et al.*, 1978; Stuart *et al.*, 1981; Vancompernelle *et al.*, 1998; Dharmanada, 2002; Turgut *et al.*, 2005; Schütt *et al.*, 2012). In addition to CATR, the plant is known to contain potentially toxic components such as sesquiterpene lactone, which can cause vomiting, weakness, tremors, weak pulse, inappetence, and convulsions in high doses. Significant hypoglycemia elevated serum glutamate oxaloacetate transaminase, and serum isocitric dehydrogenase concentrations were detected in pigs with acute hepatic necrosis who ingested plant seedlings or carboxy-atracylosides (Stuart *et al.*, 1981; Ozturk *et al.*, 2021). In a fatal case in humans, in addition to the increase in liver enzymes, blood urea and creatinine levels increased, and metabolic acidosis occurred with hypoglycemia. Creatine

phosphokinase (CPK) value, which is an indicator of myocardial damage also increased in all patients, especially in fatal cases (Nikles *et al.*, 2015).

Generally, the effects of atracyloside poisoning start with skin rash, gastrointestinal irritation (loss of appetite, nausea, vomiting, abdominal pain), and ataxia due to contact with the plant. They continue with muscle weakness, severe depression, convulsions, sweating, aggression, spasmodic contractions, tremor, fasciculations of the leg and neck muscles, and incoordination in walking. Later, blindness, myocardial dysfunction (hypotension, fast and/or weak pulse), difficulty in breathing, weakness, hypothermia, and subsequently, death is observed. Death occurs within a few hours to 3 days after the onset of the symptoms (Turgut *et al.*, 2005; Witte *et al.*, 1990).

In experimental studies, ATR has been found to cause necrosis in liver and kidney tissue (Turgut *et al.*, 2005; Xue *et al.*, 2014; Carpenedo *et al.*, 1974; Obatomi and Bach, 1998). Histopathologically, necrosis in the liver and kidney tissue, increased permeability and microvascular hemorrhage in the cerebrum and cerebellum, leukocyte infiltration in the muscles, pancreas, lungs, and myocardium, hepatomegaly with lobular emphasis, edema in the gallbladder wall, obstruction in the liver and kidneys, and water accumulation in body fluids have been noted. Along with congestion and bleeding in the liver, centrilobular hepatocytes characterized by acute diffuse necrosis can be observed as the most obvious microscopic findings (Turgut *et al.*, 2005; Witte *et al.*, 1990; Botha *et al.*, 2014). Other histological lesions are degenerative changes in the myocardium and kidneys, neuronal degeneration in the brain, and cerebral edema. Increased vascular permeability causes severe hemorrhagic lesions in the myocardium, gall bladder, and peritoneal cavity.

Coagulation and hemorrhagic hepatic necrosis are frequently observed in histopathological samples in poisoned animals (Bhoola, 1983; Witte *et al.*, 1990; Obatomi *et al.*, 2001; Botha *et al.*, 2014). The coagulation disorder, hypoglycemia, liver failure observed in cocklebur poisoning indicate that prognosis is poor as well. Since there is no specific antidote, treatment is performed symptomatically (Saidi and Mofidi, 2009). In order to reduce absorption, it is appropriate to initially lavage the stomach and administer activated charcoal (Turgut *et al.*, 2005). Administering fluid therapy to relieve dehydration, dextrose to correct hypoglycemia, anticonvulsant drugs to control seizures, fresh plasma and vitamin K to reduce the risk of bleeding, B complex vitamin as a source of cytochrome P450/cytochrome P448 activator 3 hydrolysis cobalamin, and drugs such as NSAID-phenylbutazone to reduce the cytotoxic effect of the compound by stimulating detoxification due to the non-cytochrome P450 enzyme

system can be listed as the treatment (Turgut *et al.*, 2005; Stewart and Steenkamp, 2000). However, none of them could provide a successful and sufficient treatment (Turgut *et al.*, 2005; Stewart and Steenkamp, 2000).

## MATERIALS AND METHODS

### *Experimental animals*

Fifty-four Wistar Albino rats, 7-8 weeks old, weighing 250-300 g, were obtained from Bingol University Experimental Animal Research Center. The study was carried out in a special room in the same research center, with a temperature of  $22-24 \pm 2^\circ\text{C}$  and a humidity of  $55 \pm 5\%$ . The first week was the acclimatization period of the rats. The inlet and outlet air of the test environment was filtered. A foot pool containing disinfectant was placed at the entrance of the door. The light intensity of the room was adjusted to 40 lux (12 h dark and 12 h light with a white fluorescent lamp).

During the experiment, animals received commercial pellet rat feed (consisting of 88.2% dry matter, 23.1% crude protein, 2.6% crude fat, 5% crude fiber, 7.1% crude ash, and 0.50% sodium) with *ad libitum* access. The pads of the rats were changed every other day. Feeders and drinkers were checked and cleaned regularly every day.

### *Ethics committee approval*

In this study, the approval was obtained from the Bingol University Animal Experiments Local Ethics Committee (with the decision dated 20.02.2017, meeting number 2017/02, and numbered 02/04) in order to use experimental animals and perform the specified experimental procedures on experimental animals.

### *Experimental plan and collection of blood and tissue samples*

In this study, 2 main groups were formed as control ( $n = 6$ ) and experimental group. The experimental group was divided into 8 separate subgroups. A total of 54 male Wistar albino rats, as 6 rats for each subgroup ( $n = 6$ ), were used. The seeds of the dried fruits of the plant *Xanthium strumarium* L. were ground and extracted (Gaillard and Pepin, 1999) and 4 mg of ATR was detected in 1 g of seed. Each of the rats in all groups except the control was administered the extract containing 80mg of ATR/kg orally (20mg/2ml) by the gavage method. The control group was administered physiological saline by gavage. Liver and kidney tissues, and blood samples were taken from control group at the 0<sup>th</sup> h, from the 2<sup>nd</sup> group at the 4<sup>th</sup> h, from the 3<sup>rd</sup> group at 6<sup>th</sup> h, from the 4<sup>th</sup> group at the 12<sup>th</sup> h, from the 5<sup>th</sup> group at the 24<sup>th</sup> h, from the 6<sup>th</sup> group at the 36<sup>th</sup> h, from the 7<sup>th</sup> group at the 48<sup>th</sup> h, from the 8<sup>th</sup> group at the 72<sup>nd</sup> and from the 9<sup>th</sup> group at the 96<sup>th</sup> h after a single dose was

administered.

First, all rats were anesthetized using Sevoflurane (230 ppm dose). Blood was taken from anesthetized rats firstly by intracardiac route, and then euthanasia was performed by decapitation. In necropsy, kidney and liver tissues of all animals were taken and placed in 10% buffered formaldehyde. Before the anesthesia, blood was collected from the tail vein in the rats in the control group at the 0<sup>th</sup> h for complete blood count and biochemical analysis.

### *Processing and preparation of the blood and tissue samples*

Tissues (0.2 cm<sup>3</sup>) fixed in 10% buffered formaldehyde solution were placed in plastic tissue processing cassettes in accordance with the group sequences. The samples in the plastic tissue processing cassettes were placed in the re-fixation (NBF) solution, allowing the tissues to be fixed for the second time for 24 h. Tissues were washed under running tap water for 24 h and then kept successively in 70%, 80%, 90% and 96% alcohol in order to dehydrate the tissues. Tissues were kept in 96% alcohol for 1.5 h for the second time. Then, the tissues were kept in absolute (100%) alcohol for 1 h and in 2<sup>nd</sup> absolute alcohol for 1.5 h. Thus, in order to make the dehydrated tissues transparent, they were kept in xylol solution for one hour (I. Xylol) and 1.5 h (II. Xylol), respectively. The tissues were kept in the first paraffin chamber (paraffin melted at 56°C) for 2 h. Finally, the tissues were kept for 3 h in the second paraffin chamber (paraffin melted at 56°C).

Paraffin blocks were made, 4µm thick sections were cut and then stained with the hematoxylin-eosin (Bancroft *et al.*, 2013).

Hematological complete blood counts were performed using JTBaker® brand reagents and Avantor BeneSphera H32 model hematology analyzer (Bene Sphera Guide; Patricia, 1993; Issi and Gul, 2012) and blood serum was used for estimation of Ca, P, alanine aminotransferase (ALT), aspartate aminotransferase (AST), alkaline phosphatase (ALP), activity and total bilirubin (TBIL), urea and creatinine using Randox Rx Monaco model autoanalyzer.

### *Determination of ATR levels in blood*

Blood (1 ml) was mixed with 1 ml of acetone and centrifuged at 3500g for 10 min. The supernatant obtained was dried at 45°C under nitrogen gas, dissolved 1 ml of distilled water to which 2 ml of hydrochloric acid (2mol/l) was added and vortexed and kept in this state for 12 h. The hemolysate was centrifuged at 3500g for 5 min and the upper phase was transferred to another glass tube. Ethyl acetate (2 ml) was added to the formed hydrolysate and after mixing with vortex for 2 min, it was centrifuged at 3500 g for 5 min. The organic extract collected in a



separate tube was dried under nitrogen gas at 45°C. 100 µl pyridine and 100 µl (trimethylsilyl) imidazole were added to the dried extract and derivatized for 2 h at 100 °C. At the end of the derivatization for two h, 2 µl of the sample was injected into the GC-MS device, and readings were taken (Laurens *et al.*, 2001).

#### Statistical analysis

IBM®SPSS 22 software was used for statistical analysis. Data are presented as mean and standard errors. The analysis of the data that did not meet the parametric assumptions was carried out using the Tukey test.

## RESULTS

#### Histological effect

Figure 2 shows effect of *X. strumarium* on the liver, while Figure 3 shows effect on kidney until 96h after administration. No difference was found in the histopathological examination of the liver and kidney tissues of the rats in the control and experimental groups after the time-based application of the plant extract.

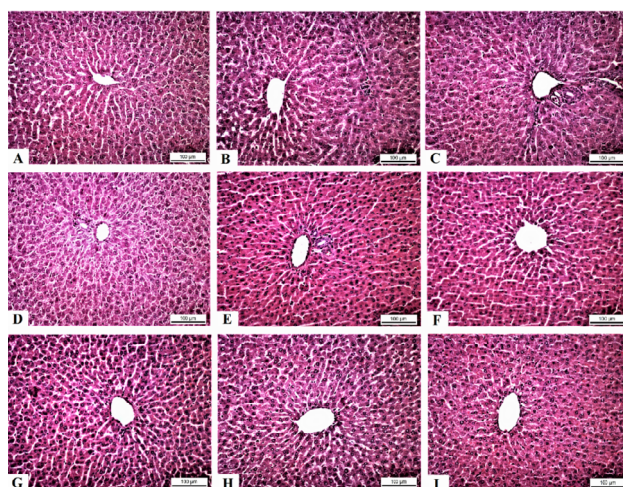


Fig. 2. Effects of *Xhantium strumarium* extract given orally to rats at different times on liver. Histological views of the liver tissues in all groups are normal. HE. 20µ. (A) Group 1-Normal histological appearance in the control group that did not undergo any procedure; (B) Group 2-Histological appearance of the liver at the 4<sup>th</sup> h; (C) Group 3-Histological appearance of the liver tissue at the 6<sup>th</sup> h; (D) Group 4-Histological appearance of the liver tissue at the 12<sup>th</sup> h; (E) Group 5-Histological appearance of the liver tissue at the 24<sup>th</sup> h; (F) Group 6-Histological appearance of the liver tissue at the 36<sup>th</sup> h; (G) Group 7-Histological appearance of the liver tissue at the 48<sup>th</sup> h; (H) Group 8-Histological appearance of the liver tissue at the 72<sup>nd</sup> h; (I) Group 9-Histological appearance of the liver tissue at the 96<sup>th</sup> h.

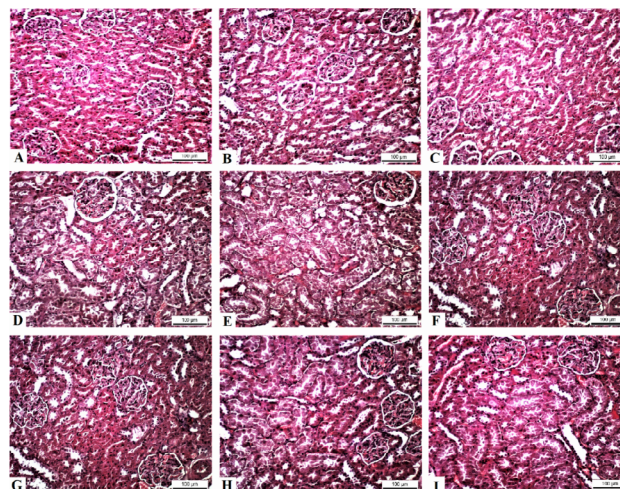


Fig. 3. Effects of *Xhantium strumarium* extract given orally to rats at different times on kidney. Histological views of the kidney tissues in all groups are normal. HE. 20µ. (A) Group 1-Normal histological appearance in the control group that did not undergo any procedure; (B) Group 2-Histological appearance of the kidney at the 4<sup>th</sup> h; (C) Group 3-Histological appearance of the kidney tissue at the 6<sup>th</sup> h; (D) Group 4-Histological appearance of the kidney tissue at the 12<sup>th</sup> h; (E) Group 5-Histological appearance of the kidney tissue at the 24<sup>th</sup> h; (F) Group 6-Histological appearance of the kidney tissue at the 36<sup>th</sup> h; (G) Group 7-Histological appearance of the kidney tissue at the 48<sup>th</sup> h; (H) Group 8-Histological appearance of the kidney tissue at the 72<sup>nd</sup> h; (I) Group 9-Histological appearance of the kidney tissue at the 96<sup>th</sup> h.

#### Mean atractyloside levels in blood samples

Table I shows ATR level (mg/ml) of blood samples taken from control and experimental groups after gavage application. The maximum level was observed 36h after the extract administration.

**Table I. Effect of ocklebur extract on the level of atractyloside in the blood of rats.**

Blood collection time	ATR levels (mg/dl)
0 <sup>th</sup> h (Control)	0
4 <sup>th</sup> h (2 <sup>nd</sup> Group)	0
6 <sup>th</sup> h (3 <sup>rd</sup> Group)	0.033 ± 0.004
12 <sup>th</sup> h (4 <sup>rd</sup> Group)	0.069 ± 0.030
24 <sup>th</sup> h (5 <sup>th</sup> Group)	5.110 ± 0.052
36 <sup>th</sup> h (6 <sup>th</sup> Group)	7.092 ± 0.053
48 <sup>th</sup> h (7 <sup>th</sup> Group)	10.803 ± 0.049
72 <sup>nd</sup> h (8 <sup>th</sup> Group)	1.830 ± 0.038
96 <sup>th</sup> h (9 <sup>th</sup> Group)	0.727 ± 0.064

*Haematological parameters*

Table II shows effect of cocklebur extract administered by gavage on haematological parameters of rats. No significant deviation was observed in the experimental group when compared with the control.

*Blood serum biochemical components*

Tables III and IV respectively show effect of cocklebur extract on renal function and liver function tests of rats. There was no statistically significant difference (p) between different experimental groups.

**Table II. Effect of cocklebur extract administered by gavage on haematological parameters in rats.**

Group	n	WBC (K/ $\mu$ L)	Lymphocyte (%)	Neutrophil (%)	RBC (M/ $\mu$ L)	Platelet (K/ $\mu$ L)	Hct (%)	Hb (g/dl)
1	6	13.88 $\pm$ 0.74	72.01 $\pm$ 3.11	23.33 $\pm$ 2.28	6.50 $\pm$ 0.41	742.67 $\pm$ 96.4	32.48 $\pm$ 2.13	13.98 $\pm$ 0.85
2	6	14.37 $\pm$ 0.71	70.33 $\pm$ 2.60	25.12 $\pm$ 2.59	7.24 $\pm$ 0.32	522.56 $\pm$ 66.64	37.55 $\pm$ 1.74	16.36 $\pm$ 0.49
3	6	14.57 $\pm$ 0.87	68.82 $\pm$ 3.86	22.50 $\pm$ 2.01	7.76 $\pm$ 0.52	603.04 $\pm$ 98.49	35.02 $\pm$ 1.69	14.81 $\pm$ 0.27
4	6	13.35 $\pm$ 1.20	72.92 $\pm$ 2.31	21.38 $\pm$ 1.51	6.82 $\pm$ 0.46	593.93 $\pm$ 105.12	39.06 $\pm$ 1.51	16.27 $\pm$ 0.74
5	6	13.79 $\pm$ 1.49	69.57 $\pm$ 3.39	22.70 $\pm$ 1.68	7.60 $\pm$ 0.33	536.67 $\pm$ 51.12	37.17 $\pm$ 0.73	16.53 $\pm$ 0.61
6	6	13.88 $\pm$ 1.17	69.50 $\pm$ 3.30	22.74 $\pm$ 2.10	7.89 $\pm$ 0.29	566.67 $\pm$ 95.18	39.93 $\pm$ 2.34	16.17 $\pm$ 0.5
7	6	13.71 $\pm$ 1.13	71.93 $\pm$ 2.93	20.74 $\pm$ 2.12	7.58 $\pm$ 0.39	569.67 $\pm$ 167.1	37.23 $\pm$ 1.33	16.23 $\pm$ 0.38
8	6	14.08 $\pm$ 0.65	70.85 $\pm$ 1.77	25.20 $\pm$ 1.52	7.73 $\pm$ 0.65	491.67 $\pm$ 77.37	38.03 $\pm$ 2.77	16.13 $\pm$ 1.03
9	6	14.08 $\pm$ 0.65	72.35 $\pm$ 2.99	21.61 $\pm$ 1.76	7.55 $\pm$ 0.06	702.33 $\pm$ 109.71	36.75 $\pm$ 0.46	16.3 $\pm$ 0.31

For details of groups, see Table I.

**Table III. Effect of cocklebur extract administered by gavage on renal function tests in rats.**

Group	n	Time (h)	Ca (mg/dl)	P (mg/dl)	Urea (mg/dl)	Creatinine(mg/dl)
1	6	0	9.83 $\pm$ 0.33	6.88 $\pm$ 0.37	18.03 $\pm$ 0.50	0.58 $\pm$ 0.02
2	6	4	10.60 $\pm$ 0.19	5.91 $\pm$ 0.23	16.64 $\pm$ 0.68	0.53 $\pm$ 0.02
3	6	6	10.76 $\pm$ 0.27	6.17 $\pm$ 0.34	16.93 $\pm$ 1.06	0.55 $\pm$ 0.02
4	6	12	10.55 $\pm$ 0.26	5.96 $\pm$ 0.42	16.33 $\pm$ 0.80	0.57 $\pm$ 0.04
5	6	24	10.80 $\pm$ 0.30	5.81 $\pm$ 0.40	15.21 $\pm$ 0.86	0.61 $\pm$ 0.04
6	6	36	10.54 $\pm$ 0.21	6.22 $\pm$ 0.40	16.65 $\pm$ 0.50	0.58 $\pm$ 0.03
7	6	48	10.58 $\pm$ 0.20	6.53 $\pm$ 0.58	17.02 $\pm$ 0.72	0.54 $\pm$ 0.04
8	6	72	10.98 $\pm$ 0.20	6.08 $\pm$ 0.14	16.47 $\pm$ 0.43	0.62 $\pm$ 0.04
9	6	96	10.42 $\pm$ 0.24	6.47 $\pm$ 0.51	15.50 $\pm$ 0.49	0.54 $\pm$ 0.03

**Table IV. Effect of cocklebur extract administered by gavage on liver function tests in rats.**

Group	n	Time (h)	T.Bilirubin (mg/dl)	ALT (mg/dl)	AST (mg/dl)	ALP (mg/dl)
1	6	0	0.06 $\pm$ 0.01	72.00 $\pm$ 1.67	191.67 $\pm$ 16.02	143.50 $\pm$ 28.07
2	6	4	0.05 $\pm$ 0.01	69.50 $\pm$ 0.99	221.00 $\pm$ 6.92	178.17 $\pm$ 16.45
3	6	6	0.04 $\pm$ 0.01	70.33 $\pm$ 3.31	191.33 $\pm$ 17.89	155.17 $\pm$ 22.74
4	6	12	0.03 $\pm$ 0.01	69.00 $\pm$ 2.77	191.83 $\pm$ 14.56	165.17 $\pm$ 22.04
5	6	24	0.04 $\pm$ 0.01	70.50 $\pm$ 6.38	188.83 $\pm$ 13.46	110.33 $\pm$ 8.37
6	6	36	0.04 $\pm$ 0.01	71.33 $\pm$ 4.71	187.67 $\pm$ 11.13	155.50 $\pm$ 26.56
7	6	48	0.03 $\pm$ 0.01	76.50 $\pm$ 4.39	214.17 $\pm$ 18.48	131.67 $\pm$ 16.99
8	6	72	0.02 $\pm$ 0.01	77.00 $\pm$ 4.87	207.67 $\pm$ 18.37	125.67 $\pm$ 21.99
9	6	96	0.04 $\pm$ 0.01	86.17 $\pm$ 8.99	204.00 $\pm$ 15.45	135.83 $\pm$ 18.57

## DISCUSSION

In light of the information from the current literature, cocklebur extract containing both ATR and CATR substances was thought to cause similar effects (Turgut *et al.*, 2005; Obatomi and Bach, 1998). In a case report published in Turkey, it was reported that death occurred due to CATR intake, and also necrotic changes occurred as a result of toxic findings in the liver and kidneys after the autopsy (Turgut *et al.*, 2005). However, in this reported study, it was CATR toxicity that was mentioned rather than cocklebur poisoning. Furthermore, in the case reported as a CATR poisoning, no findings suggesting the presence of CATR from blood and tissue materials were presented, and the diagnosis was based on anamnesis only. With this study, it was concluded that an investigation of the total toxic effect of the cocklebur plant would be more realistic and useful than the toxicity studies of pure ATR and CATR substances. Because in nature, pure ATR and CATR are mixed with other substances in plants, rather than being isolated (Vignais *et al.*, 1978). Therefore, cocklebur, one of these plants, poses a potential danger in terms of other toxic substances. When the experimental studies and clinical cases are examined, it can be seen that the liver can be affected the most by these toxic compounds. However, besides the liver, there are damages to the kidney and heart due to toxic effects. Also, it was stated that the liver was more sensitive to the toxic effects of these two compounds than the heart, while the kidneys were partially sensitive (Carpenedo *et al.*, 1974). This difference may be due to the tissues having different permeability. Because both inhibitors prevent oxidative phosphorylation in heart mitochondria as well as in liver and kidney mitochondria (Kholodenko *et al.*, 1988; Vignais *et al.*, 1978).

This study investigated the toxic effects of cocklebur extract on kidney and liver tissues containing both substances, with reference to the hepatotoxic and nephrotoxic effects highlighted in experimental ATR and CATR studies (Carpenedo *et al.*, 1974; Wang *et al.*, 2011). Although it was aimed to see results similar to the histopathological findings presented in the reported studies, no histopathological changes were detected in any of the hepatocytes, glomeruli, tubules, or even interstitial tissue in either liver or kidney tissues.

ATR was not found in the blood samples taken at the control group and the first group, in the presented study. In the third group whose blood was taken at the 6<sup>th</sup> h, ATR was first detected in the amount of 0.0328 mg/ml. The amount of ATR, which was 5.1109 mg/ml at the 24<sup>th</sup> h, increased to 7.0922 mg/ml at the 36<sup>th</sup> h and peaked at the 48<sup>th</sup> h to 10.8032 mg/ml. Thus, the orally administered extract was detected at the highest level in the blood at the

48<sup>th</sup> h. ATR decreased to 1.8308 mg/ml at the 72<sup>nd</sup> h in the 8<sup>th</sup> group and to 0.7271 mg/ml at the 96<sup>th</sup> h. This meant that ATR, one of the most important toxic substances in the extract administered to rats reached the highest levels between the 24<sup>th</sup> and 48<sup>th</sup> h, but no death occurred in rats. The probable reason for this is that the toxic substances in the extract administered to rats are not at a level that will kill the animals. Mortality could be achieved in rats by giving a higher dose of extract. However, the stomach of a rat is large enough to take only about 5-6 g of cocklebur fruit powder. Considering the real-life conditions in the experiment, it would be very difficult to give it orally by gavage, and it is not possible for rats to eat this much cocklebur fruit naturally. For this reason, considering that animals may die in the experiment, the maximum amount that the stomach will take was estimated and the level of cocklebur extract (approximately 5 g) to be given was determined. Therefore, the experiment was carried out after the ATR level in the extract was determined as 80 mg/kg. Thus, the experimental animals were prevented from dying from gavage during the experiment, and at the same time, blood samples were taken at different times and when the ATR peak was determined. For this reason, it was concluded that the study will contribute to the determination of the unknown aspects of plant-based toxications that are thought to occur in the future if similar applications are made in real life.

When the poisoning will be observed and when the symptoms will be revealed clearly after this plant is taken orally, are among the subjects that are suitable for research. Here, no ATR was seen in the blood in the first 4 h of the study, and the peak at 48 h and almost 10-fold decrease in its amount at the next 72 h provided very important evidence for the intervention time for treatment. Because, since complete absorption from the gastrointestinal tract has not yet occurred in the 0-12 h period, it can be expected that it will allow physicians to quickly remove poisonous herbs such as orally taken cocklebur from the gastrointestinal tract without being exposed to toxicity. Otherwise, between the 24<sup>th</sup> and 48<sup>th</sup> h, the symptoms of poisoning caused by the toxic plant taken orally will be observed in both humans and animals.

In the study conducted by Stuart *et al.* (1981) oral administration of cocklebur fruit extract to pigs at a rate of 0.066-0.075% of body weight caused death due to acute hepatic necrosis in some of them and did not produce any clinical or pathological findings in the other group administered at the rate of 0.05%. When the plant seed extract administered in this study and the live weights of the rats were compared to each other the rate of 0.02% was obtained.

In another article, extracts of plants synthesizing



some diterpene glycosides (*Xanthium strumarium*, *Callilepis laureola*, *Atractylis gummifera*) and substances such as ATR or CATR were administered orally, rectally, or directly intraperitoneally to humans, rats, pigs, and cattle; Some alterations in blood serums and urine were determined, *Callilepis laureola* plant extract administered orally/rectally in humans has been reported to cause albumin, blood, glucose, ketone bodies and bilirubin in the urine (Bye, 1991; Hu *et al.*, 2000).

In a reported case in Turkey, 9 people of different ages were poisoned because they ate the seeds of the cocklebur plant, and 3 of them (one 5 and two were 9 years old) were reported to die despite the treatment (Turgut *et al.*, 2005). A 25-year-old woman in Iran was admitted to the hospital with symptoms of intoxication 3 days after keeping the mixture consisting of leaves, stems, and seeds of the cocklebur plant in hot water and drinking it, and it was noted that the patient recovered after symptomatic treatment (Saidi and Mofidi, 2009). In another case, it was stated that poisoning occurred in calves that were fed hay containing mature cocklebur, and some poisoned calves died within 12-48 h after the hay was eaten (Witte *et al.*, 1990). Here, the data of the present study overlapped with the 12<sup>th</sup> and 48<sup>th</sup> h when poisoning was observed after feed intake, although some of the calves died, the rats in our experimental groups did not die. In these three studies, it is stated that toxicity occurred between 12 h and 3 days in both humans and animals. It was not reported exactly which toxic substance or substances in the cocklebur plant caused the poisoning (Turgut *et al.*, 2005; Witte *et al.*, 1990; Saidi and Mofidi, 2009). Therefore, effects similar to those in humans were also observed in albino rats given ATR intra-peritoneally (Bye, 1991; Patricia, 1993). However, while calves administered *X. strumarium* orally only had neutropenia in the blood, no findings were observed in pigs. In the same study, in the morphological examination of rats administered ATR, no change was noticed in the external appearance of the heart, liver, and lungs (Bye, 1991; Patricia, 1993). The fact that similar findings were encountered in this study in pathological observations can be interpreted as that this was caused by the administration of pure ATR or CATR in other studies reporting that there was toxicity. Because having high doses of ATR requires consuming very high amounts of seeds or plants that contain poison. This is, however, quite difficult in practice. For this reason, the fact that no changes were observed in the complete blood counts of rats in this study can be explained this way. Again, when the cocklebur plant was taken orally by humans, damages were detected in the liver, kidney, and brain tissues. However, it is not stated here how many milligrams of plant seeds were consumed by humans. The fact that no histopathological findings

were observed in the liver and kidney tissues of rats in the presented study shows that much higher levels of cocklebur plant seeds should be consumed. Also, the fact that no statistically significant difference was observed in the blood serum biochemical values (Ca, P, TBIL, ALT, AST, ALP, UREA, and CREATININ) in all groups in the study (Patricia, 1993; Issi and Gul, 2012), and the values obtained were within the physiological limits are also due to the same reasons. This can be considered as evidence that indicates that much more cocklebur seeds, stalks, or leaves must be consumed for toxicity to occur.

## CONCLUSIONS

*Xanthium strumarium*, which is one of many poisonous plants in the world and in Turkey, is widely found in empty lands. It can cause toxicity in both humans and animals. However, the prevalence and distribution of cocklebur intoxication are not fully known, as poisoning cases have not been recorded. Furthermore, when poisoning cases originating from this plant happen, it is not very clear how many h after the plant is ingested, the toxicity occurs, or what kind of a diagnostic method will be used to reveal it. Therefore, it is extremely important to reveal the exact h of the poisoning. Because after oral intake of the plant 6. having a small amount of ATR in the blood per h can give the clinician permission for emergency intervention to reduce the impact of toxicity. It is important to eliminate this toxic condition by urgently applying adsorbents or laxative drugs etc. With this study, it was determined that even if a rat ate a single dose of cocklebur seed until its stomach was full, no toxicity could occur. This situation can be shown as a source and a clue to similar studies to be done on this subject in the future. Also, since there is no specific antidote to be used in the treatment of cocklebur toxicity, symptomatic treatment should be applied in the cases that occurred. Developing a specific antidote for cocklebur toxicity may also reduce mortality due to plant toxicity.

In addition, no histopathological condition or signs of intoxication were found in the organs of rats administered cocklebur plant fruit extract containing 80 mg/kg ATR orally.

## ACKNOWLEDGMENTS

This study was supported by Bingöl University Scientific Research Projects Unit with project number BAP-VF 2019.00.001. We thank them for their contribution.

### Statement of conflict of interest

The authors have declared no conflict of interest.

## REFERENCES

- Bancroft, J.D., Suvana, S.K., and Layton, C., 2013. *Bancroft theory and practice of histological techniques*. Elsevier Ltd. pp. 73-96. <https://doi.org/10.1016/C2015-0-00143-5>
- BeneSphera-Diagnostic-Hematology: <https://www.scribd.com/doc/211026725/9103-E-Flyer-Diagnostic-Hematology-BeneSphera-3Part-Diff-H32-14vs1-E>.
- Botha, C.J., Lessing, D., Rösemann, M., van Wilpe, E., and Williams, J.H., 2014. Analytical confirmation of *Xanthium strumarium* poisoning in cattle. *J. Vet. Diag. Invest.*, **26**: 640-645. <https://doi.org/10.1177/1040638714542867>
- Bye, S., 1991. *The development of assays for atractyloside and its localisation in rat tissue*. University of Natal. pp. 4-18.
- Carpenedo, F., Luciani, S., Scaravilli, F., Palatini, P., and Santi, R., 1974. Nephrotoxic effect of atractyloside in rats. *Arch. Toxicol.*, **32**: 169-180. <https://doi.org/10.1007/BF00318431>
- Dharmananda, S., 2002. *Safety issues affecting Chinese herbs: The case of Xanthium*. ITM. Available at <http://www.itmonline.org/arts/pas.htm>.
- Fan, W., Fan, L., Peng, C., Zhang, Q., Wang, L., Li, L., Wang, J., Zhang, D., Peng, W. and Wu C., 2019. Traditional uses, botany, phytochemistry, pharmacology, pharmacokinetics and toxicology of *Xanthium strumarium* L. A review. *Molecules*, **24**: 359. <https://doi.org/10.3390/molecules24020359>
- Gaillard, Y., and Pepin, G., 1999. Poisoning by plant material: Review of human cases and analytical determination of main toxins by high-performance liquid chromatography-(tandem) mass spectrometry. *J. Chromatogr. B Biomed. Sci. Appl.*, **733**: 181-229. [https://doi.org/10.1016/S0378-4347\(99\)00181-4](https://doi.org/10.1016/S0378-4347(99)00181-4)
- Hu, F.L., Chen, Y.C., and Cheng, J.T., 2000. Caffeic acid as active principle from the fruit of *Xanthium strumarium* to lower plasma glucose in diabetic rats. *Planta Med.*, **66**: 228-230. <https://doi.org/10.1055/s-2000-8561>
- Ishwarya, S., and Singh, M.K., 2010. Evaluation of antioxidant and *in vitro* cytotoxicity of crude fractions from the roots of *Xanthium strumarium*. *Int. J. Pharm. Tech. Res.*, **2**: 2219-2223.
- İssi, M., and Gül, Y., 2012. Deney Hayvanlarında Kan ve Örnek Alma Teknikleri. Küçük Deney Hayvanlarından Rat. *Cilt 7, Sayı*, **14**: 11-20.
- Kamboj, A., and Saluja, A., 2010. Phytopharmacological review of *Xanthium strumarium* L. (Cocklebur). *Int. J. Green Pharm.*, **22**: 129-139. <https://doi.org/10.4103/0973-8258.69154>
- Kholodenko, B.N., Zilinskiene, V.J., Borutaite, V.J., Ivanoviene, L.J., Toleikis, A.J., and Praskevicius, A.K., 1988. The role of adenine nucleotide translocase in the regulation of oxidative phosphorylation in heart mitochondria. *Biokhimiya*, **53**: 1009-1012.
- Kumar, V., Gundampati, R.K., Singh, D.K., Jagannadham M.V., Sundar, S., and Hasan, S.H., 2016. Photo-induced rapid biosynthesis of silver nanoparticle using aqueous extract of *Xanthium strumarium* and its antibacterial and antileishmanial activity. *J. Ind. Eng. Chem.*, **37**: 224-236. <https://doi.org/10.1016/j.jiec.2016.03.032>
- Laurens, J.B., Bekker, L.C., Steenkamp, V., and Stewart, M.J., 2001. Gas chromatographic-mass spectrometric confirmation of atractyloside in a patient poisoned with *Callilepis laureola*. *J. Chromatogr. B Biomed. Sci. Appl.*, **765**: 127-133. [https://doi.org/10.1016/S0378-4347\(01\)00410-8](https://doi.org/10.1016/S0378-4347(01)00410-8)
- Masvingwe, C., and Mavengwa, M., 1998. Toxicological evaluation of the plant *Xanthium strumarium* in pigs in Zimbabwe. *J. Venom. Anim. Toxins.*, **4**: 113-119. <https://doi.org/10.1590/S0104-79301998000200003>
- Nikles, S., Heuberger, H., Hilsdorf, E., Schmücker, R., Seidenberger, R., and Bauer, R., 2015. Influence of processing on the content of toxic carboxyatractyloside and atractyloside and the microbiological status of *Xanthium sibiricum* fruits. *Planta Med.*, **81**: 1213-1220. <https://doi.org/10.1055/s-0035-1546207>
- Obatomi, D.K., and Bach, P.H., 1998. Biochemistry and toxicology of the diterpenoid glycoside atractyloside. *Fd. Chem. Toxicol.*, **36**: 335-346. [https://doi.org/10.1016/S0278-6915\(98\)00002-7](https://doi.org/10.1016/S0278-6915(98)00002-7)
- Obatomi, D.K., Blackburn, R.O., and Bach, P.H., 2001. Effects of the calcium channel blocker verapamil and sulphhydryl reducing agent dithiothreitol on atractyloside toxicity in precision-cut rat renal cortical and liver slices. *Fd. Chem. Toxicol.*, **39**: 1013-1021. [https://doi.org/10.1016/S0278-6915\(01\)00044-8](https://doi.org/10.1016/S0278-6915(01)00044-8)
- Ozturk, Y., Keskin, Z., Tanyildizi, S., Baykalir, B.G., Korkak, F.A., Hark, B.D. and Dagoglu, G., 2021. Atractyloside levels in xanthium strumarium and atractyloside concentrations in the serum of rats given xanthium strumarium. *Kafkas Univ. Vet. Fak. Derg.*, **27**: 589-594. <https://doi.org/10.9775/kvfd.2021.25921>
- Patricia, L.L., 1993. *Hematology parameters for the*



- CrI:CD®BR Rat, Charles River Laboratories, pp. 1-18.
- Piozzi, F., 1978. Atractyloside: Chemistry, biochemistry and toxicology. In: *The chemistry of atractyloside, RAL* (ed. S. Santi) Piccini, Padova. pp. 13-32.
- Saidi, H., and Mofidi, M., 2009. Toxic effect of *Xanthium strumarium* as an herbal medicine preparation. *EXCLI J.*, **8**: 115-117.
- Sato, Y., Oketani, H., Yamada, T., Singyouchi, K.I., Ohtsubo, T., Kihara, M., Shibata, H. and Higuti, T., 1997. A xanthanolide with potent antibacterial activity against methicillin-resistant *Staphylococcus aureus*. *J. Pharm. Pharmacol.*, **49**: 1042-1044. <https://doi.org/10.1111/j.2042-7158.1997.tb06038.x>
- Schütt, F., Aretz, S., Auffarth, G.U., and Kopitz, J., 2012. Moderately reduced ATP levels promote oxidative stress and debilitate autophagic and phagocytic capacities in human RPE cells. *Invest. Ophthalmol. Vis. Sci.*, **53**: 5354-5361. <https://doi.org/10.1167/iovs.12-9845>
- Sridharamurthy, N.B., 2011. Yogananda R, Srinivas U. In-vitro antioxidant and antilipidemic activities of *Xanthium strumarium* L. *Curr. Trends Biotechnol. Pharm.*, **5**: 1362-1371.
- Stewart, M.J., and Steenkamp, V., 2000. The biochemistry and toxicity of atractyloside: A review. *Therapeut. Drug Monit.*, **22**: 641-649. <https://doi.org/10.1097/00007691-200012000-00001>
- Stuart, B.P., Cole, R.J., and Gosser, H.S., 1981. Cocklebur (*Xanthium strumarium* L. var. *strumarium*) intoxication in swine: Review and redefinition of the toxic principle. *Vet. Pathol.*, **18**: 368-383. <https://doi.org/10.1177/030098588101800310>
- Talakal, T.S., Dwivedi, S.K., and Sharma, S.R., 1995. In vitro and in vivo antitrypanosomal activity of *Xanthium strumarium* leaves. *J. Ethnopharmacol.*, **49**: 141-145. [https://doi.org/10.1016/0378-8741\(95\)01313-X](https://doi.org/10.1016/0378-8741(95)01313-X)
- Turgut, M., Alhan, C.C., Gürgöze, M., Kurt, A., Doğan, Y., Tekatli, M., Akpolat, N. and Aygün, A.D., 2005. Carboxyatractyloside poisoning in humans. *Ann. Trop. Paediatr.*, **25**: 125-134. <https://doi.org/10.1179/146532805X45728>
- Vancompernelle, K., Van Herreweghe, F., Pynaert, G., Van De Craen, M., De Vos, K., Totty, N., Sterling, A., Fiers, W., Vandenabeele, P. and Grooteni, J., 1998. Atractyloside-induced release of cathepsin B, a protease with caspase-processing activity. *FEBS Lett.*, **438**: 150-158. [https://doi.org/10.1016/S0014-5793\(98\)01275-7](https://doi.org/10.1016/S0014-5793(98)01275-7)
- Vignais, P. M., Vignais, P.V., and Defaye, G., 1978. Structure-activity relationship of atractyloside and diterpenoid derivatives on oxidative phosphorylation and adenine nucleotide translocation in mitochondria. In: *Atractyloside: chemistry, biochemistry and toxicology*. Piccin Medical Books, Padova. pp. 39-68.
- Wang, Y., Han, T., Xue, L.M., Han, P., Zhang, Q.Y., Huang, B.K., Zhang, H., Ming, Q.L., Peng, W. and Qin, L.P., 2011. Hepatotoxicity of kaurene glycosides from *Xanthium strumarium* L. fruits in mice. *Pharmazie*, **66**: 445-449.
- Witte, S.T., Mobley, G., and Stahr, H.M., 1990. Cocklebur toxicosis in cattle associated with the consumption of mature *Xanthium strumarium*. *J. Vet. Diagnost. Invest.*, **2**: 263-267. <https://doi.org/10.1177/104063879000200402>
- Xue, L.M., Zhang, Q.Y., Han, P., Jiang, Y.P., Yan, R.Di, Wang, Y., Rahman, K., Jia, M., Han, T. and Qin, L.P., 2014. Hepatotoxic constituents and toxicological mechanism of *Xanthium strumarium* L. fruits. *J. Ethnopharmacol.*, **152**: 272-282. <https://doi.org/10.1016/j.jep.2013.12.024>
- Yan, C., Li, H., Wu, Y., Xie, D., Weng, Z., Cai, B., Liu, X., Li, W. and Chen, Z., 2014. Determination of xanthatin by ultra high performance liquid chromatography coupled with triple quadrupole mass spectrometry: Application to pharmacokinetic study of xanthatin in rat plasma. *J. Chromatogr. B Anal. Technol. Biomed. Life Sci.*, **947-948**: 57-61. <https://doi.org/10.1016/j.jchromb.2013.12.006>
- Yeom, M., Kim, J.H., Min, J.H., Hwang, M.K., Jung, H.S., and Sohn, Y., 2015. Xanthii fructus inhibits inflammatory responses in LPS-stimulated RAW 264.7 macrophages through suppressing NF-κB and JNK/p38 MAPK. *J. Ethnopharmacol.*, **176**: 394-401. <https://doi.org/10.1016/j.jep.2015.11.020>