

Biochemical and Histopathological Effects of Repeated Low Oral Doses of Malathion, Metalaxyl and Cymoxanil on Different Tissues of Rats

Ahmed H. Massoud¹, Mohamed S. Ahmed², Moustafa Saad-Allah¹,
Aly S. Derbalah¹, Ashraf Albrakati^{3*} and Ehab Kotb Elmahallawy^{4*}

¹Pesticides Chemistry and Toxicology Department, Faculty of Agriculture, Kafrelsheikh University 33516 Egypt

²Department of Pathology, Faculty of Veterinary Medicine, Kafrelsheikh University, Kafrelsheikh 33516, Egypt

³Department of Human Anatomy, College of Medicine, Taif University, P.O. Box 11099, Taif 21944, Saudi Arabia

⁴Department of Zoonoses, Faculty of Veterinary Medicine, Sohag University, Sohag 82524, Egypt

ABSTRACT

Most of the pesticides can be used with little risk if label directions were followed, while some are extremely toxic and require special precautions. This study aimed to determine the patho-biochemical toxicity of short-term exposure to repeated low oral doses of malathion, metalaxyl and cymoxanil pesticides on male rats. Results of the present study demonstrated that low doses of malathion, metalaxyl and cymoxanil pesticides was asymptomatic and mostly showed insignificant histopathological changes in treated rats. The observed values of biochemical enzymes with these low-doses were near to the control ones, whereas medium and high doses treated rats exhibited adverse signs and symptoms of toxicity. The results also depicted that cymoxanil was the most toxic of the tested pesticides, followed by Malathion and metalaxyl. The obtained histological lesions were correlated with the increased level of biochemical enzymes in target organs. Additionally, hepatotoxicity and nephrotoxicity were obvious in rats treated with cymoxanil, meanwhile, neuronal and pulmonary changes were nearly the same in all doses of the used pesticides. Taken together, our study recommends examining pesticides for their possible adverse effects on animals and humans in case of repeated use, even in small doses, before their application to agricultural fields.

Article Information

Received 18 May 2021

Revised 25 January 2022

Accepted 01 February 2022

Available online 02 June 2022

(early access)

Published 14 October 2022

Authors' Contribution

AHM and MS Ahmed presented the concept and methodology and performed formal analysis. MS Allah analysed the data and provided statistical guidance. ASD, AA and EKE helped in software, data curation and resources. MS Allah, ASD, AA, EKE AHM and MS Ahmed wrote, reviewed and edited the manuscript.

Key words

Pesticides, Malathion, Metalaxyl, Cymoxanil, Transaminases, ACHE, Creatinine

INTRODUCTION

Pesticides are natural or synthetic compounds used to control plant diseases and pests and they can be classified according their application into herbicides, insecticides and fungicides (Fantke and Juraske, 2013; Sun *et al.*, 2019). Pesticides can cause intoxication through skin contact, ingestion, or inhalation and their risk is to produce harmful effects and even fatality to human (Zuskin *et al.*, 2008). However, great efforts have been spent to produce

pesticides of lower risk to human and animals and of low environmental hazards than the currently used pesticides, it seems difficult to get rid of all pesticides with toxic effects due to its importance in some specific purposes and due to inability to provide safe substitutions (Han *et al.*, 2017). Some pesticides are dangerous after single dose and others can be dangerous after repeated doses (Zuskin *et al.*, 2008; Aardema *et al.*, 2008). Nowadays the emerging problem is the hazards of long-term and low-dose effects of pesticides on human and animals due to its excessive use (Liu *et al.*, 2014). Among others, malathion is the most commonly used pesticide in a vast manner throughout the world to control pests of crops, livestock, ornamentals, stored grain, buildings, households and gardens (Hazarika *et al.*, 2003). Metalaxyl is a systemic, benzenoid fungicide used in mixtures as a foliar spray for wide range of fungal pathogens of fruits and crops by inhibition of mycelial growth and spore formation of these fungi (Urech *et al.*, 1977). In addition, cymoxanil is a broad spectrum and systemic fungicide has a protective and curative effects

* Corresponding author: a.albrakati@tu.edu.sa,
eehaa@unileon.es
0030-9923/2023/0001-11 \$ 9.00/0



Copyright 2023 by the authors. Licensee Zoological Society of Pakistan.

This article is an open access article distributed under the terms and conditions of the Creative Commons Attribution (CC BY) license (<https://creativecommons.org/licenses/by/4.0/>).

against a wide range of fungal diseases in crops (Fazilat *et al.*, 2017). It is noteworthy to state that malathion, metalaxyl and cymoxanil can cause a biochemical and histological alterations on humans and animals (Okdah, 2005). The best ways to determine and evaluate the toxicity of different organophosphorus compounds (OP) are the assessment of biochemical parameters alterations and histopathological changes in tissues and organs (Ghanem *et al.*, 2006). It is well known that, the assessment of blood enzyme activity is more sensitive measure of toxicity and takes shorter time than histopathological examination; meanwhile, the tissue alterations are considered a confirmatory and supporting diagnostic tool (Huang *et al.*, 2019). Given the above information, this study was carried out to study the patho-biochemical toxicity of short-term exposure to repeated low oral doses of malathion, metalaxyl and cymoxanil in male rats.

MATERIALS AND METHODS

Ethical statement

The ethical approval was performed as described by the ethical standards of Veterinary Medicine, Kafrelsheikh University, Egypt, and which complies with all relevant Egyptian legislations.

Chemical

Malathion 99% was applied (Prochem Co. Ltd., Warsaw, Poland), metalaxyl is a colorless, odorless crystal, was provided by Ciba-Geigy Corporation and Cymoxanil tech, off white powder, was provided by Saturn Agrochemical Inc, Shenzhen, Guangdong, China.

Animals

Forty adult male SD rats weighing 100–120 g were obtained from faculty of medicine, Tanta University and acclimatized for one week prior to the experiment. All Rats were housed in polypropylene cages under standard conditions of 12 h light/dark cycle; at $22 \pm 2^\circ$ temperature and 30–70% relative humidity. Rats were well ventilated, standard rat feed and water were provided ad libitum (Korsrud *et al.*, 1972).

Animal treatment

Rats were divided into 9 treated groups and one control group (4 rats in each group). Each 3 treated groups of rats received a diet containing low dose (0.5mg/kg/day), medium dose (1mg/kg/day), and high dose (2mg/kg/day) of Malathion, metalaxyl and cymoxanil respectively dissolved in almond oil for successive 21 days. Control group rats were fed normal diet containing equal amount of almond oil. Clinical signs and mortality of the rats

were observed once per hour for 6 h after dosing and once daily thereafter. The body weights were measured once a week during the whole observation period. All animal studies were approved by our Institutional Animal Ethics Committee.

Histopathological examination

At the end of the study, all the animals were anesthetized and sacrificed. Postmortem examination was performed and lesions were recorded. Specimens from all organs especially liver, brain, kidneys, lungs and testis were taken and kept in 10% neutral buffered formalin for histopathological examination. Specimens were then dehydrated in ascending grades of alcohols, cleared in xylene, embedded in paraffin wax, sectioned at $4\mu\text{m}$, stained with hematoxylin and eosin (HE), and examined by light microscope (Bancroft and Gamble, 2008).

Biochemical determinations

Blood samples were taken shortly before sacrifice, under anesthesia by cardiac puncture, in vials without anticoagulant. Serum was obtained by centrifuging the blood at 3000 rpm for 5 min and kept at -20°C until be used. Liver, brain and kidneys of both treated and control rats were quickly separated on ice cold 0.8 M sucrose containing 1mM phenyl methane sulphonyl fluoride (PMSF) using Micra D-1-high speed tissue homogenizer to make 10% homogenate (w/v). The homogenate was then centrifuged at $10\,000\times g$ for 10 min at 4°C . The supernatant was used as enzyme source. Aspartate aminotransferase (AST), Alanine aminotransferase (ALT), alkaline phosphatase (ALP) and Creatinine were determined from the serum and supernatant of the homogenate of liver and kidneys as mentioned elsewhere (Reitman and Frankel, 1957; Barham and Trinder, 1972). The activity of Acetylcholinesterase (AChE) was determined according to the method described (Ellman *et al.*, 1961; Rahman *et al.*, 2000).

Statistical analysis

The statistical analysis of the treatment was performed by one-way ANOVA using SPSS statistical software package for windows version 11.0. Duncan's multiple-range test was used to find out the group effects. $P \leq 0.05$ was set as limit of significance.

RESULTS

Clinical signs and postmortem examination

There was no significant difference in daily activity, clinical observation, body weight and water and food consumption between the treated groups with (low,

medium and high) of Malathion, low and medium dose of both metalaxyl and cymoxanil and the respective control groups. However, shortly before the end of the experiment, rats treated with high dose of metalaxyl exhibited transient hypo-activity and rats treated with high dose of cymoxanil showed lethargy, dullness, incoordination, reduced body weight and feed intake, but the loss of weight was not significant. No deaths occurred throughout the study period in the treated groups. Furthermore, no macroscopic visible changes were found in organs of treated rats during postmortem examination.

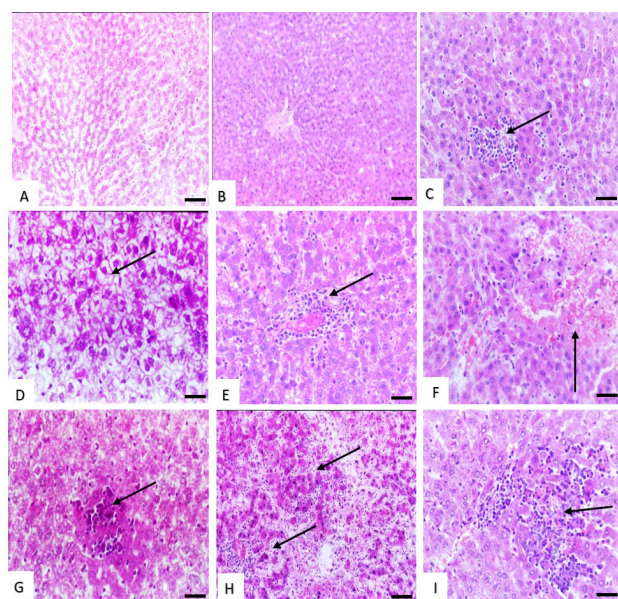


Fig. 1. Histological structure of rat liver (A and B) Effect of low dose of malathion and metalaxyl showing, slight congestion and dilation of the hepatic sinusoids. (C) Effect of low dose of cymoxanil showing slight sinusoidal cell activation with pregranuloma formation (arrow). (D) Effect of medium dose of malathion showing marked cytosolic hydrops with vacuolated cytoplasm of the hepatocytes (arrow). (E) Effect of medium dose of metalaxyl showing perivascular focal collection of mononuclear cells (arrow). (F) Effect of medium dose of cymoxanil showing haemorrhages in the hepatic parenchyma (arrow). (G and H) Effect of high dose of malathion, metalaxyl and cymoxanil showing hepatocellular necrosis (arrows). Stain: H and E. Magnification bar: 50 μ m.

Histopathological changes in the liver

Rats treated with low dose of Malathion and metalaxyl showed slight congestion and dilatation of the hepatic sinusoids which were similar to that found in the control rats (Fig. 1A, B). Meanwhile, those rats treated with low dose of cymoxanil showed slight sinusoidal cell activation with pregranuloma formation (Fig. 1C). Liver

of rats treated with medium dose of malathion showed marked cytosolic hydrops with vacuolated cytoplasm of the hepatocytes (Fig. 1D), while liver of rats treated with medium dose of metalaxyl showed moderate inflammatory reaction in the form of focal collection of mononuclear cells within the hepatic parenchyma and in the portal triad (Fig. 1E). Moreover, some areas of the hepatic lobules appeared with slight fatty changes and apoptosis, but rats treated with medium dose of cymoxanil showed focal hepatocytic necrosis with moderate infiltration of mononuclear cells and haemorrhages in the hepatic parenchyma (Fig. 1F). On the other hand, rats treated with high doses of malathion showed granuloma like reaction with focal collection of kupffer cells and focal hepatocellular coagulative necrosis (Fig. 1G); meanwhile liver of rats treated with high dose of metalaxyl and cymoxanil showed extensive piecemeal necrosis and the hepatocytes were lost their normal architecture with infiltration of mononuclear cells in the margin and within the necrosed areas (Fig. 1H, I).

The histopathological changes in the brain

There were no obvious changes recorded in the brain of rats treated with malathion and metalaxyl at low dose (Fig. 2A, B), but rats treated with low dose of cymoxanil showed slight lymphocytic perivascular infiltration (perivascular cuff) (Fig. 2C). Rats treated with medium dose of malathion showed neuronal cell degeneration and few hemorrhagic areas in the brain tissue (Fig. 2D), while rats received medium dose of metalaxyl exhibited slight spongiosis (Fig. 2E) and slight spongiosis and scattered focal collections of glial cells forming Babe's bodies was observed in rats treated with medium dose of cymoxanil (Fig. 2F). Brain lesions became more pronounced in the rats treated with high dose of all three pesticides, represented by moderate perivascular edema, cerebral hemorrhages and features of focal early malacia in the cerebral cortex in malathion treated rats (Fig. 2G). Obvious cerebral spongiosis and gliosis was reported in rats treated with metalaxyl (Fig. 2H) and cerebral liquifactive necrosis (malacia) with newly formed blood capillaries in rats treated with cymoxanil (Fig. 2I).

The histopathological changes in the kidneys

Rats treated with malathion and metalaxyl in low dose did not show any changes which is similar to that of the control rats (Fig. 3A, B), meanwhile, those treated with low dose of cymoxanil showed slight interstitial nephritis with intertubular infiltration of mononuclear cells (Fig. 3C). Kidneys of rats treated with medium dose of malathion and metalaxyl showed slight vacuolar degenerative changes in the renal tubules lining epithelium (Fig. 3D, E), but rats treated with medium dose of cymoxanil exhibited slight interstitial nephritis with intertubular infiltration

of mononuclear cells (Fig. 3F). More severe changes were observed in the kidneys of all groups, marked interstitial nephritis and plugging of renal tubules lumens with proteinaceous casts in malathion treated rats (Fig. 3G), cloudy swelling degeneration was observed in the epithelial lining of the renal tubules forming star shape like lumens in metalaxyl treated rats (Fig. 3H). Meanwhile, rats treated with high dose of cymoxanil showed marked renal changes in the form of severe interstitial nephritis and thickening and sclerosis of the Bowman's capsule and the surrounding renal tubules (Fig. 3I).

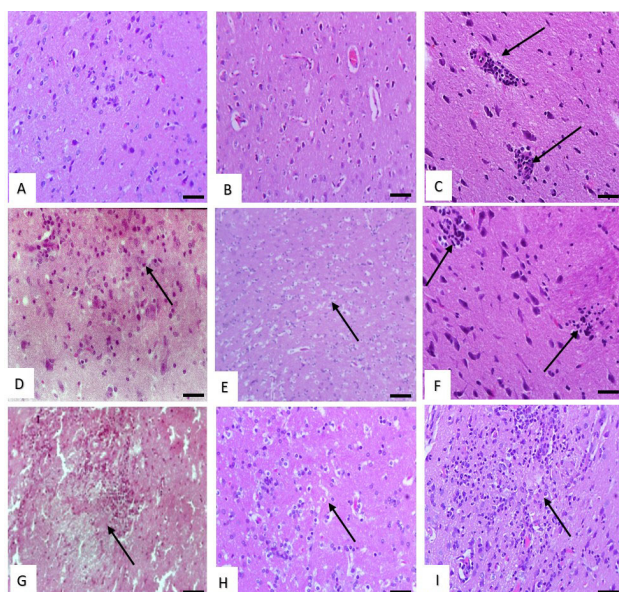


Fig. 2. Histological structure of rat brain. (A and B) Effect of low dose of malathion and metalaxyl showing normal structure. (C) Effect of low dose of cymoxanil showing slight perivascular lymphocytes infiltration (arrows). (D) Effect of with medium dose of malathion showing neuronal cell degeneration (arrow). (E) Effect of medium dose of metalaxyl showing slight spongiosis (arrow). (F) Effect of medium dose of cymoxanil showing focal collections of glial cells forming Babe's bodies (arrows). (G) Effect of high dose of malathion showing focal cerebral malacia (arrow). (H) Effect of high dose of metalaxyl showing cerebral spongiosis and gliosis (arrow). (I) Effect of high dose of cymoxanil showing cerebral liquifactive necrosis (malacia) (arrow). Stain: H and E. Magnification bar: 50 μ m.

The histopathological changes in the lungs

There were no microscopic changes observed in the lungs of rats treated with malathion and metalaxyl at low dose level and lungs showing the same architecture which is similar to that of control ones (Fig. 4A, B), but rats treated with low dose of cymoxanil showed slight perivascular mononuclear cells infiltration (Fig. 4C). On the other

hands, rats treated with malathion medium dose lungs showed interstitial pneumonia with marked thickening in the interalveolar septa (Fig. 4D), while those treated with medium dose of metalaxyl and cymoxanil exhibited slight interstitial pneumonia (Fig. 4E) and moderate interstitial pneumonia (Fig. 4F), respectively. In addition, there were marked bronchopneumonia with massive peribronchial infiltration of mononuclear cells (Fig. 4G) in rats treated with high dose of the three chemicals. Furthermore, light interstitial pneumonia (Fig. 4H) was observed in rats treated with high dose of malathion, while those treated with high dose of metalaxyl and cymoxanil exhibited marked interstitial pneumonia with pneumocyte type II hyperplasia (Fig. 4I).

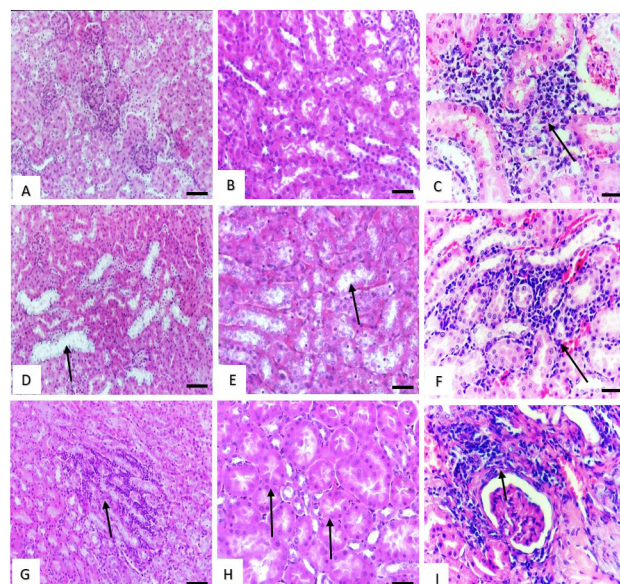


Fig. 3. Histological structure of rat kidney. (A and B) Effect of low dose of malathion and metalaxyl showing normal structure. (C) Effect of low dose of cymoxanil showing, slight interstitial mononuclear cells infiltration (arrow). (D and E) Effect of medium dose of malathion and metalaxyl showing slight vacuolar degenerative changes in the renal tubules lining epithelium (arrows). (F) Effect of medium dose of cymoxanil showing slight interstitial nephritis (arrow). (G) Effect of high dose of malathion showing marked interstitial nephritis (arrow). (H) Effect of high dose of metalaxyl showing cloudy swelling in the epithelial lining of the renal tubules (arrows). Stain: H and E. Magnification bar: 50 μ m.

The histopathological changes in the testis

No pathological changes were detected in seminiferous tubules and interstitial tissue in rats treated with low dose of malathion, cymoxanil and to low, medium, high dose of metalaxyl. The seminiferous tubules

appeared uniform in size and shape and they were lined by arranged rows of spermatogenic cells in different stages of maturation. Spermatogenic cells and sertoli cells in the seminiferous tubules were observed in normal structure. Leydig cells and blood vessels were found in the interstitial connective tissue between the tubules (Fig. 5A). Rats treated with medium dose of malathion and cymoxanil showed decrease in the number of spermatogenic cells in the seminiferous tubules (Fig. 5B) and interstitial edema (Fig. 5C), respectively. Meanwhile, rats treated with high dose of malathion revealed marked vacuolation in the cytoplasm of sertoli cells (Fig. 5D) and those rats treated with high dose of cymoxanil showed massive necrosis in the lining epithelium of seminiferous tubules with marked interstitial oedema (Fig. 5E).

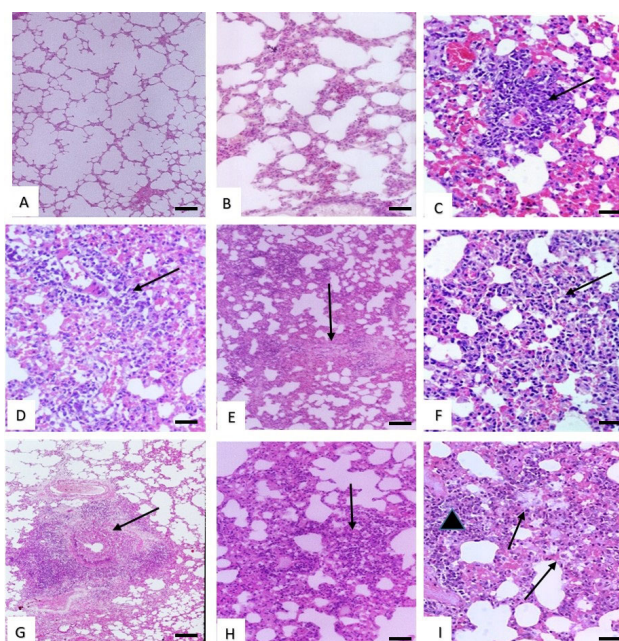


Fig. 4. Histological structure of rat lung. (A and B) Effect of low dose of malathion and metalaxyl showing normal structure. (C) Effect of low dose of cymoxanil showing slight interstitial mononuclear cells infiltration (arrow). (D) Effect of medium dose of malathion showing marked thickening in the interalveolar septa (arrow). (E) Effect of medium dose of metalaxyl showing slight interstitial pneumonia (arrow). (F) Effect of high dose of malathion showing more marked interstitial nephritis (arrow). (G) Effect of high dose of malathion showing, massive peribronchial infiltration of mononuclear cells (arrow). (H) Effect of with high dose of metalaxyl showing slight interstitial pneumonia (arrow). (I) Effect of high dose of cymoxanil showing marked interstitial mononuclear cells infiltration (triangle) and pneumocyte type II hyperplasia (arrows). Stain: H and E. Magnification bar: 50 μ m.

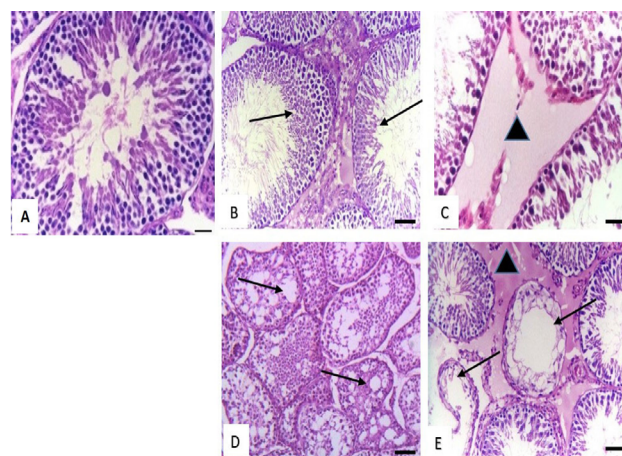


Fig. 5. Histological structure of rat testis. (A) Effect of low dose of malathion, (low, medium, high) dose of metalaxyl and low dose of cymoxanil showing normal structure. (B) Effect of medium dose of malathion showing decrease in the number of spermatogenic cells in the seminiferous tubules (arrows). (C) Effect of medium dose of cymoxanil showing interstitial oedema (triangle). (D) Effect of high dose of malathion showing necrosis of spermatogenic layers and marked vacuolation in the cytoplasm of sertoli cells (arrows). (E) Effect of high dose of cymoxanil showing, massive necrosis in the lining epithelium of seminiferous tubules (arrows) with marked interstitial oedema (triangle). Stain: H and E. Magnification bar: 50 μ m.

Effects on liver function

The obtained data showed that treated rats with malathion at low and medium dose and metalaxyl at low dose group did not show any changes in the AST, ALT and ALP activity which is similar to that of control ones. The activity was slightly increased in rat groups treated with high dose of malathion, medium dose of metalaxyl and low dose of cymoxanil. Rats treated with high dose of metalaxyl and medium dose of cymoxanil showed higher activity of liver enzymes and the activity was markedly increased in those rats treated with high dose of cymoxanil (Table I).

Effect on brain function

Low dose of malathion and cymoxanil slightly decreased the ACHE activity but nearly the same like control rats. However, low dose of cymoxanil showed more decrease in ACHE activity. The three chemicals showed medium decrease in the activity at medium dose level, but higher doses of malathion and metalaxyl exhibited slightly decrease but cymoxanil showed sharp decrease in the activity of ACHE (Table I).

Table I. Biochemical changes in male rats treated with repeated low oral doses of malathion, metalaxyl and cymoxanil pesticides.

Parameter	Control	0.5 mg/kg/day			1 mg/kg/day			2 mg/kg/day		
		Malathion	Metalaxyl	Cymoxanil	Malathion	Metalaxyl	Cymoxanil	Malathion	Metalaxyl	Cymoxanil
AST (U/ml)	13.44±0.59 ^d	13.58±1.15 ^c	13.91±0.98 ^c	17.36±0.92 ^c	13.98±1.39 ^b	16.34±0.92 ^b	18.25±1.60 ^b	14.98±0.89 ^a	18.06±1.15 ^a	25.51±1.46 ^a
ALT (U/ml)	17.76±0.46 ^d	17.66±1.52 ^c	16.68±1.39 ^d	23.96±1.76 ^c	17.97±1.01 ^b	20.21±0.99 ^b	22.75±1.98 ^b	21.39±1.82 ^a	24.74±1.61 ^a	33.28±1.02 ^a
ALP (U/100ml)	2.79±0.70 ^d	2.89±0.66 ^b	3.16±0.65 ^b	4.15±0.48 ^c	3.16±0.14 ^a	3.16±0.67 ^b	4.54±0.83 ^b	3.17±0.01 ^a	4.51±0.54 ^a	5.36±0.50 ^a
ACHE	0.95×10 ⁻⁴ ±0.05 ^a	0.87×10 ⁻⁴ ±0.01 ^b	0.72×10 ⁻⁴ ±0.06 ^b	0.88×10 ⁻⁴ ±0.01 ^a	0.75×10 ⁻⁴ ±0.01 ^a	0.75×10 ⁻⁴ ±0.03 ^b	0.75×10 ⁻⁴ ±0.04 ^b	0.67×10 ⁻⁴ ±0.02 ^a	0.65×10 ⁻⁴ ±0.04 ^c	0.37×10 ⁻⁴ ±0.07 ^c
Creatinine (Mg/di)	0.32±0.021 ^c	0.34±0.020 ^b	0.27±0.006 ^b	0.77±0.009 ^b	0.35±0.013 ^b	0.27±0.025 ^b	0.78±0.016 ^b	0.45±0.019 ^a	0.35±0.021 ^a	0.95±0.016 ^a

All data was expressed as mean ± S.D (number of replicates=3). Means within the same column (in each parameter) carrying different superscripts (a, b, c, d) is significantly different ($p < 0.05$).

Effects on kidneys function

Creatinine level was similar to that of control in rats treated with low dose malathion and low and medium dose of metalaxyl. On the other hand, the level of creatinine increased in rats treated with low dose of cymoxanil, medium dose of malathion and high dose of metalaxyl. The creatinine level was severely increased in rats treated with high dose of malathion and cymoxanil (Table I).

DISCUSSION

Investigation the adverse effects of chemical pollutants and pesticides are considered one of major concern for human health. The present study provides interesting data in relation to the patho-biochemical toxic effects of the repeated low oral doses of Malathion, Metalaxyl and Cymoxanil Pesticides on male rats. In the present study, no treatment-related differences or clinical signs were found between treated rats with malathion in all doses, metalaxyl and cymoxanil at low and medium doses and controls during the study period. It seems that the used doses gave an indication about the no observed effect level (NOEL) as the rats were asymptomatic. However, appearance of clinical signs of toxicity at the end of the experiment in the high dose treated rats with metalaxyl and cymoxanil is an interesting finding that reflects the changes in enzyme activities occurred after accumulation of large amount of the toxicants which resulted in stress condition of these chemicals on rats, which is in agreement with several previous studies (Rahman *et al.*, 2000; Awal and Malik, 1992). No deaths occurred throughout the study period in the all treated rat groups and no treatment-related gross changes in organs were seen at necropsy.

In accordance with the histopathological changes, the present study revealed that liver appeared normal in lobulation and arrangement of hepatic cords in rats treated

with low dose of malathion and metalaxyl. Inflammatory reaction in the liver parenchyma and portal triad, fatty changes and hepatic necrosis were observed in rats treated with high doses of the three studied chemicals, indicating dose dependent toxicity, which is correlated with the increased level of liver enzymes that rendered to subchronic liver damage. These results are in agreement with some previous reports (Sayim, 2007; Kim *et al.*, 2008; Singh *et al.*, 2013; Toś-Luty *et al.*, 2003), who found that exposing male Wistar rats to a single dose of malathion, caused degenerative changes in the liver in the form of parenchymatous degeneration. In addition, a previous study noticed congestion of blood vessels, increased in number of Kupffer cells, cellular infiltration and hydropic degeneration in liver of male rats treated with metalaxyl (Okdah, 2005). We assumed that these lesions may arise from the toxic effect of the high doses of these chemicals, which disturbs the detoxification mechanisms of the liver and induces an inflammatory response comparable with the dose of the all three compounds dosed (Gokcimen *et al.*, 2007; Lee *et al.*, 2016; Yehia *et al.*, 2007). It is well known that; liver is the primary organ concerned with detoxification in the body that acts through p450 mediated enzymatic catalysis. Clearly, it seems that cymoxanil, like several other pesticides, adversely affects the cytochrome P450 system or the mitochondrial membrane transport system of hepatocytes that induced liver damage and cell death in the treated rats with high dose of malathion, metalaxyl and cymoxanil. This led to inhibition of the p450-mediated biocatalysis which is in agreement with some previous reports (Gokcimen *et al.*, 2007; Guengerich and Avadhani, 2018; He *et al.*, 2020). We suggest that the high dose of the used chemicals led to reduction in antioxidant enzymes activities resulted in oxidative damage of the liver tissue, particularly in rats treated with metalaxyl (Nakatani *et al.*, 2000).

Brain is a highly susceptible organ for toxicity, because it contains relatively low levels of the anti-oxidative stress enzymes and in part because of its high myelin-associated contents, making it vulnerable to the propagation of peroxidative process (Savolainen, 1978). As depicted in our results, brain showed no histopathological changes in groups of rats treated with low dose of malathion and metalaxyl which is similar to brain of control group. Histopathological changes became more severe in other treated groups with medium and high dose of malathion and metalaxyl and in all groups treated with cymoxanil. The noticed changes indicated that the brain damage was nearly dose dependent in the rats treated with all the toxic materials. In the present study, the low dose exposed rats were mostly asymptomatic, but medium and high dose treated rats exhibited signs and symptoms of toxicity (Cheng *et al.*, 2020). Many pesticides cause neurotoxicity and they kill insects by targeting their nervous system besides reported neurotoxic effect in mammals (Ahmed *et al.*, 2020). It seems that the used pesticides interfere with chemical neurotransmission or ion channels, and cause reversible neurotoxic effects such as neuritis and gliosis, which is consistent with several previous reports (Eddleston *et al.*, 2002; Gunnell *et al.*, 2007). The noticed spongiosis could be attributed to the loss or damage of myelin sheath which is a substance encloses nerves and formed from fats and proteins that helps in transmitting signals along the nerves (Lotti and Johnson, 1978; Stacey *et al.*, 2004).

To author's knowledge, renal clearance of chemicals through glomerular filtration is time-dependent and it depends on their physiochemical properties. In this concern, particles of 7 nm or above usually cannot pass through the glomerular endothelial cells, and hence are not cleared (Iavicoli *et al.*, 2016). In the present study, the effect of all used pesticides on the kidneys of all treated groups was dose dependent. Kidneys of rats treated with low dose did not show any microscopic abnormalities and medium dose treated rats exhibited slight microscopic changes. However, marked renal changes were recorded in rats treated with high dose of malathion, metalaxyl and cymoxanil, respectively. These induced histopathological changes were in consistence with that reported elsewhere (Afshar *et al.*, 2008; Mamun *et al.*, 2015). We think that high doses of the used chemicals resulted in large size metabolites which could not pass-through glomerular filtration, then accumulate in the glomerular tufts and peritubular renal capillaries, causing chronic toxicity in kidney including, necrosis of the epithelial lining of the renal tubules and severe interstitial nephritis with thickening and sclerosis of the Bowman's capsule and the surrounding renal tubules (Yun *et al.*, 2015; Iavicoli *et al.*, 2016). All these lesions

were confined mainly in the renal cortex, as the proximal tubules are the main site for xenobiotic biotransformation, and therefore it is susceptible to chemical insult (Lock and Reed, 1998). In accordance with the histopathological changes in lungs, treatment with three chemicals was not toxic at low dose. On the other hand, metalaxyl showed slight pulmonary changes in the rats treated with medium and high dose, meanwhile malathion and cymoxanil resulted in more severe pulmonary changes in the groups treated with medium and high doses. Few studies revealed the respiratory effects of workers involved with pesticides, even though some pesticides may result in impairment of pulmonary function, development of chronic bronchitis, as well as impaired respiratory muscle function (Zuskin *et al.*, 2008). The obtained pulmonary lesions might be attributed to the breakdown of the alveolar epithelial/endothelial barrier and the exudative inflammatory infiltrate into the lungs, which is in harmony with several previous reports (Hussain and Sultan, 2005). Adamis *et al.* (1999) mentioned that the pathophysiological processes leading to these inflammatory reactions remain unclear. Little is known about male reproductive damage caused by the used pesticides. Clearly, analysis of the male reproductive function after exposure to malathion, metalaxyl and cymoxanil of great importance (Bustos-Obregón, 2001; Bustos-Obregón *et al.*, 2007). In the present study, rats treated with metalaxyl at all doses, malathion and cymoxanil at low dose showed the same histologic structure like that of control group, which is consistent with a previous study (Recena *et al.*, 2006), suggested that metalaxyl is unlikely to cause reproductive effects. Meanwhile, rats treated with medium and high dose of malathion and cymoxanil showed dose dependent testicular changes. We assume that malathion affects germinal and somatic cells of the testis and decreases the testosterone activity, consequently, inhibited spermatogenesis through damage and vacuolation of Sertoli cells and germ cells (Steger *et al.*, 1999; Farag *et al.*, 2000; Mahgoub and El-Medany, 2001). Cymoxanil in high doses may resulted in inhibition of spermatogenesis in rats (Farag *et al.*, 2000; Uzunhisarcikli *et al.*, 2007; Khan *et al.*, 2001).

The biochemical enzymatic variations are powerful predictive tool in assessment of toxicity (Kumari *et al.*, 2012). Among others, liver is often a primary target organ for the toxic effect of xenobiotics. Therefore, it can be used as an index of toxicity of various toxicants. Transaminases and phosphatases are important critical enzymes in biological processes and are considered specific biochemical indicators of the liver damage (Gokcimen *et al.*, 2007; Banacee *et al.*, 2011). AST and ALT enzymes are important to metabolism of cellular nitrogen, liver glucose and oxidation of amino acids (Celik *et al.*, 2009). Alkaline

phosphatase plays an integral role in glycogen metabolism in the liver through stimulation of glucose synthesis to overcome energy required during stress conditions (Sayim, 2007; Fazilat *et al.*, 2017). As shown in our results, low doses of the used chemicals and medium doses of malathion and metalaxyl did not disturb the liver function as the liver enzymes were within the normal limits with the exception of low dose of cymoxanil that showed slight increase of their activities. Meanwhile; higher doses of the used chemicals as well as the medium dose of cymoxanil showed elevation of AST, ALT and ALP level which means damage of the cell membrane of hepatocyte and as consequence leak of their cytosolic enzymes into blood. Elevation of ALT activity appears to reflect hepatic disease more specifically than AST values. The activity of either enzyme, particularly AST, may be elevated also in extra-hepatic disease. However, the elevation of AST and ALT, along with the elevation of ALP activities, may reflect some necro-inflammatory disease of the liver (Morowati, 1997; Kaya *et al.*, 2015; Agrahari *et al.*, 2007).

It should be stressed that Acetylcholine esterase is a neurotransmitter responsible for the hydrolysis of acetylcholine to choline at the synapses and the neuromuscular junction and has been considered as an excellent enzymatic marker for altering brain neural function (Cheng *et al.*, 2020; Kumari *et al.*, 2012). In the present study, all used chemicals showed dose dependent decreased activity of AChE which was more obvious with cymoxanil. We assume that, the interaction of the used chemicals with AChE causing alterations in the cell membrane permeability and inducing inhibition. These results are consistent with findings of many researchers who reported that the most prominent clinical effects of poisoning with organophosphorus compounds are related to their inhibition of the activity of blood cholinesterase, leading to the accumulation of acetylcholine at cholinergic synapses which causes constant acetylcholine receptor triggering, resulting in consequent signs of neurotoxicity (Timur *et al.*, 2003; Hazarika *et al.*, 2003). The kidneys possess most of the common xenobiotic metabolizing enzymes, and is thus able to make an important contribution to the body's metabolism of drugs and foreign compounds (Lock and Reed, 1998). Creatinine is a byproduct of skeletal muscle metabolism of creatine, and cleared from the blood plasma in the kidney at an approximately constant rate, primarily by filtration through the glomerulus (Mage *et al.*, 2004). According to the present results, low doses of the all chemicals used in our study and medium doses of malathion and metalaxyl did not show any increase in the creatinine level more than that of the control group. Meanwhile; higher doses of the malathion, cymoxanil and metalaxyl as well as the medium dose of cymoxanil showed

elevation of the creatinine level, indicating the impairment of the glomerular function and tubular damage in the kidneys and accumulation of creatinine in the bloodstream (Lock and Reed, 1998; Eddleston *et al.*, 2002).

CONCLUSION

Give the above information, this study demonstrated that 21 daily repeated low dose of malathion, metalaxyl and cymoxanil pesticides was asymptomatic and target biochemical enzymes and the observed values were near to the control ones. In addition, histopathological changes in various tissues of treated rats were mostly insignificant with these low doses. In stark contrast, high dose treated rats exhibited adverse signs and symptoms of toxicity. Cymoxanil was highly toxic in all used doses than those of malathion and metalaxyl. Metalaxyl has no effect on reproductive organs while medium and high doses of malathion and cymoxanil resulted in testicular degeneration and inhibited spermatogenesis. We assumed that, reported tissue necrosis in different organs of the high dose treated rats resulted in defects in cell membrane permeability, consequently, changes in biochemical enzymes of these tissues which are good biomarkers for studies of toxic tissue injury. The recorded toxicity of the used compounds at these low concentration levels could urge the governments for more restrictive regulations to investigate the effects of carcinogenesis for each pesticide to be safe for specific applications.

ACKNOWLEDGEMENT

This work was supported by grants from the Taif University Researchers Supporting Program (project number: TURSP-2020/151), Taif University, Saudi Arabia.

Statement of conflict of interest

The authors have declared no conflict of interest.

REFERENCES

- Aardema, H., Meertens, J.H., Ligtenberg, J.J., Peters-Polman, O.M., Tulleken, J.E. and Zijlstra, J.G., 2008. Organophosphorus pesticide poisoning: Cases and developments. *Neth. J. Med.*, **66**: 149-153.
- Adamis, Z., Tatray, E., Honma, K. and Ungvary, G., 1999. Effects of lead (II) nitrate and a dithiocarbamate fungicide on the rat lung. *J. appl. Toxicol.*, **19**: 347-350. [https://doi.org/10.1002/\(SICI\)1099-1263\(199909/10\)19:5<347::AID-JAT587>3.0.CO;2-3](https://doi.org/10.1002/(SICI)1099-1263(199909/10)19:5<347::AID-JAT587>3.0.CO;2-3)

- Afshar, S., Farshid, A.A., Heidari, R. and Ilkhanipour, M., 2008. Histopathological changes in the liver and kidney tissues of Wistar albino rat exposed to fenitrothion. *Toxicol. Ind. Hlth.*, **24**: 581-586. <https://doi.org/10.1177/0748233708100090>
- Agrahari, S., Kashev, C.P. and Krishna, G., 2007. Biochemical alteration induced by monocrotophos in the blood plasma of fish, *Channa punctatus* (Bloch). *Pestic. Biochem. Physiol.*, **88**: 268-272. <https://doi.org/10.1016/j.pestbp.2007.01.001>
- Ahmed, M.S., Ahmed, H.M., Aly, S.D. and Ahmed, A.I., 2020. Pathological and biochemical assesment of the fungicide (Metalaxyl) on rats. *Animals (Basel)*, **10**: 2205.
- Awal, M.A. and Malik, J.K., 1992. Effects of daily phosphamidon administration on certain blood biochemical measurements in *Bubalus bubalis*. *Bull. environ. Contamin. Toxicol.*, **48**: 709-714. <https://doi.org/10.1007/BF00195991>
- Banaee, M., Antoni, S., Ali, R.M. and Golam, R.R., 2011. Effects of long-term silymarin oral supplementation on the blood biochemical profile of rainbow trout (*Oncorhynchus mykiss*). *Fish Physiol. Biochem.*, **37**: 885-896. <https://doi.org/10.1007/s10695-011-9486-z>
- Bancroft, J.D. and Gamble, M., 2008. *Theory and practice of histological techniques*. 6th Edition, Churchill Livingstone, Elsevier, London.
- Barham, D. and Trinder, P., 1972. A colorimetric methods for the determination of creatinine in serum. *Analyst*, **97**: 142-145. <https://doi.org/10.1039/an9729700142>
- Bustos-Obregón, E., Fernando, C.D.R. and Luis, S., 2007. Morphometric analysis of mice testicular tubules after administration of malathion and maca. *Int. J. Morphol.*, **25**: 245-248. <https://doi.org/10.4067/S0717-95022007000200001>
- Bustos-Obregón, E., 2001. Adverse effects of exposure to agropesticides on male reproduction. *Acta Pathol. Microbiol. Immunol. Scand.*, **109**: S233-S42. <https://doi.org/10.1111/j.1600-0463.2001.tb05772.x>
- Celik, I., Zeycan, Y. and Vedat, T., 2009. Hematotoxic and hepatotoxic effects of dichlorvos at sublethal dosages in rats. *Environ. Toxicol. Int. J.*, **24**: 128-132. <https://doi.org/10.1002/tox.20390>
- Cheng, B., Hua, Z., Jihuan, H., Yuyang, P., Jian, Y., Xinjun, L., Fasheng, L., Jun, G., Chengyu, H. and Huiqiang, L., 2020. The immunotoxicity and neurobehavioral toxicity of zebrafish induced by famoxadone-cymoxanil. *Chemosphere*, **247**: 125870. <https://doi.org/10.1016/j.chemosphere.2020.125870>
- Eddleston, M., Ladislaus, S., Peter, E. and Nick, B., 2002. Oximes in acute organophosphorus pesticide poisoning: a systematic review of clinical trials. *Quart. J. Med.*, **95**: 275-283. <https://doi.org/10.1093/qjmed/95.5.275>
- Ellman, G.L., Diane, K.C., Valentino, A.J. and Robert, M.F., 1961. A new and rapid colorimetric determination of acetylcholinesterase activity. *Biochem. Pharmacol.*, **7**: 88-95. [https://doi.org/10.1016/0006-2952\(61\)90145-9](https://doi.org/10.1016/0006-2952(61)90145-9)
- Fantke, P. and Ronnie, J., 2013. Variability of pesticide dissipation half-lives in plants. *Environ. Sci. Technol.*, **47**: 3548-3562. <https://doi.org/10.1021/es303525x>
- Farag, A.T., Eweidah, M.H. and El-Okazy, A.M., 2000. Reproductive toxicology of acephate in male mice. *Reprod. Toxicol.*, **14**: 457-462. [https://doi.org/10.1016/S0890-6238\(00\)00094-0](https://doi.org/10.1016/S0890-6238(00)00094-0)
- Fazilat, N., Arya, V., Mahdi, B. and Ahmad, F., 2017. Separate and combined effects of dimethoate pesticide and bio-fertilizer on the activity of enzymes involved in anaerobic pathway, neurotransmission and protein metabolism in common carp, *Cyprinus carpio* (Teleostei: Cyprinidae). *Iran. J. Ichthyol.*, **4**: 352-360.
- FAO, 1983. *Food, Nations Agriculture Organization of the United, Organization World Health, F.A.O. Panel of Experts on Pesticide Residues in Food, Environment the, and W.H.O. Expert Group on Pesticide Residues 1983*. Pesticide residues in food: 1982 evaluations, the monographs, data and recommendations of the joint meeting of the FAO Panel of Experts on Pesticide Residues in Food and the Environment and the WHO Expert Group on Pesticide Residues, Rome, 23 November - 2 December 1982.
- Ghanem, N.F., Hassan, N.A. and Ismail, A.A., 2006. *Biochemical and histopathological changes induced in rats fed on diets and byproducts of fumigated wheat grains with phostoxin*. Proceedings of 4th International Conference Biology Science Zoology, pp. 259-268.
- Gokcimen, A., Kanat, G., Hilmi, D., Dilek, B., Ahmet, K. and Irfan, A., 2007. Effects of diazinon at different doses on rat liver and pancreas tissues. *Pestic. Biochem. Physiol.*, **87**: 103-108. <https://doi.org/10.1016/j.pestbp.2006.06.011>
- Guengerich, F.P. and Narayan, G.A., 2018. *Roles of cytochrome P450 in metabolism of ethanol and carcinogens*. Alcohol Cancer (Springer).
- Gunnell, D., Fernando, R., Hewagama, M., Priyangika, W.D., Konradsen, F. and Eddleston, M., 2007. The

- impact of pesticide regulations on suicide in Sri Lanka. *Int. J. Epidemiol.*, **36**: 1235-1242. <https://doi.org/10.1093/ije/dym164>
- Han, Y., Mo, R., Yuan, X., Zhong, D., Tang, F., Ye, C. and Liu, Y., 2017. Pesticide residues in nut-planted soils of China and their relationship between nut/soil. *Chemosphere*, **180**: 42-47. <https://doi.org/10.1016/j.chemosphere.2017.03.138>
- Hazarika, A., Sarkar, S.N., Hajare, S., Kataria, M. and Malik, J.K., 2003. Influence of malathion pretreatment on the toxicity of anilofos in male rats: A biochemical interaction study. *Toxicology*, **185**: 1-8. [https://doi.org/10.1016/S0300-483X\(02\)00574-7](https://doi.org/10.1016/S0300-483X(02)00574-7)
- He, B., Yinhu, N., Yuanxiang, J. and Zhengwei, F., 2020. Pesticides-induced energy metabolic disorders. *Sci. Total Environ.*, pp. 139033. <https://doi.org/10.1016/j.scitotenv.2020.139033>
- Huang, J., Qian, Y., Kai, W. and Fuhua, W., 2019. Residue behavior and risk assessment of cymoxanil in grape under field conditions and survey of market samples in Guangzhou. *Environ. Sci. Pollut. Res.*, **26**: 3465-3472. <https://doi.org/10.1007/s11356-018-3890-1>
- Hussain, A.M. and Sultan, S.T., 2005. Organophosphorus insecticide poisoning: management in surgical intensive care unit. *J. Coll. Phys. Surg. Pak.*, **15**: 100-102.
- Iavicoli, I., Luca, F. and Gunnar, N., 2016. The effects of nanoparticles on the renal system. *Crit. Rev. Toxicol.*, **46**: 490-560. <https://doi.org/10.1080/10408444.2016.1181047>
- Kaya, H., Ekrem, Ş.Ç., Sevdan, Y., Arınç, T., Mehmet, A. and Neslihan, D., 2015. Hematological, serum biochemical, and immunological responses in common carp (*Cyprinus carpio*) exposed to phosalone. *Comp. clin. Pathol.*, **24**: 497-507. <https://doi.org/10.1007/s00580-014-1930-x>
- Khan, I.A., Vijaybhasker, B.R., Mohd, M., Rahman, M.F. and Kaiser, J., 2001. Effects of phosphorothionate on the reproductive system of male rats. *J. environ. Sci. Hlth. B.*, **36**: 445-456. <https://doi.org/10.1081/PFC-100104188>
- Kim, Y.S., Kim, J.S., Cho, H.S., Rha, D.S., Kim, J.M., Park, J.D., Choi, B.S., Lim, R., Chang, H.K., Chung, Y.H., Kwon, I.H., Jeong, J., Han, B.S. and Yu, I.J., 2008. Twenty-eight day oral toxicity, genotoxicity, and gender-related tissue distribution of silver nanoparticles in Sprague-Dawley rats. *Inhal. Toxicol.*, **20**: 575-583. <https://doi.org/10.1080/08958370701874663>
- Korsrud, G.O., Grice, H.C. and McLaughlan, J.M., 1972. Sensitivity of several serum enzymes in detecting carbon tetrachloride-induced liver damage in rats. *Toxicol. appl. Pharmacol.*, **22**: 474-483. [https://doi.org/10.1016/0041-008X\(72\)90255-4](https://doi.org/10.1016/0041-008X(72)90255-4)
- Kumari, M., Rajak, S., Singh, S.P., Kumari, S.I., Kumar, P.U., Murty, U.S., Mahboob, M., Grover, P. and Rahman, M.F., 2012. Repeated oral dose toxicity of iron oxide nanoparticles: Biochemical and histopathological alterations in different tissues of rats. *J. Nanosci. Nanotechnol.*, **12**: 2149-2159. <https://doi.org/10.1166/jnn.2012.5796>
- Lee, I.C., Ko, J.W., Park, S.H., Shin, N.R., Shin, I.S., Moon, C., Kim, J.H., Kim, H.C. and Kim, J.C., 2016. Comparative toxicity and biodistribution assessments in rats following subchronic oral exposure to copper nanoparticles and microparticles. *Part. Fibre Toxicol.*, **13**: 56. <https://doi.org/10.1186/s12989-016-0169-x>
- Liu, X., Yang, Y., Cui, Y., Zhu, H., Li, X., Li, Z., Zhang, K. and Hu, D., 2014. Dissipation and residue of metalaxyl and cymoxanil in pepper and soil. *Environ. Monit. Assess.*, **186**: 5307-5313. <https://doi.org/10.1007/s10661-014-3779-5>
- Lock, E.A. and Reed, C.J., 1998. Xenobiotic metabolizing enzymes of the kidney. *Toxicol. Pathol.*, **26**: 18-25. <https://doi.org/10.1177/019262339802600102>
- Lotti, M. and Johnson, M.K., 1978. Neurotoxicity of organophosphorus pesticides: predictions can be based on in vitro studies with hen and human enzymes. *Arch. Toxicol.*, **41**: 215-221. <https://doi.org/10.1007/BF00354093>
- Mage, D.T., Allen, R.H., Gondy, G., Smith, W., Barr, D.B. and Needham, L.L., 2004. Estimating pesticide dose from urinary pesticide concentration data by creatinine correction in the Third National Health and Nutrition Examination Survey (NHANES-III). *J. exp. anal. Environ. Epidemiol.*, **14**: 457-465. <https://doi.org/10.1038/sj.jea.7500343>
- Mahgoub, A.A. and El-Medany, A.H., 2001. Evaluation of chronic exposure of the male rat reproductive system to the insecticide methomyl. *Pharmacol. Res.*, **44**: 73-80. <https://doi.org/10.1006/phrs.2001.0816>
- Mamun, M.A.A., Rahman, M.A., Belal, S., Islam, M., Sarker, M., Ekram, A.A.E. and Kazi, H., 2015. Histological study of the effect of malathion on liver and kidney tissues of mice model. *Int. J. Pharmacuet. Sci. Res.*, **7**: 043-1048
- Morowati, M., 1997. Inhalation toxicity studies of thimet (phorate) in male Swiss albino mouse, *Mus musculus*: I. Hepatotoxicity. *Environ. Pollut.*, **96**: 283-288. <https://doi.org/10.1016/S0269->

- 7491(97)00052-3
- Nakatani, T., Tawaramoto, M., Opare Kennedy, D., Kojima, A. and Matsui-Yuasa, I., 2000. Apoptosis induced by chelation of intracellular zinc is associated with depletion of cellular reduced glutathione level in rat hepatocytes. *Chem. Biol. Interact.*, **125**: 151-163. [https://doi.org/10.1016/S0009-2797\(99\)00166-0](https://doi.org/10.1016/S0009-2797(99)00166-0)
- Okdah, Y.A., 2005. Effect of antox on metalaxyl fungicide-induced histological and histochemical changes in liver of albino mice. *J. Egypt. German Soc. Zool.*, **48**: 205.
- Rahman, M.F., Siddiqui, M..KJ. and Kaiser, J., 2000. Inhibition of acetylcholinesterase and different ATPases by a novel phosphorothionate (RPR-II) in rat brain. *Ecotoxicol. Environ. Saf.*, **47**: 125-129. <https://doi.org/10.1006/eesa.2000.1956>
- Recena, M.C.P., Dario, X.P. and Eloisa, D.C., 2006. Acute poisoning with pesticides in the state of Mato Grosso do Sul, Brazil. *Sci. Total Environ.*, **357**: 88-95. <https://doi.org/10.1016/j.scitotenv.2005.04.029>
- Reitman, S. and Sam, F., 1957. A colorimetric method for the determination of serum glutamic oxalacetic and glutamic pyruvic transaminases. *Am. J. clin. Pathol.*, **28**: 56-63. <https://doi.org/10.1093/ajcp/28.1.56>
- Savolainen, H., 1978. Superoxide dismutase and glutathione peroxidase activities in rat brain. *Res. Commun. Chem. Pathol. Pharmacol.*, **21**: 173-176.
- Sayim, F., 2007. Dimethoate-induced biochemical and histopathological changes in the liver of rats. *Exp. Toxicol. Pathol.*, **59**: 237-243. <https://doi.org/10.1016/j.etp.2007.05.008>
- Singh, S.P., Monika, K., Srinivas, I.K., Mohammed, F.R., Mahboob, M. and Paramjit, G., 2013. Toxicity assessment of manganese oxide micro and nanoparticles in Wistar rats after 28 days of repeated oral exposure. *J. appl. Toxicol.*, **33**: 1165-1179. <https://doi.org/10.1002/jat.2887>
- Stacey, R., Morfey, D. and Payne, S., 2004. Secondary contamination in organophosphate poisoning: Analysis of an incident. *Qurt. J. Med.*, **97**: 75-80. <https://doi.org/10.1093/qjmed/hch020>
- Steger, K., Rey, R, Louis, F, Kliesch, S, Behre, H.M., Nieschlag, E., Hoepffner, W., Bailey, D, Marks, A, and Bergmann, M., 1999. Reversion of the differentiated phenotype and maturation block in Sertoli cells in pathological human testis. *Hum. Reprod.*, **14**: 136-143. <https://doi.org/10.1093/humrep/14.1.136>
- Sun, S., Ruifa, H., Chao, Z. and Guanming, S., 2019. Do farmers misuse pesticides in crop production in China? Evidence from a farm household survey. *Pest Manage. Sci.*, **75**: 2133-2141. <https://doi.org/10.1002/ps.5332>
- Timur, S., Seçil, Ö., Karabay, N.Ü., Ferah, S. and Figen, Z., 2003. *In vivo* effects of malathion on glutathione-S-transferase and acetylcholinesterase activities in various tissues of neonatal rats. *Turkish. J. Zool.*, **27**: 247-252.
- Toś-Luty, S., Daniela, O-P., Jadwiga, L., Malgorzata, T-R. and Agnieszka, H-M., 2003. Dermal and oral toxicity of malathion in rats. *Ann. Agric. Environ. Med.*, **10**: 101-106.
- Urech, P.A., Schwinn, F. and Staub, T., 1977. *CGA 48988 a novel fungicide for the control of late blight, downy mildews and related soil borne diseases*. British Crop Protection Conference; Proceedings.
- Uzunhisarcikli, M., Yusuf, K., Kerem, D., Suna, K., Ayse, O. and Fatma, B., 2007. Acute, subacute and subchronic administration of methyl parathion-induced testicular damage in male rats and protective role of vitamins C and E. *Pestic. Biochem. Physiol.*, **87**: 115-122. <https://doi.org/10.1016/j.pestbp.2006.06.010>
- Yehia, M.A.H., Sabah, G.E-B. and Aly, B.O., 2007. Diazinon toxicity affects histophysiological and biochemical parameters in rabbits. *Exp. Toxicol. Pathol.*, **59**: 215-225. <https://doi.org/10.1016/j.etp.2007.09.003>
- Yun, J.W., Seung-Hyun, K., Ji-Ran, Y., Woo, H.K., Ja-June, J., Seung-Kee, M., Hee, C.K., Doo, H.C., Jayoung, J. and Byeong-Cheol, K., 2015. Comparative toxicity of silicon dioxide, silver and iron oxide nanoparticles after repeated oral administration to rats. *J. appl. Toxicol.*, **35**: 681-693.
- Zuskin, E., Jadranka, M., Schachter, E.N., Josipa, K., Vlasta, D-V., Ivancica, T. and Angelo, C., 2008. 'Respiratory function in pesticide workers. *J. Occup. environ. Med.*, **50**: 1299-1305. <https://doi.org/10.1097/JOM.0b013e3181845f6c>