

Osteometric Measurements on Topographic and Morphological Structure of Foramen in Regiones Capitis in Gurcu Goats

Semine Dalga* and Kadir Aslan

Department of Anatomy, Faculty of Veterinary Medicine, Kafkas University, Kars-36100, Turkey

ABSTRACT

In this study, the clinically significant foramen and bones comprising the skull in the regiones capitis of Gurcu goats were examined topographically. Twelve adult goat skulls of both sexes (n=6 males and n=6 females) that did not produce fertile offspring were used in the study. Twenty different morphometric measurements were taken on the skull. Four distinct reference points were measured for the selection site of the infraorbital foramen. A reference point was used for the selection site of the oval foramen. In both sexes, the skulls of the goats were observed to be elongated and dolichocephalic according to the cephalic index ($49.24 \pm 3.47/48.31 \pm 4.87$). The length of the skulls was found as 222.71 ± 16.74 mm in females and 240.19 ± 26.29 mm in males. It was observed that half of the materials lacked the supraorbital foramen, which should be located on both sides of the frontal bone. The remaining animals possessed it only on one side. The tuber faciale was prominently located dorsally at the intersection of the last premolar and the first molar in both sexes. The infraorbital foramen was located dorsal to the second upper premolar tooth on the os maxilla. The septal process was shown to terminate with two ends in females and a single end in males. It was observed that the processus nasalis of the os incisum extended to the os nasale, with incisura nasoincisus being located between them. Nasomaxillary fissure was observed to be present in females. The findings of this study are believed to be applicable in clinical veterinary practice, the blocking of terminal branches of cranial nerves between sexes, the treatment of dental injuries and possibly zooarchaeology.

Article Information

Received 30 January 2022

Revised 05 March 2022

Accepted 31 March 2022

Available online 08 August 2022
(early access)

Published 14 October 2022

Authors' Contribution

SD and KA designed the study. SD and KA performed the macro-anatomical and morphometric analysis. SD carried out the statistical analysis. SD and KA performed the imaging all section. The manuscript was written by SD. All authors approved the final version.

Key words

Cephalometry, Cranium, Sexual dimorphism, Morphology

INTRODUCTION

The foramina on the skull are of great importance for clinical purposes because they serve as the exit holes for nerves. To be able to apply anesthesia to the nerve extensions protruding from these holes, it is necessary to determine their precise locations. In addition to these holes, which are palpable bone sites in ruminants such as the infraorbital foramen, mental foramen, supraorbital foramen, regiones capitis, which is also found in mandibular foramen, oval foramen and maxillary foramen, which are all of practical importance (Dursun, 2000). Gurcu goats originating from

the Caucasus, also known as Tbilisi goat or Caucasian goat, are bred in Northern Anatolia, particularly in Kars province and the Çıldır district of Ardahan. Gurcu goats, which are predominantly black, gray and white in color, are descended from the auger horned goat *Capra falconeri* and may show similarities with Abaza goats bred especially in the Şavşat or Borcka region (Batu, 1951). The morphometric characteristics of Gurcu goats, which are one of Turkey's domestic gene resources, remain unclear due to their lack of study. There are numerous studies on morphometry and applied clinical anatomy in domestic and wild species in the literature (Onar, 1999; Onar *et al.*, 2005; Sarma, 2006; Jakubowski *et al.*, 2008; Baranowski, 2010; Parés *et al.*, 2010; Özcan *et al.*, 2010; Onuk *et al.*, 2013; Avdic *et al.*, 2013; Demiraslan *et al.*, 2014; Dalga *et al.*, 2018; Gündemir *et al.*, 2020; Özkan *et al.*, 2020; Yılmaz and Demircioğlu, 2020; Dalga and Aslan, 2020; Jashari *et al.*, 2021). Additionally, there are numerous studies in the literature examining goat species (Olopade and Onwuka, 2005, 2008; Uddin *et al.*, 2009; Monfared *et al.*, 2013; Goodarzi and Hoseini, 2014; Choudhary *et al.*, 2020; Din *et al.*, 2020; Wang *et al.*, 2021; Dalga and Aslan, 2021). This study was designed to detail the skull

* Corresponding author: seminedalga@kafkas.edu.tr, sdalga91@gmail.com
0030-9923/2023/0001-23 \$ 9.00/0



Copyright 2023 by the authors. Licensee Zoological Society of Pakistan.

This article is an open access article distributed under the terms and conditions of the Creative Commons Attribution (CC BY) license (<https://creativecommons.org/licenses/by/4.0/>).

morphometry and topographically significant blockage areas of the skulls of Gurcu goats raised in Şavşat Borcka.

MATERIALS AND METHODS

In this study, 12 Gurcu goat skulls were analyzed to determine the locations of the holes found in regiones capitis and the topographical structure of the bones that comprise the skull. The study's samples consisted of 12 (n=6 males and n=6 females) adult (approximately 3-4 years old) goat skulls without any skeletal problems. The study was approved with the permission of the Animal Experiments Local Ethics Committee (KAÜ-HADYEK/2020-153). After deatching the skulls from their skin and muscles, they were subjected to maceration. Maserated skull specimens were kept in 4% hydrogen peroxide for one day to whiten the bones. A total of 25 measurements were taken using digital calipers from the skulls of Gurcu goats whose morphometric measurements were not defined (Driesch, 1976). All measurements obtained were statistically analyzed. The obtained data were expressed as mean \pm standard deviation (S.D.). Parameters taken from the skulls of goats are shown in Figures 1 and 2.

Skull measurement

Skull length (L1): Distance between the highest points of the parietal bones and the middle of the rostral margin of the incisive bone.

Skull width (L2): Distance between two zygomatic arches.

Cranial length (L3): Distance from the central point of the frontonasal suture to the middle point of the nuchal crest.

Cranial width (L4): Distance between the bases of both the horns.

Facial length (L5): Distance from the frontonasal suture to the center of the incisive bone.

Facial width (L6): Distance between the caudal extents of the orbital rims.

Length of the maxilla (L7): Distance from parietofrontal suture to the frontonasal suture.

Width of the maxilla (L8): Distance from interfrontal suture to the rim of the orbit

Height of orbit (Ho) (L9), Width of orbit (Wo) (L10), Length of nasal bone (L11): Distance from the central point of the frontonasal suture to the rostral end of the internasal suture.

Width across nasal bone (L12): Distance across the nasal bones or distance between the naso-maxillary sutures.

Length of palatine (L13): Distance between the

rostral mid sutured line of incisive bone and the caudal nasal spine of the palatine bone.

Width of palatine (L14): Distance at the horizontal plate of palatine bone behind the last molar tooth.

Length of occipital (L15): Distance between external margins of two paracondylar processes

Height of occipital (L16): Distance from base of the occipital condyle to the starting point of the sagittal crest

Intercondylar width (L17): Width between the lateral margins of the occipital condyles.

Interparacondylar width (L18): The greatest width between the ventromedial end of the paracondylar processes.

Height of foramen magnum (L19): Distance between the midpoints of the dorsal and ventral rims of the foramen magnum.

Width of the foramen magnum (L20): Distance between the two occipital condyles (Figs. 1, 2).

Craniofacial indices

a) Skull/cephalic index (SKI): Skull width X 100/ skull length.

b) Cranial index (CRI): Cranial width X 100/ cranial length.

c) Facial index (FAI): Facial width X 100/ facial length.

d) Nasal index (NI): Nasal width X 100/ nasal length.

e) Foramen magnum index (FMI): Foramen magnum height X 100/ foramen magnum width.

Infraorbital foramen measurement its for anesthesia infraorbital nervus

a) Infraorbital foramen distance: Distance between two infraorbital foramina.

b) Facial tuberosity to the infraorbital foramen (FTIO): It was measured from the level of most lateral bulging of facial tuberosity to mid-level of the infraorbital foramen.

c) Infraorbital foramen to root of the alveolar tooth: It was measured from the mid-level of the infraorbital foramen to the alveolar root of the superior second premolar tooth.

d) Infraorbital foramen to orbit: It was measured from the orbit to the infraorbital foramen

RESULTS

Macroanatomical results

All of the bones forming the neurocranium and viscerocranium were present in the skulls. Processus paracondylaris was observed to be curved or hook-shaped (Fig. 2/5). The supraorbital foramina, which should be on both sides of the frontal bone, were absent in half of

the materials (Fig. 2/7). It was only present on one side in the other half of the materials. The tuber faciale was prominently located dorsally at the junction of the last premolar and the first molar in both sexes (Fig. 2/8). The foramen infraorbitale was located dorsal to the second upper premolar tooth on the os maxilla (Fig. 2/8). Processus septal terminated with two ends in females and a simngle end in males (Fig. 2/7). It was observed that the processus nasalis of os incivus extended to the os nasale, with incisura nasoincivus being located between them. Females were found to possess nasomaxillaris (Fig. 2/5).

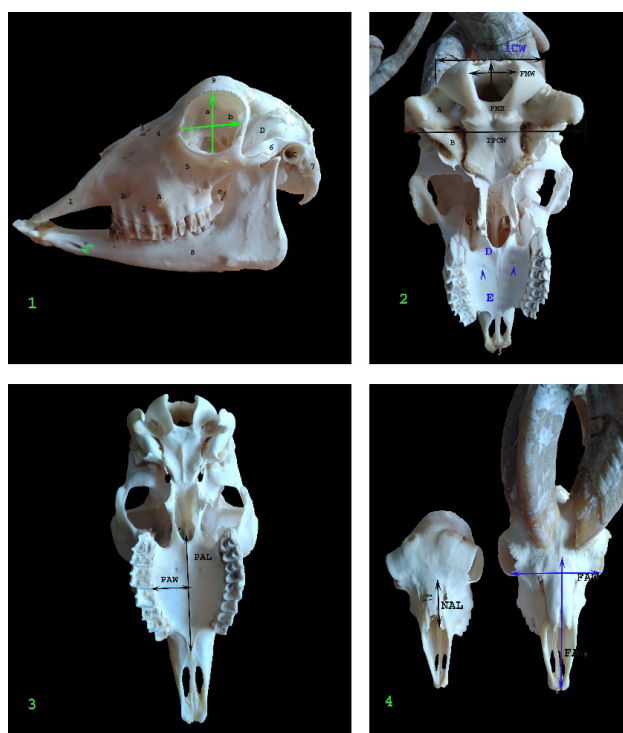


Fig. 1. Some points on the skull of Gurcu goats. **1:** A, Facial tuberosity; B, Infraorbital foramen; C, Porus acusticus externus; D, Processus corocoideus; 1, Incisiv bone; 2, Maxillar bone; 3, Nasal bone; 4, Lacrimal bone; 5 and 6, Occipital bone; 7, Paracondylar process; 8, Mandible; 9, Frontal bone; a, height of bulbus oculi; b, length of bulbus oculi; c, oval foramen; narrowhead, mental foramina; **2:** Measurement of the skull (ventral view) of Gurcu goat; ICW, Intercondylar width; FMW, Width of foramen magnum; FMH, Height of foramen magnum; IPCW, Interparacondylar width; A, Fossa condylaris ventralis; B, Tympanic bullae; C, Maxillar foramen; D, Horizontal lamina of os palatinum; E, Processus palatinus of maxilla; narrowhead, foramen palatinum majus; **3:** PAW, Width of palatine; PAL, Length of palatine; **4:** Measurements of the skull (dorsal view) of Gurcu goat; NAW, Width of nasal; NAL, Length of nasal; FAW, Facial width; FAL, FACIAL length.

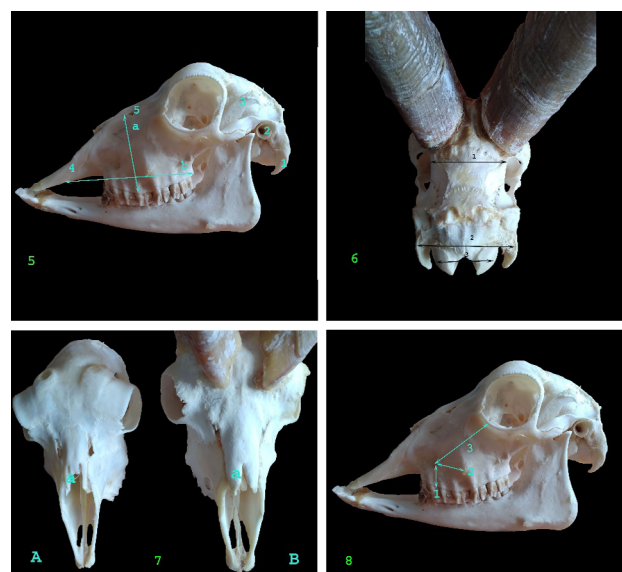

Fig. 2. Measurement of skull lateral view of Gurcu goats. **5:** a, Width of maxilla; b, Length of maxilla; 1, paracondylar process; 2, meatus acusticus externus; 3, coronoid process; 4, nasal bone; 5, nasolacrimal fissur; **6:** Measurement of skull occipital view of Gurcu goats; 1, Width of parietal; 2, Interparacondylar width; 3, Intercondylar width; **7:** Dorsal view of skull in female and male Gurcu goats; A, Female Gurcu goat; B, Male Gurcu goat; a, Septal process; **8:** 1, Distance between foramen infraorbital and premolar tooth; 2, The distance between foramen infraorbitale and tuber faciale; 3, The distance between foramen infraorbitale and orbita.

Morphometrical results

According to the results of the statistical analysis, the mean skull length was determined as 222.71 ± 16.74 mm in females and 240.19 ± 26.29 mm in males. Similarly, the cranial length measured from the skulls was calculated as 130.47 ± 10.26 mm in females, 144.75 ± 15.21 mm in males, and facial length as 118.63 ± 10.69 mm in females and 113.3 ± 17.87 mm in males (Table I). According to the parameters taken to enable anesthesia of the foramen infraorbitale, the mean distance between the tuber faciale and the foramen infraorbitale was 25.79 ± 1.65 mm in females and 27.29 ± 3.36 mm in males (Table II). In the blockage of the nervus mandibularis, an injection is performed from the incisura mandibularis towards the ear level of the opposite side to anesthetize from the foramen ovale. The distance between the foramen ovale and the incisura mandible is 30.31 ± 1.49 mm in females and 31.44 ± 2.78 mm in males. This measured parameter provides access to the foramen ovale. According to craniofacial index calculations, skull index was measured as 48.31 ± 4.87 in females, 49.24 ± 3.47 in males, and facial index as 74.61 ± 7.58 in females and 105.74 ± 19.28 in

males. According to the cephalic index, both sexes' skulls were found to be dolichocephalic (Table III).

Table I. The mean value of parameters its on Gurcu goat skull.

Craniofacial index	Female (n=6)	Male (n=6)
L1	222.72±7.49	240.19±11.76
L2	106.99±1.47	117.87±5.22
L3	130.47±4.59	144.75±6.81
L4	67.04±2.16	71.89±1.58
L5	118.64±4.78	113.37±7.99
L6	87.92±1.74	117.24±1.93
L7	105.15±4.47	108.63±5.73
L8	59.35±1.77	66.68±3.15
L9	38.01±.60	39.49±2.13
L10	36.66±.67	35.95±1.18
L11	51.54±1.36	62.64±4.05
L12	12.63±.62	16.01±1.52
L13	74.41±1.66	85.22±5.96
L14	23.51±.78	24.15±.90
L15	57.09±3.03	78.81±6.63
L16	48.56±1.79	61.41±3.17
L17	48.74±.79	55.55±2.21
L18	75.96±1.35	88.55±5.15
L19	22.32±1.08	21.23±1.03
L20	19.85±.84	21.41±1.55

For details of indices, see Materials and Methods.

Table II. The mean value of infraorbital foramen its taken from Gurcu goat skull.

Parameters	Female (mm)	Male (mm)
A	44.26±3.01	46.62±4.44
B	25.79±1.65	27.29±3.36
C	18.93±2.46	23.04±2.59
D	53.14±3.35	56.83±7.18

A, The distance between two foramen infraorbital; B, The distance between foramen infraorbitale and tuber faciale; C, Distance between foramen infraorbital and premolar tooth; D, The distance between foramen infraorbitale and orbita.

Table III. The measurement of craniofacial index from Gurcu goats.

Craniofacial index	Male (n=6)	Female (n=6)
SKI	49.24±1.55	48.31±2.18
CRI	50.17±2.17	51.76±3.11
FAI	105.74±8.62	74.61±3.39
NI	25.78±2.51	24.59±1.33
FMI	100.90±7.61	112.36±1.63

For details of indices, see Materials and Methods.

DISCUSSION

In this study, the bones comprising the skulls of Gurcu goats and the holes that serve as anesthesia application points were evaluated topographically and morphometrically. When the morphometric measurements acquired from the skulls were compared between sexes, no statistical difference was found. This finding is consistent with the literature (Samuel, 2013; Din *et al.*, 2020; Wang *et al.*, 2021). In 33% (2) of the materials belonging to female Gurcu goats, the foramen ovale was found to be quite wide. This was also observed in the skulls of 7 Sharri sheep (Jashari *et al.*, 2021). Similar to Sharri sheep, Gurcu goats had a large tuberculum muscularis located at the border between the occipital and sphenoid bones. In Gurcu goats, the processus septalis of the os nasale ended with a tip that differed greatly between the sexes. They had a "U" shaped nasofrontal suture between their os frontale and os nasale. This is similar to Mehraban sheep (Karimi *et al.*, 2011), whereas in Sharri sheep, the nasofrontal suture was reported to be "U" and "V" shaped (Jashari *et al.*, 2021), and "V" shaped in Bardhoka sheep (Gündemir *et al.*, 2020). The skull length parameter, which is of great importance in most skull morphometric studies and is frequently emphasized, was determined as 222.71±16.74 mm in females and 240.19±26.29 mm in males in Gurcu goats. In previous studies, it has been found as 22.67±0.93 cm in Saanen goats (Wang *et al.*, 2021), 16.99±1.59 cm in WADG goats (Oloopade, 2005), 18.67±0.66 cm in Markhoz goats (Goodarzi and Hosseini, 2014), 20.68±0.02 cm in blackbucks (Choudhary and Singh, 2015), 19.73±0.11 in female and 19.99±0.25 cm in male Beetal goats (Din *et al.*, 2020), 241.30±14.01 in Awasssi sheep (Yılmaz and Demircioğlu, 2020), 204.49±9.71 and 198.09±7.69 mm in female and male Morkaraman and Tuj sheep, respectively (Özcan *et al.*, 2010), and 245.25±10.24 and 257.98±15.81 mm in female and male Bardhoka sheep, respectively (Gündemir *et al.*, 2020). According to Lakshmi *et al.* (2015), cephalic/skull index analysis is an important parameter in sex determination, forensic medicine and anthropology. In this study, the skulls were found to be dolichocephalic according to this index. This finding was similar to that for Kagani goats (Sarma, 2006) and blackbucks (Choudhary *et al.*, 2020). The skull index of Gurcu goats was analyzed to be 49.24±3.47 in males and 48.31±4.87 in females. This index is 52.15±2.11 in Saanen goats (Wang *et al.*, 2021), 47.77±1.96 in Markhoz goats (Goodarzi and Hosseini, 2014), 47.82±0.05 in Mizoram goats (Choudhary *et al.*, 2020), 46.12±0.12 in blackbucks (Choudhary and Singh, 2015). Additionally, a recent study reported the skull index in Beetal goats as 57.32±0.10 in females and 57.72±0.14 in males (Din *et al.*, 2020). The

skull index values of Gurcu goats was lower than those of Saanen (Wang *et al.*, 2021) and Beetal goats (Din *et al.*, 2020) and higher than those of Markhoz goats (Goodarzi and Hosseini, 2014), Mizoram goats (Choudhary *et al.*, 2020), and blackbucks (Choudhary and Singh, 2015). The skull index of Abaza goats, which live in the same region and are morphologically similar to Gurcu goats, has been reported as 51.0 ± 1.8 (Dalga and Aslan, 2021). The mean facial lengths and widths of the skulls were 118.63 ± 10.69 and 87.92 ± 3.88 mm in females, and 113.37 ± 17.87 and 117.23 ± 4.30 mm in males, respectively. It has been reported in the literature as 11.53 ± 0.08 cm, 9.30 ± 0.015 cm for blackbucks (Choudhary and Singh, 2015), and 10.20 ± 0.08 , 6.58 ± 0.02 cm for Mizoram goats (Choudhary *et al.*, 2020). The facial index in Gurcu goats was analyzed as 74.61 ± 7.58 in females and 105.74 ± 19.28 in males. This index was reported as 85.44 ± 1.89 for Mizoram goats (Choudhary *et al.*, 2020), 85.44 ± 1.89 for Mehraban sheep (Karimi *et al.*, 2011), 138.48 ± 0.57 for Kagani goats (Sarma, 2006), 100.77 ± 6.85 for Markhoz goats (Goodarzi and Hosseini, 2014) goats, and 80.67 ± 0.44 for blackbucks (Choudhary and Singh, 2015). The length and width of the nasal bones in Gurcu goats were 51.53 ± 3.04 and 12.62 ± 1.38 mm in females, and 62.64 ± 9.05 and 16.01 ± 3.40 mm in males, respectively. These parameters were reported as 5.59 ± 0.03 , 0.97 ± 0.01 for Mizoram goats (Choudhary *et al.*, 2020), 6.50 ± 0.11 , 3.20 ± 0.57 for Kagani goats (Sarma, 2006), and 5.69 ± 0.01 , 1.29 ± 0.01 for blackbucks (Choudhary and Singh, 2015). The topographies of the infraorbital nerve and infraorbital foramen are critical for intra- and extraoral anesthesia applications, as well as a safe surgical intervention (Mozsary and Middleton, 1983; Lawrence and Poole, 1992; Zide and Swift, 1998). The distance between the infraorbital foramen and the premolar teeth in Gurcu goats was determined to be 18.93 ± 2.46 mm in females and 23.04 ± 2.59 mm in males. The height and width of the foramen magnums of Gurcu goats were analyzed as 22.32 ± 2.42 and 19.85 ± 1.87 mm in females, and 21.23 ± 2.30 and 21.40 ± 3.47 mm in males, respectively. These parameters were reported as 1.81 ± 0.02 and 1.71 ± 0.01 in female, and 5.73 ± 0.01 and 2.43 ± 0.06 cm in male Mizoram goats (Choudhary *et al.*, 2020), respectively. In a study conducted in India, these parameters were reported as 1.74 ± 0.00 cm, 2.03 ± 0.00 cm, 8.22 ± 0.01 cm, and 0.88 ± 0.00 cm, respectively for blackbucks (Choudhary and Singh, 2015). In a study conducted in Iran, it was reported as 3.08 ± 0.35 , 3.12 ± 0.36 cm, and 12.30 ± 0.28 cm, 2.53 ± 0.58 cm, respectively for Kagani goats (Sarma, 2006). In a different study, they were reported as 2.35 ± 0.06 , 2.00 ± 0.04 cm, and 2.39 ± 0.07 , 2.02 ± 0.03 cm for Beetal goats (Din *et al.*, 2021). Choudhary *et al.*, (2020) determined sex using the foramen magnum index

parameter. This index was measured as 100.90 ± 17.02 mm in females and 112.36 ± 3.65 mm in males in Gurcu goats. There was no statistical difference between them. The Foramen magnum index for Mizoram goats was reported as 94.47 ± 0.28 (Choudhary *et al.*, 2020), as 89.32 ± 14.1 for Markhoz goats (Goodarzi and Hosseini, 2014), 98.71 ± 0.28 for blackbucks (Choudhary and Singh, 2015), 85.16 ± 0.04 for female and 84.62 ± 0.05 for male Beetal goats. The height and width of the orbits in Gurcu goats' skulls were determined as 38.01 ± 1.34 , 36.66 ± 1.49 mm in females and 39.49 ± 4.77 and 35.95 ± 2.63 in males, respectively. In Beetal goats (Din *et al.*, 2020), orbital height and length was 3.40 ± 0.06 cm and 4.25 ± 0.06 cm in females, and in males, 4.25 ± 0.06 and 3.40 ± 0.06 cm, respectively.

CONCLUSION

As a result, data were presented on skull anatomy, formations, and skull holes used for regional anesthesia in Gurcu goats. It is believed that these data revealed on Gurcu goats in terms of sex differences can be compared with other goat breeds in Turkey and used as a reference for clinical procedures in the head region.

Ethical approval

This study was approved by the Kafkas University Animal Experiments Local Ethics Committee (Approval no: 2020/153).

Financial support

This work was not supported by any institution.

Statement of conflict of interest

The authors have declared no conflicts of interest.

REFERENCES

- Avdić, R., Hadžiomerović, N., Tandir, F., Bejdić, P., and Ćutahija, V., 2013. Analysis of morphometric parameters of the roe deer mandible (*Capreolus capreolus*) and mandible of the sheep (*Ovis aries*). *Veterinaria (Sarajevo)*, **62**: 1–9.
- Baranowski, P., 2010. Morphometric analysis of early medieval dog skulls from Pomerania allowing for forehead position index and dorsal notch of the foramen magnum. *Electron. J. Polish Agric. Uni.*, **13**: 16–28.
- Batu, S., 1951. *Türkiye Keçi Irkları*. Ankara Üniversitesi Veteriner Fakültesi Yayınları, Ankara.
- Choudhary, O.P., Priyanka, Kalita, P.C., Arya, R.S., Kalita, A., Doley, P.J., and Keneisenno, 2020. A morphometrical study on the skull of goat

- (*Capra hircus*) in Mizoram. *Int. J. Morphol.*, **38**: 1473-1478. <https://doi.org/10.4067/S0717-95022020000501473>
- Choudhary, O.P. and Singh, I., 2015. Morphometrical studies on the skull of Indian blackbuck (*Antelope cervicapra*). *Int. J. Morphol.*, **33**: 868-876.
- Dalga, S., and Aslan, K., 2020. Topographic and morphometric study on mental foramen in Hemshin sheep for local anesthesia. *Manas J. Agric. Vet. Life Sci.*, **10**: 93-97.
- Dalga, S., Aslan, K., and Akbulut, Y., 2018. A morphometric study on the skull of the adult Hemshin sheep. *Van. Vet. J.*, **29**: 125-129.
- Dalga, S., and Aslan, K., 2021. Morphological and osteometric analysis of the skull in Abaza goats (*Capra aegagrus*). *Dicle Üniv. Vet. Fak. Derg.*, **14**: 35-38.
- Demiraslan, Y., Gülbaz, F., Özcan, S., Dayan, O.M., and Akbulut, Y., 2014. Morphometric analysis of the mandible of Tuj and Morkaraman sheep. *J. Vasc. Access*, **7**: 75-86. <https://doi.org/10.21608/jva.2014.44813>
- Driesch von den, A., 1976. *A guide to the measurement of animal bones from archeological sites*. Peabody Museum Bulletin, Harvard University, Massachusetts.
- Dursun, N., 2000. *Veteriner topografik anatomi*, Medisan Yayınevi.
- Goodarzi, N. and Hoseini, T.S., 2014. Morphologic and osteometric analysis of the skull of Markhoz goat (Iranian angora). *Vet. Med. Int.*, **2014**: 972682. <https://doi.org/10.1155/2014/972682>
- Gündemir, O., Duro, S., Jashari, T., Kahvecioğlu, O., Demircioğlu, İ., and Mehmeti, H., 2020. A study on morphology and morphometric parameters on skull of the *Bardhoka autochthonous* sheep breed in Kosovo. *Anat. Histol. Embryol.*, **49**: 365-371. <https://doi.org/10.1111/ahe.12538>
- Jakubowski, H., Komosa, M., and Frackowiak, H., 2008. Allometric analysis of cranial parameters of American mink, including bones of masticatory apparatus. *Electron. J. Polish Agric. Univ.*, **11**: 2-10.
- Jashari, T., Duro, S., Gündemir, O., Szara, T., Ilieski, V., Mamuti, D. and Choudhary, O.P., 2021. Morphology, morphometry and some aspects of clinical anatomy in the skull and mandible of Sharri sheep. *Biologia*, **77**: 423-433. <https://doi.org/10.1007/s11756-021-00955-y>
- Karimi, I., Onar, V., Pazvant, G., Hadipour, M. and Mazaher, Y., 2011. The cranial morphometric and morphologic characteristics of Mehraban sheep in western Iran. *Glob. Vet.*, **6**: 111-117.
- Lakshmi, K.K., Vijaya, P.V.S.S., Kusuma, K.P., and Nagamani, M., 2015. A study of cephalic index and facial index in Visakhapatnam, Andhra Pradesh, India. *Int. J. Res. med. Sci.*, **3**: 656-658. <https://doi.org/10.5455/2320-6012.ijrms20150324>
- Lawrence, J.E. and Poole, M.D., 1992. Mid-facial sensation following craniofacial surgery. *Br. J. Plast. Surg.*, **45**: 519-522. [https://doi.org/10.1016/0007-1226\(92\)90146-O](https://doi.org/10.1016/0007-1226(92)90146-O)
- Monfared, A.L., Naji, H. and Sheibani, M.T., 2013. Applied anatomy of the head region of the Iranian native goats (*Capra hircus*). *Glob. Vet.*, **10**: 60-64.
- Mozsary, P.G. and Middleton, R.A., 1983. Microsurgical reconstruction of the infraorbital nerves. *J. Oral Maxillofac. Surg.*, **41**: 697-700. [https://doi.org/10.1016/0278-2391\(83\)90183-0](https://doi.org/10.1016/0278-2391(83)90183-0)
- Nomina Anatomica Veterinaria, 2017. International Committee on Veterinary Gross Anatomical Nomenclature: General assembly of the world association of veterinary anatomists. 6th edition, Gent.
- Olopade, J.O. and Onwuka, S.K., 2008. A craniometric analysis of the skull of the Red Sokoto (Maradi) goat (*Capra hircus*). *Eur. J. Anat.*, **12**: 57-62.
- Olopade, J.O. and Onwuka, S.K., 2005. Some aspects of the clinical anatomy of the mandibular and maxillofacial regions of the West African dwarf goat in Nigeria. *Int. J. Morphol.*, **23**: 33-36. <https://doi.org/10.4067/S0717-95022005000100006>
- Onar, V., 1999. A morphometric study on the skull of the German shepherd dog (*Alsatian*). *Anat. Histol. Embryol.*, **28**: 253-256. <https://doi.org/10.1046/j.1439-0264.1999.00202.x>
- Onar, V., Belli, O., and Owen, P.R., 2005. Morphometric examination of red fox (*Vulpes vulpes*) from the Van-Yoncatepe Necropolis in Eastern Anatolia. *Int. J. Morphol.*, **23**: 253-260. <https://doi.org/10.4067/S0717-95022005000300011>
- Onuk, B., Kabak, M., and Atalar, K., 2013. Anatomic and craniometric factors in differentiating roe deer (*Capreolus capreolus*) from sheep (*Ovis aries*) and goat (*Capra hircus*) skulls. *Arch. Biol. Sci.*, **65**: 133-141. <https://doi.org/10.2298/ABS1301141M>
- Özcan, S., Aksoy, G., Kürtül, I., Aslan, K. and Özudogru, Z., 2010. A comparative Morphometric Study on the skull of the Tuj and Morkaraman sheep. *J. Kafkas Univ. Vet. Fak. Derg.*, **16**: 111-114.
- Özkan, E., Jashari, T., Gündemir, O., and Gezer-İnce, N., 2020. Morphometric analysis of the mandible of Bardhoka autochthonous sheep in Kosovo. *Anat. Histol. Embryol.*, **49**: 737-741. <https://doi.org/10.1007/s11756-021-00955-y>

- [org/10.1111/ahc.12568](https://doi.org/10.1111/ahc.12568)
- Parés, I. Casanova, P.M., Kamal, S., and Jordana, J., 2010. On biometrical aspects of the cephalic anatomy of Xisqueta sheep (Catalunya, Spain). *Int. J. Morphol.*, **28**: 347-351. <https://doi.org/10.4067/S0717-95022010000200001>
- Din, S., Masood, S., Zaneb, H., Rehman, H., Ashraf, S., Khan, I., Shah, M. and Hadi, S.A., 2020. An osteometric study of the skull of adult Beetal goat. *J. Anim. Pl. Sci.*, **30**: 828-835.
- Samuel, O.M., Olopade, J.O., Korzerzer, M.R., and Onwuka, S.K., 2013. Craniometric evaluation of some cranial indices of clinical significance in goats (*Capra hircus*) from the Middle-Belt Region of Nigeria – case for population surveillance and ecomigration. *Eur. J. Wildl. Res.*, **2**: 89-97.
- Sarma, K., 2006. Morphological and craniometrical studies on the skull of Kagani goat (*Capra hircus*) of Jammu Region. *Int. J. Morphol.*, **24**: 449-455. <https://doi.org/10.4067/S0717-95022006000400025>
- Uddin, M.M., Ahmed, S.S.U., Islam, K.N., and Islam, M.M., 2009. Clinical anatomy of the head region of the black Bengal goat in Bangladesh. *Int. J. Morphol.*, **27**: 1269-1273. <https://doi.org/10.4067/S0717-95022009000400048>
- Wang, X., Liu, A., Zhao, J., Elshaer, F.M. and Massoud, D., 2021. Anatomy of the skull of Saanen goat. An anesthesiology and stereology approach. *Int. J. Morphol.*, **39**: 423-429. <https://doi.org/10.4067/S0717-95022021000200423>
- Yılmaz, B., and Demircioglu, İ., 2020. İvesi Koyunlarda (*Ovis aries*) Kafatasının Morfometrik Analizi. *Fırat Üniv. Sağlık Bilimleri Vet. Derg.*, **34**: 1-6.
- Zide, B., and Swift, R., 1998. How to block and tackle the face. *Plast. Reconstr. Surg.*, **101**: 840-851. <https://doi.org/10.1097/00006534-199803000-00041>