



Evaluation of Wound Healing and Anti-Oxidative Activity of Acacia Honey and N-Acetylcysteine in Sprague Dawley Rats

Fatima Ali^{1*}, Rimsha Tahir¹ and Tahir Rehman Samiullah²

¹*Institute of Molecular Biology and Biotechnology (IMBB), The University of Lahore (UOL), Lahore, Pakistan.*

²*Center of Excellence in Molecular Biology, University of The Punjab, Lahore, Pakistan.*

ABSTRACT

Honey has been widely used in the treatment of wound as dressing for the last thousands of years, however its effectiveness in clinical trials not yet been fully recognized. It is now known that honey acts as a biologic wound dressing with multiple bioactivities. Major aim of this study was to evaluate the efficacy of honey in combination with N-acetyl cysteine (NAC) for the treatment of excisional wounds in rats. Sprague Dawley (SD) rats were inflicted with excisional wounds. Wounds were treated with honey as control group and in combinations with 1%, 3% and 5% NAC. Wound area was measured after 3rd, 7th, 10th and 14th day. Improvement in wound healing was also confirmed by analyzing angiogenesis, apoptosis and chemotaxis genes. A significant increase was observed in the percentage of wound contraction and significant decrease in the period of epithelialization in honey+3% NAC group as compared with control group. Histologically, honey+3% NAC Group treatment resulted in almost complete re-epithelialization and re-structuring of the wound tissue. There was a significant rise in catalase and decrease in GSH levels in the control group that was reversed to a major extent by the application of honey+3% NAC dressing. The results revealed the improved wound healing potential of honey+3% NAC dressing. It can be concluded that beneficial effects of honey in combination with NAC accelerated wound healing in rats by enhancing proliferation, mobilization and angiogenesis at wound site.

Article Information

Received 09 August 2021

Revised 13 May 2022

Accepted 17 June 2022

Available online 07 September 2022 (early access)

Published 29 September 2023

Authors' Contribution

Conceptualization; FA., Experimental work; RT, Acquisition of data; RT, TRS, Analysis, interpretation of data and original draft preparation; FA., Review and editing; RT and FA. All authors have seen and approved the manuscript.

Key words

Acacia honey, Excisional wound, Free radicals, Wound healing, N-Acetylcysteine

INTRODUCTION

Skin injury results in wound caused by tissue damage after contact with hot object, flame, electrical, chemicals or radiation (Friedstat *et al.*, 2017). Wound healing is a complex biological cascade of cellular and biochemical events comprised of inflammation, proliferation, and maturation phases (Wang *et al.*, 2018). Despite the recent advances in health, the skin injury is still a major public health problem in the world, especially in the developing countries. This fact is due to inadequate wound management and the development of secondary infections at wound site (Atkin, 2019). Many different strategies including use of topical antimicrobial ointments are

used presently to reduce the infection at wound site. However, antimicrobial ointments have some side effects or are partially effective in healing the wound (Punjataewakupt *et al.*, 2019). In order to improve the wound healing, an alternative method based on natural products have great potential and is preferred over modern therapy due to the low cost, limited side effects, bioavailability, and efficacy (Ali *et al.*, 2021; Medellin-Luna *et al.*, 2019; Al-Waili *et al.*, 2011). Honey is one of the natural products of interest that has attracted the attention of many researchers due to its medicinal properties. Many ancient civilizations have been using honey for medicinal purpose (Yilmaz and Aygin, 2020; Henry *et al.*, 2019). Medicinal properties of honey are due to its anti-inflammatory effect, stimulatory effects, antibacterial activity, and antioxidant activity. All these factors contribute to enhance wound healing (Nizet *et al.*, 2020). Researchers and modern practitioners are interested in rapid wound healing and for this reasons they are interested to use honey as wound dressing. Iftikhar *et al.* (2010) reported that Acacia honey depending on their source differ substantially in their activity.

Impaired wound healing is multifactorial, dysfunctional angiogenesis, production of reactive oxygen

* Corresponding author: fatima.ali@imbb.uol.edu.pk
030-9923/2023/0006-2557 \$ 9.00/0



Copyright 2023 by the authors. Licensee Zoological Society of Pakistan.

This article is an open access article distributed under the terms and conditions of the Creative Commons Attribution (CC BY) license (<https://creativecommons.org/licenses/by/4.0/>).

species (ROS), delay in proliferation and migration of bone marrow-derived stem and progenitor cells at the site of injury are assumed to be primary contributing factors. Several important growth factors like insulin-like growth factor-1 (IGF-1) and vascular endothelial growth factor (VEGF) promote angiogenesis at injury site. IGF-1 has been shown to increase angiogenesis through an increase in hypoxia-inducible factor 1- α (HIF-1 α) and VEGF dependent mechanisms (Morbidegli *et al.*, 2021). In this study we focused on to evaluate the role of these growth factors in angiogenesis. Moreover, effect of honey and NAC on mobilization and proliferation of stem cells at the site of injury and their role in wound healing were also evaluated.

During healing process, ROS are produced by inflammatory cells such as neutrophils, macrophages, endothelial cells and fibroblasts causing delay in healing (Forrester *et al.*, 2018). Hence it is hypothesized that antioxidant treatment can reduce free oxygen radicals that further enhance the wound healing. Glutathione (GSH) is an important antioxidant that helps in repairing damage resulting from ROS (Forrester *et al.*, 2018). N-acetylcysteine (NAC) is an antioxidant sulfhydryl substance, which is involved in the formation of GSH in the body (Kurutas, 2016). NAC is administered in both oral and injectable forms. To enhance the effectiveness of Acacia honey it is mixed with antioxidant (NAC). In this study, main objectives were to investigate healing efficacy of Acacia honey in combination with NAC for the treatment of excisional wounds in rats.

MATERIALS AND METHODS

Experimental animals

The experiments on animals were performed in accordance with the guidelines on the Care and Use of Laboratory Animals specified by the Institutional Review Committee of the University of Lahore vide Approval letter No. IMBB/UOL/21/1035.

Male adult Sprague-Dawley rats (280 \pm 20g) were maintained under the controlled environment in the Institute's animal house at 25 \pm 1 $^{\circ}$ C and 12-hour light/dark cycle and were provided with rat chow and water *ad libitum*.

Acid burn experimental model

Rats were anesthetized by ketamine and xylazine injection (30 mg/kg) intraperitoneally, their hair on the back were shaved. A sterile filter paper of 0.5 cm² was soaked in 12.06 N HCl for one minute and applied at the dorsolateral side of the neck for one minute. Thereafter, wound excision was performed and then washed with

normal saline for 30 sec at a flow of 50 ml/min. To avoid infection, wound was covered with paraffin gauze and bandage.

Before creation of acid burn injury, rats were weighed and anesthetized by intramuscular injection of 75 mg/kg ketamine and 15 mg/kg xylazine. The dorsum of the sedated animals was shaved with an electric clippers and depilated with Veet cream to create uniform area. Acid burn injuries were created by exposing the dorsum of rats with sterile filter paper (1.5 cm in diameter) saturated with 12.06 N for a period of one minute. Thereafter, acid burned skin was marked, lifted and cut carefully at the same time. Once the wounds were created on the right side, the animal was turned over onto its left side and the procedure was repeated. One wound was created on each side for a total of two wounds on the rat. All procedures involving animals and their care were conducted in conformity with institutional guidelines.

Physicochemical and microbiological analysis of honey

Commercially available Acacia honey of certified quality was purchased from Langnese Honig GmbH and Co (Germany). The taste and pH values of honey sample were also determined.

The sterility of the honey sample was determined upon observations and assays made on it. The jar was observed for seal intactness, any damage, cap bulging or cracks on the bottle. Honey was observed for any changes in color, odor, homogeneity etc. The sample was assessed for the presence of microbes using the methods as described by Sereia *et al.* (2017).

Preparation of honey and NAC wound dressing

To use honey as wound dressing, honey sample was sterilized by gamma-irradiation (25kGy). Then honey was kept at room temperature protected from sunlight by covering glass bottle in aluminum foil. Then honey and NAC wound dressing was prepared in following way:

1% NAC (Santa Cruz Biotechnology, USA) was prepared by dissolving 1 g NAC in 100 g of honey. Whereas 3% and 5% NAC was prepared by dissolving 3 g and 5 g NAC in 100 g of honey, respectively. NAC was not easily dissolved in honey so for proper mixing honey and NAC were heated in hot boiling water until NAC dissolved completely.

Experimental procedure

After 24 h of wound creation rats were randomly divided into five experimental groups with five animals per group. The duration of protocol was 14 days. The groups were assigned as follows:

Group 1 (Sham group) received acid burn injury but

had no treatment act as a control group.

Group 2 (Honey group) a thin layer of pure honey was topically applied to the wound and then covered with plain gauze.

Group 3 (Honey+1% NAC group) a thin layer of honey and 1% NAC mixture was topically applied to the wound then covered with plain gauze.

Group 4 (Honey+3% NAC group) a thin layer of honey and 3% NAC mixture was topically applied to the wound then covered with plain gauze.

Group 5 (Honey+5% NAC group) a thin layer of honey and 5% NAC mixture was topically applied to the wound and then covered with plain gauze.

Gross examination of wound

Wound area was examined on days 3, 7, 10 and 14 by standards as follows: after injury. The wounds were examined for wound bed, color, exudates, swelling of the wound surface, and the consistency of tissues surrounding the wound. Photographs were taken and analyzed.

Assessment of wound healing

On days 3, 7, 10 and 14 after acid burn injury, wound size was measured by giving anesthesia to rats. The wound margin was traced by using transparent paper and the respective area was measured using a graph paper. Thereafter, color photographs of the wounds were taken by digital camera. The degree of wound healing was calculated by using the following formula:

Percent wound contraction = $[\text{Healed area (cm}^2\text{)}/\text{Total wound area (cm}^2\text{)}] \times 100$,

(Healed area = original wound area – present wound area)

Histological analysis

Rats from each group were slaughtered on day 14 of treatments. A control group was included at this stage to compare the skin histology. Then wound tissue specimens (wound bed) from all experimental groups were removed carefully and fixed in 10% formalin immediately for histological process. After tissue processing 5 μm thick sections were cut and stained with hematoxylin and eosin. Histological section slides were then assessed for histological features (fibroblast proliferation, collagen formation, angiogenesis, granulation, and epithelialization) under light microscope (Olympus CKX53).

Hydroxyproline assay

On day 14 post-wound induction, a piece of skin from the healed wound area was collected and analyzed for its hydroxyproline content. Hydroxyproline assay was performed by weighing 250 mg of wet tissue, then dried at

50°C for 24 h. Dried tissue (40 mg) was used to perform hydroxyproline assay. The assay was performed following the previously published protocol by [Ali et al. \(2021\)](#).

Reverse transcriptase polymerase chain reaction (RT-PCR)

Total RNA was extracted from healed skin area by using TRIZOL reagent (Invitrogen, USA). cDNA was synthesized using total RNA by Revert Aid H Minus first strand cDNA synthesis kit (Thermofisher Scientific, USA) according to the manufacturer's instructions. Gene expression analysis of *VEGF*, *IGF*, *PCNA*, *HIF-1*, *p53*, *CXCR-4*, *SDF-1* and β -Actin was analyzed by PCR amplification.

Following PCR conditions were used: 1 cycle at 94°C for 4 min: 35 cycles at (94°C for 45 s, annealing temp for 45 s and 72°C for 60 s) and 1 extended cycle at 72°C for 10 min. The PCR products were size-fractionated by 2% agarose gel electrophoresis. β -Actin was used as an internal control, and bands were quantified by using ImageJ. The oligonucleotide sequences specific for the selected genes are presented in [Table I](#).

Table I. Primer sequences and product size.

Gene	Primer sequence	Size (bp)
β -Actin	F 5'-GCTGTGTTGTCCTGTATGC-3' R 5'-GAGCGCGTAACCCTCATAGA-3'	102
PCNA	F 5'-TGACCCTCACCGATAACA-3' R 5'-CTGTACAGCACAGCCACGTT-3'	123
HIF-1	F 5'-CTAGGGATGCAGCAGCATCT-3' R 5'-AGATGGGAGCTCACGTTGTG-3'	100
P53	F 5'TTGGATCCATGTTTTGCCAACTGGCC3' R 5'TTGAATTCAGGCTCCCCTTTCTTGCG3'	120
SDF-1	F 5'AGCCAGTCAGCCTGAGCTAC3' R 5'GGCACAGTTTGGAGTGTGA3'	104
CXCR-4	F 5'GCCATGGCTGACTGGTACTT3' R 5'GAAGGCCAGGATGAGAACAC3'	104
IGF-1	F 5'GCTGAAGCCGTTTCATTTAGC3' R 5'CCACCCAGTTGCTATTGCTT3'	193
VEGF	F 5'GCCCTGAGTCAAGAGGACAG3' R 5'GAGGAGGAGGAGCCATTACC3'	284

Indirect enzyme-linked immunoassay (ELISA)

Healed skin tissue was separated, after 14 days of treatment and then tissue homogenates were prepared ultrasonic cell disruptor and radioimmunoprecipitation assay buffer (RIPA) buffer (Sigma-Aldrich, St. Louise, MO, USA). Then the lysates were centrifuged at 12,000

rpm for 15 min at 4°C, and the supernatant was collected. The concentrations of protein were determined by a standard Bradford protein assay. By using this homogenate, Indirect ELISA was performed to detect the levels of IGF, VEGF, SDF, CXCR-4, and β -actin. A micro-titer plate (Corning, USA) was coated with 100 μ l of primary antibodies (VEGF; sc-57496; dilution 1:200), (IGF-1; sc-9013; dilution 1:200), (SDF-1; sc-28876; dilution 1:200), (CXCR-4; sc-9046; dilution 1:200), and (β -actin; sc-47778; dilution 1:200) (Santa Cruz Biotechnology, Inc, UK) and incubated overnight at 4°C. After washing thrice with Tris buffered saline (TBS), the excess antibody was washed off and 100 μ l of HRP-conjugated secondary antibodies (anti-mouse antibody for VEGF and β -actin antibody; sc-2371; dilution 1:1000), and anti-rabbit antibody for IGF-1, CXCR-4; sc-2357; dilution 1:1000) (Santa Cruz Biotechnology, Inc, UK) were added. After washing, equal volume of chromogenic solution 3, 3', 5, 5'-tetramethylbenzidine (TMB) (Invitrogen Inc., USA) and 0.1 mM HCl were added to stop the reaction. Using a micro-titer plate reader, absorbance was taken at a wavelength of 450 nm along with 650 nm as a reference value.

Estimation of GSH and catalase activity

The reduced glutathione (GSH), and catalase (CAT) activity from tissue homogenate was estimated according to Ali *et al.* (2017).

Statistical analysis

All experiments were performed in triplicates. Statistical tests and graphical representations were performed by using GraphPad Prism 5 software (GraphPad, San Diego, Ca, USA). Data are presented as mean \pm standard deviation. One-way ANOVA (Analysis of Variance) was performed for comparison between different groups. The statistical significance was set at $p \leq 0.05$.

RESULTS

Honey analysis

Biochemical analysis of *Acacia* honey sample showed that honey had pH 3.42 ± 2.45 . No bacterial growth was detected in honey sample after microbiological analysis which shows it's safe to apply on wound.

Wound healing examination

Morphology examination of wounds before and after treatment show that on day 14, that is the last day of the experiment, honey+3% NAC group showed a marked reduction in size and continuous hair growth at the wound site compared to other group (Fig. 1).

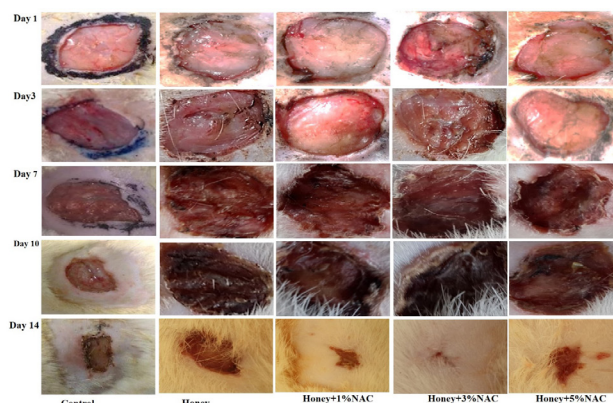


Fig. 1. Effect of *Acacia* honey and N-Acetylcysteine on wound healing process on day 0, 3, 7, 9, and 14.

Histological findings indicated a progressive improvement in wound healing at day 14. The honey +3% NAC group showed significant wound healing with completed re-epithelialization of epidermis shown in Figure 2.

Detailed histological analysis of slides from all treatment groups are mentioned in Table II. The slides were examined for presence of inflammatory cells, angiogenesis, granulation tissue, epithelialization, presence of fibroblast, and collagen deposition.

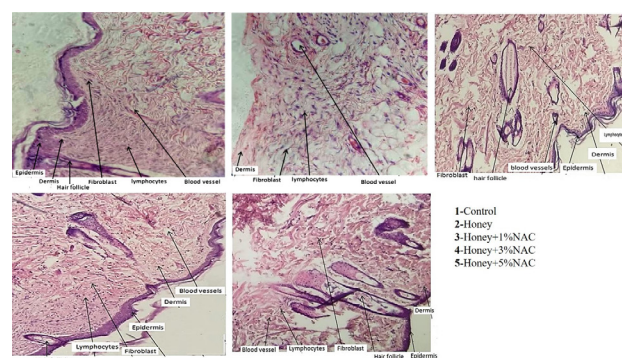


Fig. 2. Effect of *Acacia* honey and N-Acetylcysteine on histological structure of skin during wound healing process in Sprague Dawley rats. Stain: hematoxylin-eosin. Magnification: $\times 20$.

Wound contraction

Following wound induction and treatment with honey and NAC, the wound size decreased. On day 14, the treated wounds size was almost closer to that of honey group as shown in Table III. The decrease in wound size that indicated faster healing was significant compared to honey group ($p \leq 0.05$). The 5% NAC treated group showed slower

Table II. Comparison of histological parameters for the assessment of wound healing in different groups on day 14.

Parameters	Control	Honey	Honey+1%NAC	Honey+3%NAC	Honey+5%NAC
Epidermis	Present	Partially present	Present	Present	Present
Dermis	Present	Present	Present	Present	Present
Granulation tissue	Thick and mature	Immature thin	Moderate mature	Thick mature	Moderate mature
Lymphocytes	Many	Few	Many	Many	Many
Neutrophils	None	None	None	None	None
Fibroblast	Many	Few	Moderate	Many	Many
Hair follicle	Present	Not present	Present	Present	Present

Table III. Wound contraction (%) after treatment with honey+NAC. Values are mean \pm SEM. ^a $P < 0.05$, ^b $P < 0.01$, and ^c $P < 0.001$ compared to respective day control (honey) group.

Treatment groups	n	Degree of wound healing (%)			
		Day 3	Day 7	Day 9	Day 14
Honey group	9	12.36 \pm 0.57	31.83 \pm 1.11	51.96 \pm 0.35	83.88 \pm 2.51
Honey+1%NAC	9	17.43 \pm 1.12 ^b	37.42 \pm 0.97 ^a	60.90 \pm 1.11 ^b	90.48 \pm 0.66
Honey+3%NAC	9	18.78 \pm 0.32 ^b	42.33 \pm 0.48 ^c	68.44 \pm 0.77 ^b	95.14 \pm 0.93 ^b
Honey+5%NAC	9	16.01 \pm 0.80	37.19 \pm 1.55	58.76 \pm 0.55 ^c	88.72 \pm 1.55

contraction rate from 16.01% on day 3 to 88.72% on day 14 whereas the 3% NAC treated group show faster contraction rate from 18.78% NAC on day 3 to 95.14% on day 14. The contraction rate was significant compared to honey control group ($p \leq 0.05$).

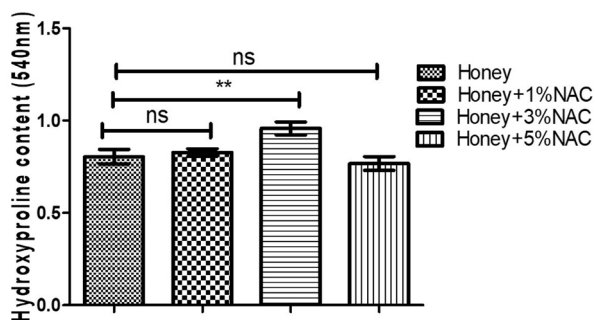


Fig. 3. Effect of honey + NAC on hydroxyproline content in wound area of skin of rats. Values are presented as mean \pm S.E.M; n = 9; ^a $P < 0.05$, ^b $P < 0.01$, and ^c $P < 0.001$ compared to respective day control (honey) group.

Hydroxyproline content

The hydroxyproline content of the skin tissue after 14 days is given in Figure 3. A significant increase in hydroxyproline content was observed in honey+3% NAC group than control group. Hydroxyproline content was low in honey group (0.805 \pm 0.022 nm), honey+1% NAC group

(0.828 \pm 0.011 nm) and honey+5% NAC (0.768 \pm 0.021 nm) as compared to honey+3% NAC group (0.925 \pm 0.020 nm). Hydroxyproline is a good marker for wound healing.

GSH content and catalase enzyme

Biochemical analysis of skin for GSH and catalase shows that the honey+3% NAC group improved the GSH and catalase status after injury. GSH levels were less (Fig. 4A) in honey group (1.293 \pm 0.04 nm), honey+1% NAC group (1.625 \pm 0.02 nm) and honey+5% NAC group (1.468 \pm 0.04 nm), compared to honey+3%NAC group (1.824 \pm 0.03 nm).

The level of catalase on the other hand decreased in honey group (0.035 \pm 0.00 nm), honey+1% NAC group (0.055 \pm 0.00 nm) and honey+5% NAC group (0.055 \pm 0.00 nm), respectively compared to honey+3% NAC group (0.063 \pm 0.00 nm) (Fig. 4B).

Gene expression during wound healing

PCR results revealed that the expression of PCNA is high in honey+3% NAC group as compared to other groups. Expression of apoptotic markers such as P53 was significantly down-regulated in honey+3% NAC group. Oxidative stress increases the HIF 1 α expression in honey group as compared to honey+3% NAC group. Similarly, IGF-1 and VEGF expression is high in honey+3% NAC group compared to honey group. SDF-1 and CXCR-4 expression is up-regulated in honey+3% NAC group

compared to other groups (Fig. 5).

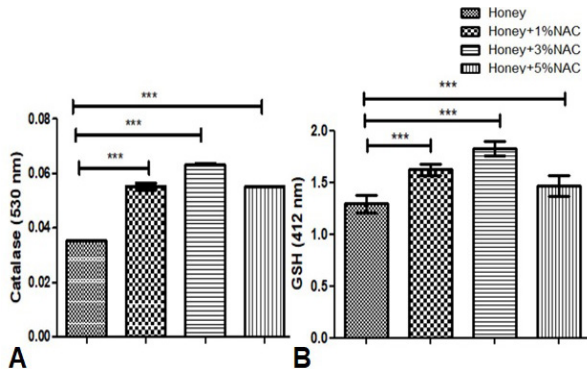


Fig. 4. Effect of hony + NAC on Catalase (A) and GSH (B) in skin of rats. Values are presented as mean ± S.E.M; n = 9; * $P < 0.05$, ** $P < 0.01$, and *** $P < 0.001$ compared to respective day control (honey) group.

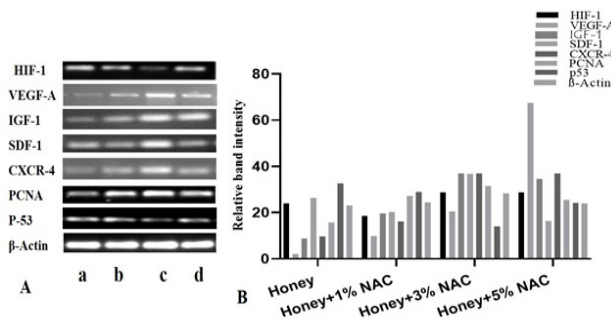


Fig. 5. (A) Effect of hony + NAC on gene expression profiling of treatment groups with PCR. (a) Honey group; (b) Honey+1% NAC group; (c) Honey+3% NAC group; (d) Honey+3% NAC group. (B) Gel band quantification by Image J.

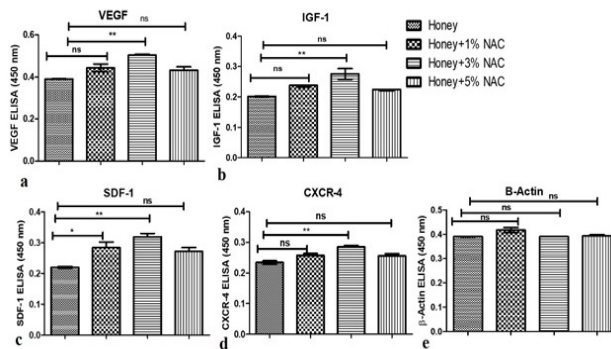


Fig. 6. Effect of hony + NAC on results of indirect ELISA for VEGF, IGF, SDF-1, CXCR-4 from skin proteins. Values are presented as mean ± S.E.M; n = 9; * $P < 0.05$, ** $P < 0.01$, and *** $P < 0.001$ compared to respective day control (honey) group. ns mean non-significant.

ELISA analysis

The level of VEGF, IGF-1, SDF-1 and CXCR-4, β-actin proteins from skin of each group was determined by ELISA. Levels of VEGF, IGF-1, SDF-1 and CXCR-4 in Figure 6. Results show that the growth factor VEGF, IGF-1 levels was positively increased in honey+3% NAC group compared to the honey group. Similarly, the level of SDF-1 and CXCR-4 increased in honey+3% NAC group when compared to the honey group.

DISCUSSION

The clinical findings of the earlier clinical trials of honey as wound dressing for burn management in human (Jull *et al.*, 2015) and animals (Sarraf *et al.*, 2019; Sawazaki *et al.*, 2018) was the motivation to carry out the current study. Therefore, the present study evaluated the effect of honey in combination with antioxidant NAC on the wound healing process. The present study demonstrated that honey+3% NAC treatment improved wound healing. Burn area decreased significantly in honey+3% NAC treated group. Our results showed that topical application of honey+3%NAC treated group was effective towards the treatment of excisional wound when compared to honey group and other combinational groups. Wound healing results shows that synergistic interaction between honey and NAC together is greater than individual honey. Microscopic and macroscopic findings indicated that treatment of wound with honey+3% NAC resulted in regeneration of epidermis and accelerated the wound healing time compared to the honey treated group. This is similar to the findings reported by many researchers relevant to efficacy of topical application of honey in wound management (Sarraf *et al.*, 2019; Sawazaki *et al.*, 2018; Tan *et al.*, 2012). Improvement in wound healing is due to synergistic properties of both honey and NAC. As hydrogen peroxide production, hydrosopic, antioxidant, and antibacterial characteristic of honey added with antioxidative ability of NAC provide suitable environment for healing process (Henry *et al.*, 2019; Galal *et al.*, 2019; Tan *et al.*, 2012).

The efficiency of the topical application of honey on wounds has been reported by many researchers (Jull *et al.*, 2015; Sarraf *et al.*, 2019; Sawazaki *et al.*, 2018). Result of hydroxyproline show, increase hydroxyproline level in honey+3% NAC treated animals compared to the control. Hydroxyproline is associated with collagen content of the granulation tissue. In the newly formed granulation tissue fibroblasts are responsible for the synthesis of collagen, so one would expect that any increase in fibroblasts proliferation would results in an increase in collagen synthesis (Rodrigues *et al.*, 2019; Yaghoobi *et al.*, 2013).

Beside other nutritional properties honey contains glycine, methionine, arginine, and proline amino acids which are important for collagen formation and deposition (Lusby *et al.*, 2002; Gupta *et al.*, 1992).

Antioxidant enzymes are essential part of the cellular defense against ROS. The activities of antioxidant enzymes such as CAT (scavenges hydrogen peroxide to form water and oxygen), and GSH (directly binding to oxidative compounds) were reduced in honey group (He *et al.*, 2017). The reduced activities of these two main antioxidant enzymes improved in honey in combination with NAC group, this may be attributed to synergistic effect of honey and NAC.

Angiogenesis plays a pivotal role in tissue regeneration and wound repair, VEGF and IGF both growth factor has significant role in vasculogenesis and angiogenesis (Apte *et al.*, 2019; Lin *et al.*, 2017). Result of ELISA and RT-PCR show that honey+3% NAC treatment has beneficial effect on VEGF, and IGF-1. The expression of growth factor proteins such as VEGF and IGF-1 indicate the initiation of angiogenesis. Recent evidence demonstrates that the chemokine stromal-cell derived factor-1 (SDF-1) has a major role in the recruitment and retention of CXCR4+ bone marrow cells toward injury site that would enhance the revascularization of tissue (Cun *et al.*, 2021). ELISA and RT-PCR results show that the honey+3% NAC group show high expression for SDF-1 and CXCR-4 which indicated that wound healing is due to migration of stem cells at the site of injury wherein the migrated cell will proliferate to develop the new tissue. Cell proliferation potential was determined by Proliferating cell nuclear antigen (PCNA) (Lu *et al.*, 2019). RT-PCR results indicated a high expression of PCNA in the honey+3% NAC group compared with the honey group. These findings highlight the efficacy of honey in wound healing are in agreement with the previous studies which describe that honey has hydrogen peroxide production, hydroscopic, antioxidant, and antibacterial characteristic (Henry *et al.*, 2019; Galal *et al.*, 2019; Tan *et al.*, 2012).

CONCLUSION

In conclusion, the present study illustrates the wound healing property of Acacia honey in combination with NAC. This combination is shown to stimulate wound healing by promoting fibroblast function, enhance angiogenesis and deposition of collagen. It also increases the rate of wound contraction and epithelialization without affecting animal health. Treatment also show the chemo-taxis of stem, cells toward injury place which further accelerate healing. This study clearly demonstrates that the combined treatment of honey with NAC is useful adjuvant in wound management.

ACKNOWLEDGMENTS

This study was financially supported by Higher Education Commission (HEC) of Pakistan under NRP Project (7517/Punjab/NRP/R and D/HEC/2017).

Statement conflict of interest

The authors have declared no conflict of interest.

REFERENCES

- Ali, F., Aziz, F., and Wajid, N., 2017. Effect of type 2 diabetic serum on the behavior of Wharton's jelly-derived mesenchymal stem cells *in vitro*. *Chronic Dis. Transl. Med.*, **3**: 105–111. <https://doi.org/10.1016/j.cdtm.2017.02.006>
- Ali, F., Wajid, N., Sarwar, M.G., and Qazi, A.M., 2021. Oral administration of *Aloe vera* ameliorates wound healing through improved angiogenesis and chemotaxis in sprague dawley rats. *Curr. Pharm. Biotechnol.*, **22**: 1122–1128. <https://doi.org/10.2174/1389201021999201001204345>
- Al-Waili, N., Salom, K., and Al-Ghamdi, A.A., 2011. Honey for wound healing, ulcers, and burns; data supporting its use in clinical practice. *Sci. World J.*, **11**: 766–787. <https://doi.org/10.1100/tsw.2011.78>
- Apte, R.S., Chen, D.S., and Ferrara, N., 2019. VEGF in signaling and disease: Beyond discovery and development. *Cell*, **176**: 1248–1264. <https://doi.org/10.1016/j.cell.2019.01.021>
- Atkin L., 2019. Chronic wounds: The challenges of appropriate management. *Br. J. Commun. Nurs.*, **24**: S26–S32. <https://doi.org/10.12968/bjcn.2019.24.Sup9.S26>
- Cun, Y., Diao, B., Zhang, Z., Wang, G., Yu, J., Ma, L., and Rao, Z., 2021. Role of the stromal cell derived factor-1 in the biological functions of endothelial progenitor cells and its underlying mechanisms. *Exp. Ther. Med.*, **21**: 39. <https://doi.org/10.3892/etm.2020.9471>
- Forrester, S.J., Kikuchi, D.S., Hernandez, M.S., Xu, Q., and Griendling, K.K., 2018. Reactive oxygen species in metabolic and inflammatory signaling. *Circ. Res.*, **122**: 877–902. <https://doi.org/10.1161/CIRCRESAHA.117.311401>
- Friedstat, J., Brown, D.A., and Levi, B., 2017. Chemical, electrical, and radiation injuries. *Clin. Plast. Surg.*, **44**: 657–669. <https://doi.org/10.1016/j.cps.2017.02.021>
- Galal, A., Ramadan, R.A., Metwally, M., and El-Sheikh, S., 2019. Protective effect of N-acetylcysteine on

- fenitrothion-induced toxicity: The antioxidant status and metabolizing enzymes expression in rats. *Ecotoxicol. environ. Saf.*, **171**: 502–510. <https://doi.org/10.1016/j.ecoenv.2019.01.004>
- Gupta, S.K., Singh, H., Varshney, A.C., and Prakash, P., 1992. Therapeutic efficacy of honey in infected wounds in buffaloes. *Indian J. Anim. Sci.*, **62**: 521–523.
- He, L., He, T., Farrar, S., Ji, L., Liu, T., and Ma, X., 2017. Antioxidants maintain cellular redox homeostasis by elimination of reactive oxygen species. *Cell. Physiol. Biochem. Int. J. Exp. Cell. Physiol. Biochem. Pharmacol.*, **44**: 532–553. <https://doi.org/10.1159/000485089>
- Henry, N., Jeffery, S., and Radotra, I., 2019. Properties and use of a honey dressing and gel in wound management. *Br. J. Nurs.*, **28**: S30–S35. <https://doi.org/10.12968/bjon.2019.28.6.S30>
- Iftikhar, F., Arshad, M., Rasheed, F., Amraiz, D., Anwar, P., and Gulfraz, M., 2010. Effects of acacia honey on wound healing in various rat models. *Phytother. Res.*, **24**: 583–586. <https://doi.org/10.1002/ptr.2990>
- Jull, A.B., Cullum, N., Dumville, J.C., Westby, M.J., Deshpande, S., and Walker, N., 2015. Honey as a topical treatment for wounds. *Cochrane Database Syst. Rev.*, **3**: CD005083. <https://doi.org/10.1002/14651858.CD005083.pub4>
- Kurutas, E.B., 2016. The importance of antioxidants which play the role in cellular response against oxidative/nitrosative stress: Current state. *Nutr. J.*, **15**: 71. <https://doi.org/10.1186/s12937-016-0186-5>
- Lin, S., Zhang, Q., Shao, X., Zhang, T., Xue, C., Shi, S., Zhao, D., and Lin, Y., 2017. IGF-1 promotes angiogenesis in endothelial cells/adipose-derived stem cells co-culture system with activation of PI3K/Akt signal pathway. *Cell Prolif.*, **50**: e12390. <https://doi.org/10.1111/cpr.12390>
- Lu, E.M., Ratnayake, J., and Rich, A.M., 2019. Assessment of proliferating cell nuclear antigen (PCNA) expression at the invading front of oral squamous cell carcinoma. *BMC Oral Hlth.*, **19**: 233. <https://doi.org/10.1186/s12903-019-0928-9>
- Lusby, P.E., Coombes, A., and Wilkinson, J.M., 2002. Honey: a potent agent for wound healing? *J. Wound Ostomy, Continence Nurs.*, **29**: 295–300. <https://doi.org/10.1067/mjw.2002.129073>
- Medellín-Luna, M.F., Castañeda-Delgado, J.E., Martínez-Balderas, V.Y., and Cervantes-Villagrana, A.R., 2019. Medicinal plant extracts and their use as wound closure inducing agents. *J. med. Fd.*, **22**: 435–443. <https://doi.org/10.1089/jmf.2018.0145>
- Morbideilli, L., Genah, S., and Cialdai, F., 2021. Effect of microgravity on endothelial cell function, angiogenesis, and vessel remodeling during wound healing. *Front. Bioeng. Biotechnol.*, **9**: 720091. <https://doi.org/10.3389/fbioe.2021.720091>
- Nizet, O., Camby, S., and Nizet, J.L., 2020. Utilisation des pansements à base de miel dans le traitement des plaies use of honey dressings in wound healing. *Rev. Med. Liege*, **75**: 797–801.
- Punjataewakupt, A., Napavichayanun, S., and Aramwit, P., 2019. The downside of antimicrobial agents for wound healing. *Eur. J. clin. Microbial. Infect. Dis.*, **38**: 39–54. <https://doi.org/10.1007/s10096-018-3393-5>
- Rodrigues, M., Kosaric, N., Bonham, C.A., and Gurtner, G.C., 2019. Wound healing: A cellular perspective. *Physiol. Rev.*, **99**: 665–706. <https://doi.org/10.1152/physrev.00067.2017>
- Sarraf, D.P., Jaisani, M.R., Dongol, A., Shrestha, A., and Rauniar, G.P., 2019. Effect of honey on healing process of extraction socket in rabbits. *Kathmandu Univ. med. J.*, **17**: 287–292.
- Sawazaki, T., Nakajima, Y., Urai, T., Mukai, K., Ohta, M., Kato, I., Kawaguchi, A., Kinoshita, Y., Kumagai, Y., Sakashita, A., Yamazaki, A., and Nakatani, T., 2018. Efficacy of honeydew honey and blossom honey on full-thickness wound healing in mice. *Wounds Compend. clin. Res. Pract.*, **30**: 197–204.
- Sereia, M.J., Perdoncini, M.R.F.G., Março, P.H., Parpinelli, R.S., de Lima, E.G., and Anjo, F.A., 2017. *Techniques for the evaluation of microbiological quality in honey: Honey analysis*. Vagner de Alencar Arnaut de Toledo, Intech Open. <https://doi.org/10.5772/67086>
- Tan, M.K., Hasan, A.D.S., Tumiran, M.A., Abdulla, M.A., and Yusoff, K.M., 2012. The efficacy of gelam honey dressing towards excisional wound healing. *Evid. Based Complement. Altern. Med.*, **2012**: 805932. <https://doi.org/10.1155/2012/805932>
- Wang, P.H., Huang, B.S., Horng, H.C., Yeh, C.C., and Chen, Y.J., 2018. Wound healing. *J. Chinese med. Assoc.*, **81**: 94–101. <https://doi.org/10.1016/j.jcma.2017.11.002>
- Yaghoobi, R., Kazerouni, A., and Kazerouni, O., 2013. Evidence for clinical use of honey in wound healing as an anti-bacterial, anti-inflammatory antioxidant and anti-viral agent: A review. *Jundishapur J. Natl. Pharm. Prod.*, **8**: 100–104. <https://doi.org/10.17795/jjnpp-9487>
- Yilmaz, A.C., and Aygin, D., 2020. Honey dressing in wound treatment: A Systematic review. *Complement. Ther. Med.*, **51**: 102388. <https://doi.org/10.1016/j.ctim.2020.102388>