



Research Article

Haematological and Histopathological Analyses of Levofloxacin Induced Toxicity in Mammals

Chaman Ara^{1*}, Asmatullah¹, Sehrish Kanwal¹, Asma Chaudhary², Ayesha Siddiqua¹

²Department of Zoology, Faculty of Life Sciences, University of the Punjab, Lahore, Pakistan

²Department of Zoology, University of Education, Lahore, Pakistan

Article History

Received: October 04, 2019

Revised: November 05, 2019

Accepted: January 08, 2020

Published: January 10, 2020

Authors' Contributions

CA and Asmatullah conceived, executed and supervised the study. CA wrote the manuscript. SK and AS conducted the experiments.

Keywords

Levofloxacin, Histopathology, Haematology

Abstract | Levofloxacin (LFX), a broad spectrum fluoroquinolone antibiotic of third generation, is widely used to treat respiratory and genitourinary infections. Keeping in view the controversy about its toxicity, current study was conducted to assess the levofloxacin induced hepatotoxicity, nephrotoxicity and its likely noxious effects on spermatogenesis in mammals. Forty mice, randomly categorized into four groups (N=10) were administered orally with different concentrations of levofloxacin (0.00, 9.37, 18.75 and 37.50 µg/g BW of mice) for 30 days consecutively. Mice were sacrificed on 31st day (24 hours after last dose administered) under deep chloroform anaesthesia. Blood was extracted through cardiac puncture and viscera were dissected out for further analysis. Levofloxacin induced reduction in body weight while caused a noticeable increase in liver, kidney and testis weights. Significant increase in levels of total alkaline aminotransferase (ALT), aspartate transaminase (AST), alkaline phosphatase (ALP) and bilirubin was observed in blood plasma. Urea level showed a remarkable decrease, whereas creatinine level increased but not significantly. Histological examinations exhibited pyknosis, necrosis, vacuolations, increased sinusoidal spaces, karyomegaly, glomerulosclerosis, glomerulonephritis, epithelium degeneration, spermatocytes exfoliation, tubular degeneration and aspermia in liver, kidney and testis respectively. Levofloxacin causes deleterious effects on liver, kidneys and testes of mice and alters normal functioning of vital organs.

Novelty Statement | The research highlighted safe and toxic dose limits of Levofloxacin, (a broad spectrum antibiotic) on repeated exposure to mammals

To cite this article: Ara, C., Asmatullah, Kanwal, S., Chaudhary, A. and Siddiqua, A., 2020. Haematological and histopathological analyses of levofloxacin induced toxicity in mammals. *Punjab Univ. J. Zool.*, 35(1): 01-06. <https://dx.doi.org/10.17582/journal.pujz/2020.35.1.01.06>

Introduction

Levofloxacin (LFX), a fluoroquinolone, is a broad spectrum antibiotic which possesses highly assertive antimicrobial activity against Gram-positive as well as Gram-negative bacteria (Al-Soufi and Al-Rekabi, 2019). It also exhibits exceptional proficiency to exterminate pathogens like *Chlamydia* and *Mycoplasma* (Aboubakr and Soliman, 2014). In comparison with other members of the same family, like ciprofloxacin, levofloxacin has much

better efficacy to treat typhoid fever. It is extensively used to treat various infections such as pneumonia, bronchitis, sinusitis and genitourinary infection including both intricate and facile urinary tract infections (Olayinka *et al.*, 2015). The bactericidal action of levofloxacin as well as other fluoroquinolones is primarily achieved by their binding to enzyme DNA gyrase leading to subsequent inhibition of DNA replication and transcription, hence disabling the bacteria to divide (Aboubakr and Soliman, 2014).

Most of the fluoroquinolones are found to be consolidated with some detrimental effects on vital organs of body (Gurbay *et al.*, 2001). They actually produce reactive

Correspondence author: Chaman Ara
dr.chamanara@yahoo.com

oxygen species (ROS) which subsequently causes oxidative stress as well as hepatic and renal cells deterioration (Afolabi and Oyewo, 2014). Generally, the toxicity of levofloxacin in liver results in the formation of free radicals, ruination of mitochondria and lipid peroxidation of membranes (Hincal and Taskin, 1995) or alterations in redox status of glutathione (GSH) (Gurbay *et al.*, 2001). Renal effects of fluoroquinolones include allergic interstitial nephritis, acute tubular necrosis, acute renal failure and crystalluria. Most of these responses are associated with ciprofloxacin, norfloxacin and ofloxacin (Ramalakshmi *et al.*, 2003). With respect to spermatogenic toxicity, levofloxacin induces reduction in sperm count, oligospermia, sperm motility and abnormal sperm morphology (Norra *et al.*, 2003). Chronic exposure to LFX can cause pathological changes such as atrophy in seminiferous tubules, disturbing the regular process of spermatogenesis hence inducing hypo spermatogenesis and infertility in rats (Ahmadi *et al.*, 2016).

The production of reactive oxygen species (ROS) in phagocytic cells (Thuong-Guyot *et al.*, 1994; Yazar and Tras, 2001) and weakening of enzymatic antioxidant defence system in tissues is closely associated with the notorious effects of fluoroquinolones (Kavutcu *et al.*, 1996). Hepatocytes which generally comprise of enzymatic and non-enzymatic antioxidants play role in protection against tissue bruises caused by ROS and free radicals (Rahman, 2007). It has been conceded that various classes of antibiotics produce varying degrees of ROS that subsidize to kill the cells (Albesa *et al.*, 2004; Dwyer *et al.*, 2007). Moreover, getting exposed to elevated level of ROS may result in decline of cellular antioxidant capacity hence exposing the cell to enhanced level of lipid peroxidation and ultimately causing tissue injury (Wagener *et al.*, 2013). Above mentioned studies are usually on other fluoroquinolone family members, our study specifically focuses on levofloxacin toxicity. As this is a multiparametric study, so data authenticity is undoubted. We used various concentrations of LFX to explore which was the safest concentration after subchronic exposure.

Materials and Methods

Animal husbandry

BALB/c strain of Swiss Webster albino mice (5 males, 10 females) was used to raise the colony in the animal house, Department of Zoology, University of the Punjab, Lahore. Where they were kept under well controlled environment, having light and dark cycle of 12 hours, temperature ($27\pm 2^{\circ}\text{C}$) and relative humidity of 40-55%. Breeding collection from this colony was reserved and forty male mice out of this collection were selected to conduct the experiment. They were accommodated in steel cages placed on iron racks, and fed on highly protein rich and vitamin loaded feed pellets which are commercially prepared by National feeds, Lahore, Pakistan. Mice were

provided regular supply of food and water *ad libitum* throughout the experiment.

Dose preparation

Levofloxacin 250mg Film-coated Tablets were supplied by Abbott Laboratories (Pak). 250 mg tablet was dissolved in distilled water in such a way that 0.1ml contained the required dose concentration ($9.37\mu\text{g/g}$, $18.75\mu\text{g/g}$ and $37.50\mu\text{g/g}$ body weight) for mice.

Experimental design and dose administration

Four to five weeks old, forty male mice with mean weight of 27 ± 02 gm were randomly divided into four groups, 10 mice in each group. These groups were entitled as C, D-I, D-II and D-III, orally administered with various doses of levofloxacin ($0.00\mu\text{g/g}$, $9.37\mu\text{g/g}$, $18.75\mu\text{g/g}$ and $37.50\mu\text{g/g}$ BW) respectively, for 30 days routinely. Mice of all experimental groups were weighed unanimously at the start as well as at the end of experiment.

Dissection

Dissection was carried out on 31st day, exact 24hrs after the last treatment, mice were deeply anaesthetized by anaesthetic chloroform. Blood and organ samples were collected for biochemical assay and histological study, respectively. Blood was ejected out from intracardiac puncture, stored in EDTA vials to prevent blood clotting and later on different enzymes were analysed using Randox diagnostic kits, purchased from Randox Laboratories Ltd. Online, following the kit protocols. For histological study, liver, kidneys and testes were excised out, weighed and fixed in Bouine's fixative for about 48 hours and later were subjected to morphometric, morphological and histological examination.

Morphological and morphometric analyses

For morphology and morphometric studies, wet weight of organs, liver, kidney and testis was measured by using digital balance. Then organs were macro photographed using close-up lens fitted camera of Panasonic TZ15 and Microscope Labomed, CZM6, at different magnifications.

Histological preparations of organs

The organs, previously fixed in Bouine's fixative were treated with ascending concentrations of alcohol (70% to 100%) for dehydration. Then organs were cleared with xylene. After this, organs were embedded in paraffin wax and were cut into sections of 5μ thickness by using rotary microtome. Finally, the slides were stained by Eosin-hematoxylin staining method and microphotographed by light microscope, SWIFT MD3500.

For sperm count, the epididymis was excised from testis, and macerated thoroughly in trisodium citrate solution. Then a drop of suspension was shifted to a Neubauer haemocytometer thereby sperm count was assessed (Val and Robledano, 2013).

Table 1: Shows the effect of Levofloxacin on various body parameters, liver and kidney specific enzymes and sperm count in male mice.

Dose groups ^Δ Parameters	Control	Levofloxacin treated groups		
		D-I	D-II	D-III
Body weight (g±SEM)				
Day 1	28.4±0.19	28.58±0.46	29.24±0.30	28.88±0.76
Day 30	32.3±0.19	29.2±0.37	28.96±0.20	27.12±0.66*
Organ weight (mg±SEM)				
Liver	1323±44.57	1260.4±1.76	1244.6±18.70	1496±42.09***
Kidney	402.8±50.23	415.2±7.10	421.8±20.79	449.4±18.48*
Testis	118.6±9.02	123.8±1.81	156.4±8.02*	192.4±15.55**
Liver function test				
Bilirubin (mg/dl)	0.51±0.11	0.49±0.11	0.58±0.21	0.91±0.05*
ALT (U/L)	34±0.57	37±1.15	52±2.88**	77±1.15***
AST (U/L)	47±2.30	51±1.15	68±0.57**	83±1.73***
ALP (U/L)	121±2.88	69±2.08	76±3.00**	91±3.46***
Renal function test				
Urea (mg/dl)	42±1.73	39±1.30	33±1.15*	37±1.15
Creatinine (mg/dl)	0.50±0.17	0.49±0.17	0.56±0.17	0.61±0.17
Sperm count	65×10 ⁶ ±1.22	57×10 ⁶ ±1.14***	39×10 ⁶ ±0.83***	29×10 ⁶ ±1.14***

Δ: For explanation see materials and methods; Asterisks show, $p \leq 0.001 = ***$; $p \leq 0.01 = **$; $p \leq 0.05 = *$.

Statistical analysis

Numerical data collected, tabulated and processed statistically in the form of mean \pm standard error of mean (SEM) using software SPSS version 16 (SPSS Inc., Chicago, IL, USA). One-way analysis of variance (ANOVA) was applied followed by Tukey's test for multiple comparison. Differences were considered significant at $p \leq 0.05$.

Results

Morphological and morphometric observations

Current study observations showed a considerable decrease ($p \leq 0.05$) in the average body weight of levofloxacin treated mice in dose dependent manner relative to control. The weight of liver revealed a significant increase ($p \leq 0.001$) at high concentration of LFX in comparison with control. However, a remarkable increase ($p \leq 0.05$, $p \leq 0.01$) in the mean weight of kidney and testis was observed in dose-wise concentrations (Table 1).

Biochemical analysis

Hepatic and renal function tests

Table 1 shows elevated levels ($p \leq 0.001$, $p \leq 0.01$) of different liver biomarkers like Alanine aminotransferase (ALT), Aspartate Aminotransferase (AST) and Alkaline phosphatase (ALP) in dose dependent concentrations. Whereas bilirubin level exhibited significant increase ($p \leq 0.05$) only at high dose of LFX.

Urea, the biochemical marker for kidney, exhibited significant decrease ($p \leq 0.05$) in levofloxacin treated mice as compared to control. However, creatinine level in serum increased but not significantly (Table 1).

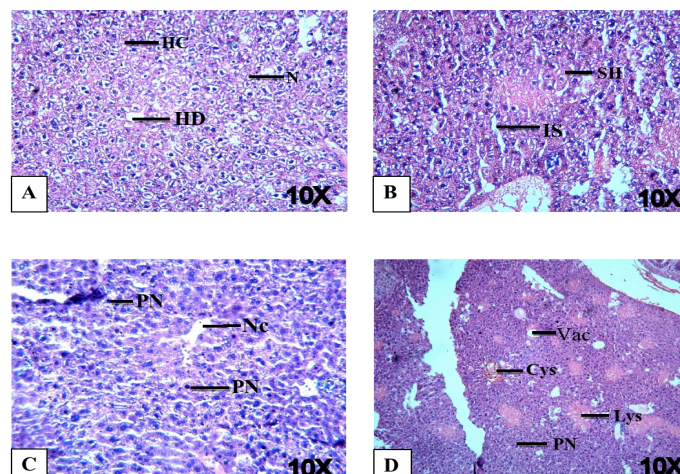


Figure 1: Histopathological examination of liver tissues of LFX exposed mice at 10X magnification. (A) Control mice showing normal structure i.e. HD: Hepatic duct; HC: Hepatocyte; N: nucleus. (B) Mice treated with 9.37 µg/g B.W. of LFX showing IS: increased sinusoidal spaces; SH: swollen hepatocytes. (C) Mice treated with 18.37 µg/g B.W. of LFX exhibiting Nc: necrosis; PN: pyknosis. (D) Mice treated with 37.50 µg/g B.W. of LFX showing showing defects i.e. Vac.: Vacuolation; PN: pyknosis; Lys: Lysed blood cells; Cys: cyst. H and E staining.

Sperm count

Current study exhibited that levofloxacin has adverse effects on testis and epididymis. Number of sperm was reduced significantly ($p \leq 0.001$) in all levofloxacin treated mice in comparison with control group (Table 1).

Histopathological Observations

Histopathology of liver sections from control group

showed normal hepatic features like normal morphology of hepatocytes and sinusoids as well as regular hepatic lobules and hepatic duct. Whereas exposure to various concentrations of levofloxacin caused multiple liver damages such as necrosis, vacuolations, increased sinusoidal spaces, pyknosis, karyomegaly, hypertrophy and hepatic cysts (Figures 1 and 2).

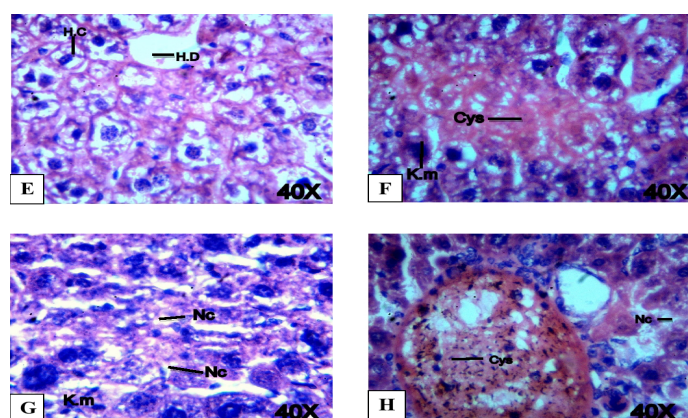


Figure 2: Histopathological examination of liver tissues of LFX exposed mice at 40X magnification. (A) Control mice showing normal structure i.e. HD: Hepatic duct; HC: Hepatocyte. (B) Mice treated with 9.37 µg/g B.W. of LFX showing Cys: cyst; K.m: karyomegaly. (C) Mice treated with 18.37 µg/g B.W. of LFX exhibiting Nc: necrosis; PN: pyknosis. (D) Mice treated with 37.50 µg/g B.W. of LFX showing Cys: cyst; Nc: necrosis' H and E staining.

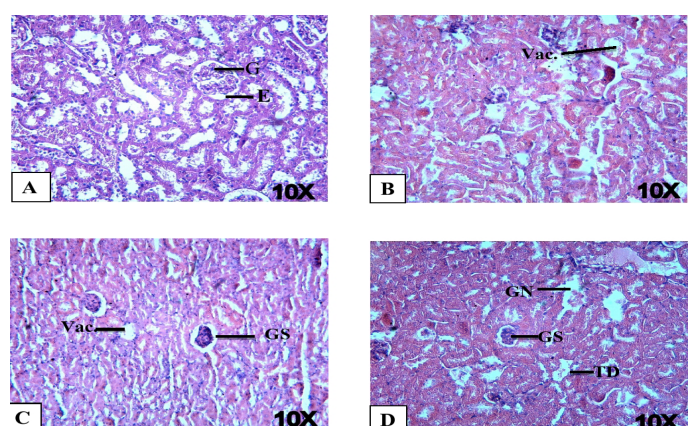


Figure 3: Histopathological examination of mice kidneys with LFX at 10X. (A) Control mice showing normal tissues i.e. G: glomerulus; E: epithelial lining. (B) Mice treated with 9.37 µg/g B.W. of LFX showing Vac.: vacuolation. (C) Mice treated with 18.37 µg/g B.W. of LFX showing GS: glomerulosclerosis; Vac.: vacuolation. (D) Mice treated with 37.50 µg/g B.W. of LFX showing GS: glomerulonephritis; GN: glomerulonephritis; TD: tubular degeneration. Stain H and E.

Sections of kidney from control group exhibited normal structure of Bowman's capsules, glomeruli as well as tubules. Whereas exposure to LFX caused various damages including glomerulosclerosis, glomerulonephritis, epithelium degenerations, tubular degenerations and dilation of tubules (Figure 3).

Histological sections of testis from control group

showed normal histology of testis having lumens of seminiferous tubules filled with Sperm tails and intact interstitial cells. While LFX exposure led to interstitial cell degenerations, exfoliation of spermatocytes, rupture of epithelium, vacuolations and aspermia (Figure 4 and 5).

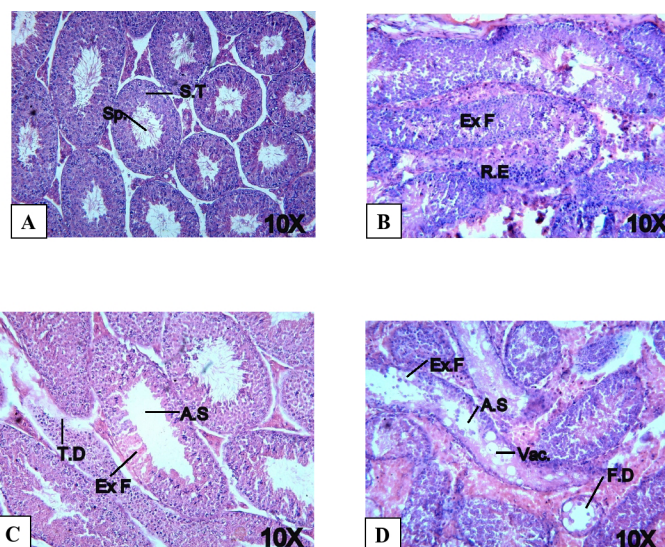


Figure 4: Histopathological examination of testes of LFX exposed mice at 10X magnification. (A) Control mice showing normal tissues i.e. SP: sperm; S.T.: semeniferous. (B) Mice treated with 9.37 µg/g B.W. of LFX showing Ex.F: exfoliation of spermatocytes; R.E: Rapture of epithelium. (C) Mice treated with 18.37 µg/g B.W. of LFX exhibiting A.S: spermia; Ex.F: exfoliation of spermatocytes; T.D: tuber degeneration. (D) Mice treated with 37.50 µg/g B.W. of LFX showing Ex.F: exfoliation of spermatocytes; Vac: vacuolation; F.D: fat deposition, A.S: Aspermia. H and E staining.

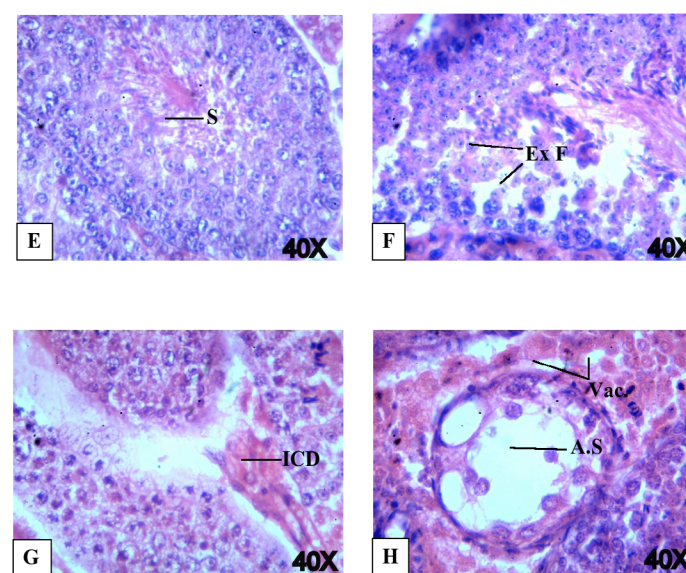


Figure 5: Histopathological examination of testes of LFX exposed mice at 40X magnification. (A) Control mice showing normal tissues i.e. SP: sperms. (B) Mice treated with 9.37 µg/g B.W. of LFX showing Ex.F: exfoliation of spermatocytes. (C) Mice treated with 18.37 µg/g B.W. of LFX exhibiting ICD: interstitial cell degeneration. (D) Mice treated with 37.50 µg/g B.W. of LFX showing Vac: vacuolation; A.S: Aspermia. H and E staining.

Discussion

Although fluoroquinolone antibiotics are being extensively used to treat serious and life threatening infections but most of them are known to be consolidated with inimical effects (Gurbay *et al.*, 2001). Body weight of animal is one of the pragmatic parameter towards antibiotics induced toxicity. Current study exhibited detrimental effects of levofloxacin on weight of mice, as the body weights declined significantly after exposure to different concentrations of levofloxacin (LFX). These findings are contrary to the observations of Ray, 2012 who reported that the relative body weights of antibiotic exposed mice was increased. According to literature, it has been reported that fluoroquinolone antibiotics generate reactive oxygen species that ultimately result in oxidative stress and cellular damage to liver and kidney (Afolabi and Oyewo, 2014; Pouzaud *et al.*, 2006). In current research, levofloxacin being used at three different concentrations induced hepatic damages and altered its histology in the form of necrosis, vacuolations, increased sinusoidal spaces, karyomegaly, hypertrophy and hepatic cysts and hepatocytes disruptions. LFX caused liver injuries due to oxidative stress and depletion of hepatic antioxidant reserves (Olayinka *et al.*, 2015). Functionality and integrity of liver is judged by the reliable marker enzymes of plasma ALT and AST (Naik and Panda, 2007). Additional ALT and AST are released and added into blood plasma when a body tissue or any organ like heart or liver is diseased or damaged (Pratt and Kaplan, 2000). Elevated levels of total Alanine Aminotransferase (ALT), Aspartate Aminotransferase (AST), Alkaline phosphatase (ALP) and bilirubin in serum of LFX treated groups indicated liver dysfunction. These results are in concordance with the study of (Pratt and Kaplan, 2000) who reported that the necrosis of hepatocytes results in an increase of ALT and AST. However, ALP elevation has been attributed to increased osteoblastic activity, neoplasm and hepatobiliary diseases (Singh *et al.*, 2011). Increased level of bilirubin is also associated with hepatocellular damage (Nagao *et al.*, 2012). Exposure of mice kidney to LFX in present study revealed renal damages including glomerulosclerosis, glomerulonephritis, epithelium degenerations, tubular degenerations and dilation of tubules. These findings are corroborating with the results of Dharnidharka *et al.*, 1998, they disclosed that reactive oxygen species and free radicals induce cellular damages to kidney. Commonly serum concentrations are used to screen renal diseases (Johnson, 2011). Deviation in urea and creatinine levels of LFX treated mice be seen from the normal levels, which is an indication of abnormal renal function. Urea level showed a significant decline while creatinine level increased non-significantly. Study of Mouton and Holder, 2006 also reported elevation of creatinine and urea levels in blood plasma. Moreover, plasma urea is also reported to elevate in acute as well as chronic renal diseases, or when there is less efficient circulating blood volume with mitigated

renal perfusion (Stevens *et al.*, 2006). Histopathological alterations manifested in testes of LFX exposed mice were interstitial cell degenerations, exfoliation of spermatocytes, rupture of epithelium, vacuolations and aspermia. These results are in consonance with Ahmadi *et al.*, 2016. Their experiment on male rats treated with levofloxacin showed severe disruptions including immature spermatozoa, less seminiferous tubules and less leydig cells. Their research also revealed that LFX caused destruction in tubules, spermatogonia and primary spermatocytes (Ahmadi *et al.*, 2016). Sperm count was significantly decreased in mice exposed to LFX. According to Ahmadi *et al.*, 2016, sperm concentration reduced linearly as levofloxacin was consumed. The results of Khaki *et al.*, 2008 who worked on ciprofloxacin, were also in accordance to our research, indicating sperm reduction. Another fluoroquinolone, moxifloxacin also exhibited decline in number of sperms, reduced motility and disrupted morphology.

So the chief outcomes of present study revealed that levofloxacin toxicity is proven by various parameters such as morphometry, histology and blood biochemistry. Overall, our results disclose that subchronic exposure of levofloxacin at various concentrations induce hepatic and renal damages, testicular toxicity as well as deviations in enzymatic biomarkers and reduction in sperm count.

Conflict of interests

The authors declare there is no conflict of interest.

References

- Aboubakr, M. and Soliman, A., 2014. Comparative pharmacokinetics of levofloxacin in healthy and renal damaged Muscovy ducks following intravenous and oral administration. *Vet. Med. Int.*, **2014**: 1-6. <https://doi.org/10.1155/2014/986806>
- Afolabi, O.K., and Oyewo, E.B., 2014. Effects of ciprofloxacin and levofloxacin administration on some oxidative stress markers in the rat. *Int. J. Biol. Vet. Agric. Food Eng.*, **8**: 31-39.
- Ahmadi, R., Ahmadifar, M., Safarpour, E., Vahidi-Eyrisofla, N., Darab, M., Eini, A. M., and Alizadeh, A., 2016. The effects of levofloxacin on testis tissue and spermatogenesis in rat. *Cell J. (Yakhteh)*, **18**: 112.
- Albesa, I., Becerra, M.C., Battán, P.C., and Páez, P.L., 2004. Oxidative stress involved in the antibacterial action of different antibiotics. *Biochem. Biophys. Res. Commun.*, **317**: 605-609. <https://doi.org/10.1016/j.bbrc.2004.03.085>
- Al-Soufi, W.F., and Al-Rekabi, F.M.K., 2019. The cytogenetic effects of levofloxacin in male rats. *Adv. Anim. Vet. Sci.*, **7**:138-150. <https://doi.org/10.17582/journal.aavs/2019/7.3.138.150>
- Dharnidharka, V.R., Nadeau, K., Cannon, C.L., Harris, H.W., and Rosen, S., 1998. Ciprofloxacin overdose:

- acute renal failure with prominent apoptotic changes. *Am. J. Kidney Dis.*, **31**: 710-712. <https://doi.org/10.1053/ajkd.1998.v31.pm9531191>
- Dwyer, D.J., Kohanski, M.A., Hayete, B., and Collins, J.J., 2007. Gyrase inhibitors induce an oxidative damage cellular death pathway in *Escherichia coli*. *Mol. Syst. Biol.*, **3**: 91. <https://doi.org/10.1038/msb4100135>
- Gürbay, A., Gonthier, B., Daveloose, D., Favier, A., and Hincal, F., 2001. Microsomal metabolism of ciprofloxacin generates free radicals. *Free Radic. Biol. Med.*, **30**: 1118-1121. [https://doi.org/10.1016/S0891-5849\(01\)00508-1](https://doi.org/10.1016/S0891-5849(01)00508-1)
- Hincal, F., and Taskin, T., 1995. The Mechanism Induced by Ciprofloxacin May Involve the Generation of Free Radicals and the Activation of Excitatory Amino Acid Receptors. *Int. Cong. Toxicol.*, pp. 27.
- Johnson, D.W., 2011. Screening and management: Overview. *Handb. Chronic Kidney Dis. Manage.*, **1**: 32.
- Kavutcu, M., Canbolat, O., Öztürk, S., Olcay, E., Ulutepe, S., Ekinci, C., and Durak, I., 1996. Reduced enzymatic antioxidant defense mechanism in kidney tissues from gentamicin-treated guinea pigs: effects of vitamins E and C. *Nephron*, **72**: 269-274. <https://doi.org/10.1159/000188853>
- Khaki, A., Heidari, M., Ghaffari Novin, M., and Khaki, A. A., 2008. Adverse effects of ciprofloxacin on testis apoptosis and sperm parameters in rats. *Int. J. Reprod. BioMed.*, **6**: 71-0.
- Mouton, R., and Holder, K., 2006. Laboratory tests of renal function. *Anaesth. Intensive Care Med.*, **7**: 240-243. <https://doi.org/10.1053/j.mpaic.2006.04.003>
- Nagao, Y., Watanabe, H., and Yokota, S. I., 2012. Percentile analysis of plasma total bilirubin—how different will the rate of phototherapy for jaundice of neonates be by different standards? *Open J. Pediatr.*, **2**: 133. <https://doi.org/10.4236/ojped.2012.22022>
- Naik, S.R., and Panda, V.S., 2007. Antioxidant and hepatoprotective effects of Ginkgo biloba phytosomes in carbon tetrachloride induced liver injury in rodents. *Liver Int.*, **27**: 393-399. <https://doi.org/10.1111/j.1478-3231.2007.01463.x>
- Norra, C., Skobel, E., Breuer, C., Haase, G., Hanrath, P., and Hoff, P., 2003. Ciprofloxacin-induced acute psychosis in a patient with multidrug-resistant tuberculosis. *Eur. Psychiatry*, **18**: 262-263. [https://doi.org/10.1016/S0924-9338\(03\)00091-9](https://doi.org/10.1016/S0924-9338(03)00091-9)
- Olayinka, E.T., Ore, A., and Ola, O.S., 2015. Influence of different doses of levofloxacin on antioxidant defense systems and markers of renal and hepatic dysfunctions in rats. *Adv. Toxicol.*, Article ID 385023, 7 pages. <https://doi.org/10.1155/2015/385023>
- Pouzaud, F., Dutot, M., Martin, C., Debray, M., Warnet, J.M., and Rat, P., 2006. Age-dependent effects on redox status, oxidative stress, mitochondrial activity and toxicity induced by fluoroquinolones on primary cultures of rabbit tendon cells. *Comp. Biochem. Physiol. Part C: Toxicol. Pharmacol.*, **143**: 232-241. <https://doi.org/10.1016/j.cbpc.2006.02.006>
- Pratt, D.S., and Kaplan, M.M., 2000. Evaluation of abnormal liver-enzyme results in asymptomatic patients. *N. Engl. J. Med.*, **342**: 1266-1271. <https://doi.org/10.1056/NEJM200004273421707>
- Rahman, K., 2007. Studies on free radicals, antioxidants, and co-factors. *Clin. Interv. Aging*, **2**: 219.
- Ramalakshmi, S., Bastacky, S., and Johnson, J.P., 2003. Levofloxacin-induced granulomatous interstitial nephritis. *Am. J. Kidney Dis.*, **41**: e7-1. <https://doi.org/10.1053/ajkd.2003.50064>
- Ray, K., 2012. Gut microbiota: adding weight to the microbiota's role in obesity—exposure to antibiotics early in life can lead to increased adiposity. *Nat. Rev. Endocrinol.*, **8**: 623. <https://doi.org/10.1038/nrendo.2012.173>
- Singh, S.K., Dimri, U., Kataria, M., and Kumari, P., 2011. Ameliorative activity of *Withania somnifera* root extract on paraquat-induced oxidative stress in mice. *J. Pharmacol. Toxicol.*, **6**: 433-439. <https://doi.org/10.3923/jpt.2011.433.439>
- Stevens, L.A., Coresh, J., Greene, T., and Levey, A.S., 2006. Assessing kidney function—measured and estimated glomerular filtration rate. *N. Engl. J. Med.*, **354**: 2473-2483. <https://doi.org/10.1056/NEJMra054415>
- Thuong-Guyot, M., Domarle, O., Pocidalo, J.J., and Hayem, G., 1994. Effects of fluoroquinolones on cultured articular chondrocytes flow cytometric analysis of free radical production. *J. Pharmacol. Exp. Ther.*, **271**: 1544-1549.
- Val, G.M.D., and Robledano, P.M., 2013. In vivo serial sampling of epididymal sperm in mice. *Lab. Anim.*, **47**: 168-174. <https://doi.org/10.1177/0023677213478411>
- Wagener, F., Carels, C., and Lundvig, D., 2013. Targeting the redox balance in inflammatory skin conditions. *Int. J. Mol. Sci.*, **14**: 9126-9167. <https://doi.org/10.3390/ijms14059126>
- Yazar, E., and Tras, B., 2001. Effects of fluoroquinolone antibiotics on hepatic superoxide dismutase and glutathione peroxidase activities in healthy and experimentally induced peritonitis mice. *Rev. Méd. Vét.*, **152**: 235-238.