



RESEARCH

Isolation and Detection of Avian Reovirus from Tenosynovitis and Malabsorption Affected Broiler Chickens with Involvement of Vertical Transmission

Shimaa M. Mansour¹, Reham M. ElBakrey², Ahmed Orabi¹, Haytham Ali³, Amal A. Eid²

ABSTRACT

Background: Avian Reovirus (ARV) is involved in many pathologic syndromes of chicken including the both major syndromes, Viral Arthritis (VA) and Runting Stunting Syndrome (RSS), which have great negative impacts on the poultry industry. Although ARV was reported in Egypt since 1984 but only few studies figured out the implication of ARV only in the uneven growth of some Egyptian chicken flocks.

Aim: Clinical and molecular investigation of avian reovirus infection in broiler chickens with availability of Vertical Transmission

Methods: Herein, 18 chickens derived from 4 broiler flocks within Sharkia Province, Egypt suffering from different degrees of lameness and/or stunting were clinically and molecularly examined for the presence of ARV.

Results: By clinical examination, one third (6/18) of examined chickens showed bilateral arthritis with tendons included microscopic changes consistent with the typical ARV infection. Additionally, eight chickens (8/18) showed stunting and another one chicken (1/18) showed poor feathering while the last three chickens (3/18) appeared diarrheic. All clinically affected chickens showed varied postmortem lesions that almost associated with ARV infections. Further molecular detection of ARV within the 18 clinically affected samples (n=18) by RT-PCR using a specific primer set targeting a conserved sequence within ARV- sigma C protein revealed 7/18 positive samples. All positive samples (7/18) were successfully isolated on specific pathogen free embryonated chicken eggs (SPF-ECE). Additional RT-PCR testing and re-isolation of ARV from ECEs of a breeder flock of a history of uneven growth and/or arthritis revealed ARV infection in six (6/60) examined ECEs.

Conclusion: These results indicated the incrimination of ARV infection in some arthritis infections beside the low food conversion rate of chickens within Sharkia Province, Egypt. Moreover, the obtained data highlight the importance of vertical transmission in the field spread of ARV infections.

Keywords: ARVs, Isolation, Vertical transmission, Arthritis, Malabsorption

BACKGROUND

Avian reovirus (ARV), within the genus *Orthoreovirus* of the family *Reoviridae*, induces clinical diseases in chicken (Robertson and Wilcox, 1986). Beside the both ARV major associated diseases, viral tenosynovitis/arthritis (VA) and enteritis related -runting stunting syndrome (RSS) or - malabsorption syndrome (MAS), ARVs are also involved in other serious conditions e.g. chronic respiratory disease (CRD), immunosuppression and inclusion body hepatitis (Fahey and Crawley, 1954; Jones and Guneratne, 1984; Rosenberger *et al.*, 2003). ARV are usually perceived in domestic broiler and broiler breeder chickens causing less weight gain, diminished marketability and high mortality rates which in turn have economical drawbacks on the poultry industry (Jones and Kibenge, 1984; Rosenberger *et al.* 1989). Although VA is almost the disease of heavy meat-type broiler but an occasional ARV associated VA outbreak was reported in lighter breeds (Schwartz *et al.*, 1976). The both VA and RSS/MAS lead to nutrient deficiency in affected birds, which in many cases fated to death, either via the disability of the

affected bird to move to food and water supplies or by the disruption of food digestion and absorption (Rosenberger *et al.*, 1989; Songserm *et al.*, 2003).

Reoviruses including ARV are non-enveloped viruses characterized by a unique double icosahedral capsid shell encasing a segmented double-stranded RNA (dsRNA) genome (Benavente and Martinez-Costas, 2007). The RNA segments (n=10) of ARV genome are of 1-4 kb and classified according to the molecular size on electrophoresis as small (S1-S4), medium (M1-M3) and large (L1-L3) segments. ARVs genome is coded for at least 12 viral proteins, 8 structural and 4 non-structural proteins (Bodelon *et al.*, 2001). Sigma C protein (encoded by S1) is a minor viral-cell attachment capsid protein used as a base for classifying ARV (Schnitzer, 1985; Wickramasinghe *et al.*, 1993). Although the sigma C protein includes the most hypervariable regions of ARV proteins that elicit specific neutralizing antibodies against ARV (Guardado Calvo *et al.*, 2005; Liu *et al.*, 2003) but some other conserved sequences within sigma C protein could also be identified (Goldenberg *et al.*, 2010).

ARV transmitted between birds horizontally often through ingestion and inhalation (al Afaleq and Jones, 1990; Ni and Kemp, 1995; Roessler and Rosenberger, 1989). Some studies demonstrated the possibility of ARV infection through the broken skin (al Afaleq and Jones, 1990). The vertical transmission of ARV was experimentally proved and revealed the tendency of ARV to persist for long periods in the cecal tonsils and hock joints of infected young chicks (Jones and Georgiou, 1984; Marquardt *et al.*, 1983). Thus, the young hatched chicks from ARV infected breeders act as a carrier for ARV and can spread the infection horizontally to the uninfected birds and surroundings (Al-Muffarej *et al.*, 1996; Menendez *et al.*, 1975).

In Egypt, avian reoviruses were firstly reported in 1984 (Tantawi *et al.*, 1984). Since then, few published studies addressed the Egyptian avian reoviruses (Madbouly *et al.*, 1997a; Madbouly *et al.*, 1997b; Madbouly *et al.*, 1997c; Madbouly and El-Sawah, 1999; Madbouly *et al.*, 2001; Madbouly *et al.*, 2009; Zaher and Mohamed, 2009; Abd el-samie, 2014). This study aimed to isolate and detect recent avian reoviruses from both embryonated chicken eggs (ECEs) and chickens showing different clinical signs that usually identified in avian reovirus infections, lameness and stunting.

MATERIALS AND METHODS

Clinical samples

A total number of 18 chickens from 4 different broiler chicken flocks across Sharkia Province, Egypt showed signs of lameness and/ or poor growth were submitted by the owners to Avian and Rabbit Medicine Department, Faculty of Veterinary Medicine, Zagazig University, Egypt. Prior to euthanasia for necropsy, all chickens were examined clinically and all signs were scored and recorded. For isolation and molecular identification of ARVs and also for histopathology, tendons and synovial tissues were collected from birds showing lameness. Other tissues including heart, liver, proventriculus, intestine, bursa and thymus were also collected when pericarditis lesions and /or clinical signs of poor growth were present alone or together with arthritis. Additional random 60 ECEs were collected from a breeder flock with a previous history of lameness and stunting for isolation and molecular diagnosis of ARV.

RNA extraction and RT-PCR

Viral nucleic acid was extracted from each broiler chicken tissue specimen and embryo's liver of breeder flock, using an RNeasy Mini Kit (QIAGEN, Valencia, CA), following the manufacturer's instructions. The extracted RNA was used as a template to amplify a 532 bp fragment from an ARV S1 segment using the published primers MK87/ MK88. The RT-PCR assay was conducted in a 50 µl reaction mixture using a One Step RT-PCR Kit (QIAGEN,

Valencia, CA) containing 10 µl of template RNA, 25 µl of RNase-free water, 10 µl of 5 × Buffer, 2 µl of dNTP mix (10 mM each dNTP), 1 µl of enzyme mix, and 1 µl of each of the two primers MK87: 5- GGT GCG ACT GCT GTA TTT GGT AAC-3 and MK88: 5- AAT GGA ACG ATA GCG TGT GGG-3 that encompass an amplicon of 532 bp length (Xie *et al.*, 1997). Amplification was performed with the Applied Biosystems 9700 thermal cycler using a reverse transcription step at 50°C for 30 min. The initial PCR activation step was set at 95°C for 15 min; then was followed by 94°C for 30 s, 50°C for 30s, and 72°C for 90 s of each cycle for 38 cycles; and finally was completed with a single cycle of 72°C for 5 min.

Virus isolation

Each PCR positive tissue specimen was homogenized in adequate volume (1:10 w/v) of a sterile phosphate-buffered saline (PBS) with antibiotics (Penstrept, Lonza) using a sterile mortar. The tissue homogenate was centrifuged at 2000 rpm for 10 min. The supernatant was filtered through a sterile syringe membrane filter with a 0.45µm pore size. Thereafter, 200 µl volume of the filtrate were inoculated in the 5-7 day-old embryonated chicken eggs (ECE) via the yolk route. The inoculated ECEs were then incubated at 37°C with daily candling up to 10 days. ECEs showed pathognomonic lesions of ARVs at 14-16 days post inoculation were recorded positive (Jones, 2000).

Histopathology

Tissue specimens were fixed in 10% formalin and processed routinely for histological examination. Tissues were processed and paraffin blocks were sectioned in duplicates and stained with hematoxylin and eosin (H&E) and examined under light microscope for any significant findings (Spackman *et al.*, 2010).

RESULTS

The clinical signs

Clinically, the chickens exhibited varying degrees of lameness, difficulties in movement. Bilateral arthritis and tenosynovitis affecting the hock joint were observed in 6/18 tested chickens. A high morbidity up to 50% of the investigated flocks was observed, and the mortality in the most severe cases was up to 10%. Moreover, another birds exhibited general malaise, stunting (44.4%) and uneven growth in a flock with a high culling rate, diarrhea with undigested feed resulting in wet litter. Distended abdomens, depression, poor feathering and diarrhea were also noticed (Table 1). Morbidity ranged from 10 to 30%, and mortality rates up to 12% were recorded.

Table 1: Clinical findings of avian reovirus in broiler chickens, Sharkia Province, Egypt during 2014-2016

No	Clinical signs			Gross lesion						
	Bilateral arthritis	Poor growth/ Stunting	Poor feathering	Swelling of joint/tendon	Enlarged proventriculus	Distended intestine/ Undigested food	Pericarditis	Atrophy of pancreas	Atrophy of bursa	Paleness in muscle
1	-	50%	16.7%	-	33.3%	-	16.7%	-	-	-
2	60%	40%	-	60%	20%	20%	20%	-	-	-
3	50%	50%	-	50%	25%	50%	-	50%	25%	50%
4	33.3%	33.3%	-	33.3%	66.7%	33.3%	33.3%	33.3%	-	66.7%
Total	33.3%	44.4%	5.6%	33.3%	33.3%	22.2%	16.7%	16.7%	5.6%	22.2%

Gross lesions and pathological examination

Broilers that suffered from lameness (Fig. 1a) showed marked swelling in the hook joints (Fig. 1b). Birds showed severe tenosynovitis of the gastrocnemius tendon represented by hemorrhages and edema in tendon and the tendon sheath (Fig. 1c). Microscopically marked infiltrations of the tendon with lymphocytes, plasma cells, and few heterophils were observed. The proventriculus was distinctly dilated and enlarged (Fig. 1d) and showed lymphocytic infiltrates in the proventricular glands and in the lamina propria. The intestine was pale, dilated and filled with undigested feed (Fig. 1e); while microscopically the intestinal submucosa was infiltrated with lymphocytes, plasma cells and few heterophils. Marked atrophy of the pancreas was observed in most affected birds (Fig. 1e). Bursa of Fabricius was atrophied and showed lymphoid depletion of its follicles (Fig. 1f). Pericarditis lesions were also present in three affected birds.

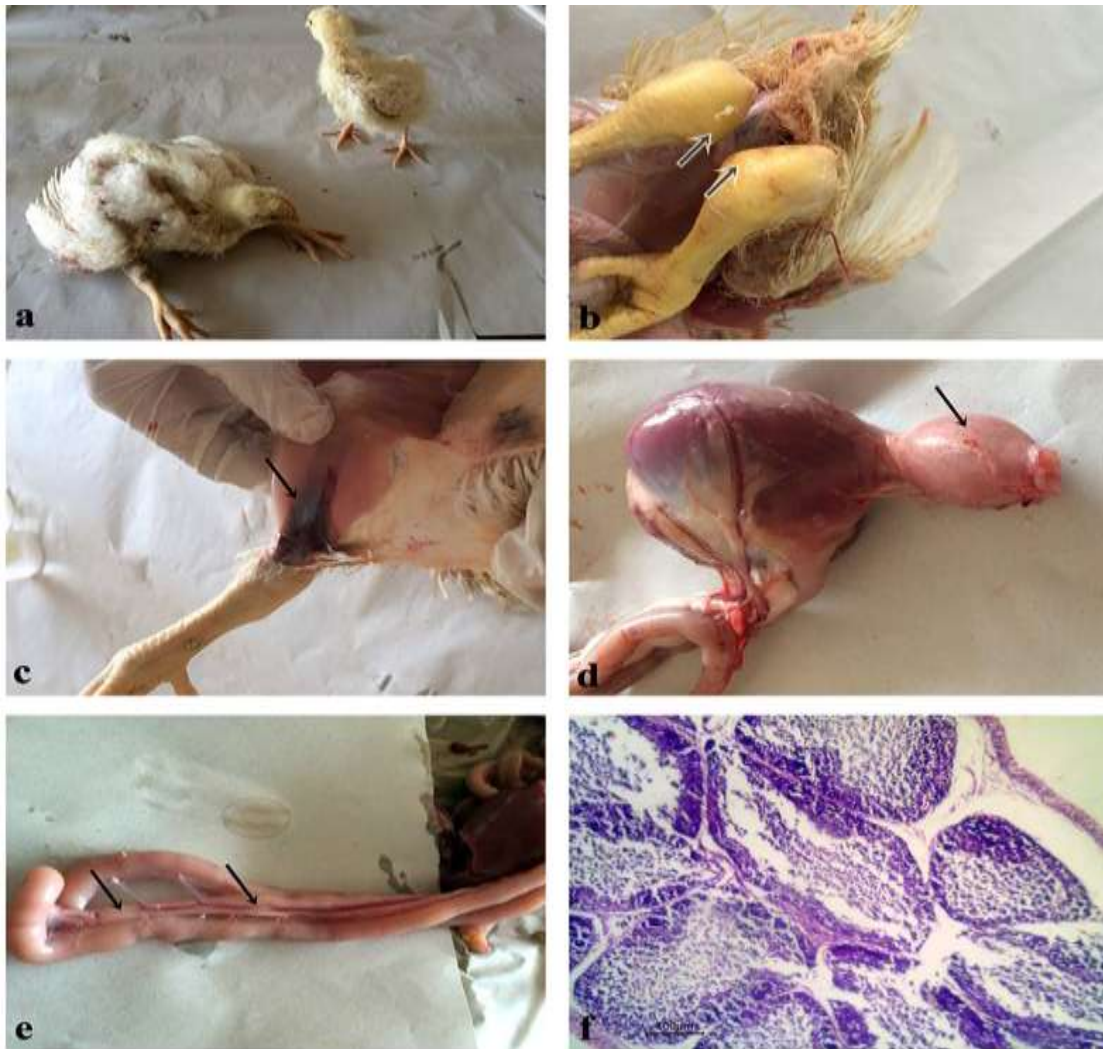

Fig. 1: Clinical signs and pathological lesions of avian reovirus infections in broiler chickens. **(a)** Broiler cases with stunting growth and arthritis at 4 weeks of age; **(b)** Broiler cases with bilateral arthritis and swelling of hock joints (Arrows); **(c)** Marked hemorrhages in the tendon and tendon sheaths (Arrow); **(d)** Enlarged proventriculus (Arrow); **(e)** Pale and dilated intestine with markedly atrophied pancreas (arrows); **(f)** Bursa of Fabricius follicles with moderate lymphocytic depletion.

Molecular detection of ARV using RT-PCR

ARV was molecularly identified in seven (7/18) broiler chickens showed signs and lesions resembling that of VA (n=4) and RSS (n=3) and also in 6/60 ECEs. Total RNA was used as a template for RT-PCR reactions; non infected-embryos and RNase free water were used as negative controls. Using primer pairs of S1 gene, RNA extracts from all ARV isolates were transcribed into cDNA and amplified, producing fragments with expected sizes of 532 bp. RNA extracted from non-infected embryos and RNase-free water were used as negative controls. In negative controls no ARV cDNA was detected, indicating that the amplified viral DNA was specific and did not originate from contamination (data not shown).

ARV isolation on ECEs

The virus was isolated from all ARV-PCR positive chickens (n=7) and also from all ARV-PCR positive ECEs (n=6) in the yolk sac of 5 -7 days old ECEs. In first passage, edema with abdominal distention and cutaneous congestion were observed in the half of inoculated embryos. Additionally, the inoculated embryos showed green liver, gelatinous material as shown in Fig. 2b, and greenish allantoic fluid. In second passage, necrotic foci on liver (Fig. 2c) and heart were noticed.

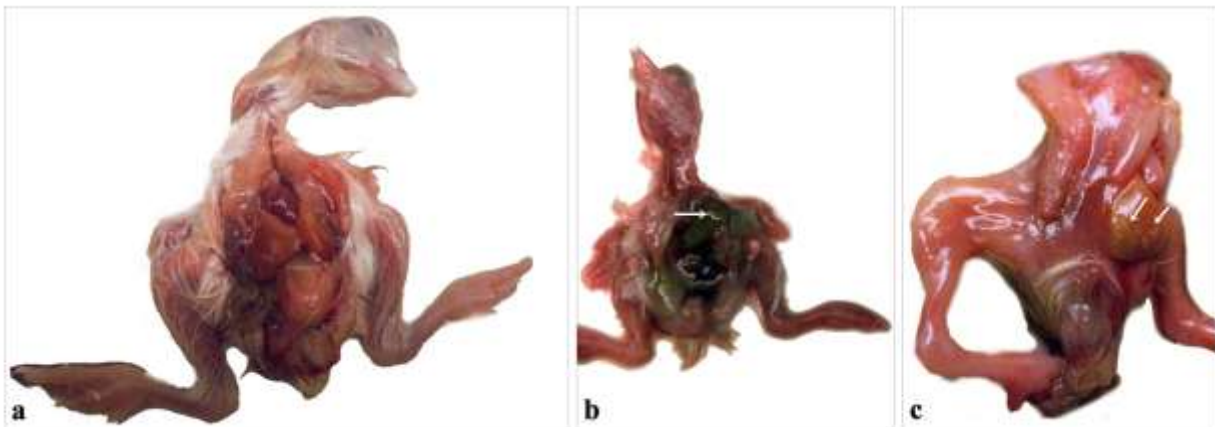


Fig. 2: Evidence of ARV infection in ECEs. (a) Mock-inoculated chicken embryo 17 day-old showing normal size embryo. (b) Mock-inoculated chicken embryo 17 days-old showed submandibular and subcutaneous edema, green liver with gelatinous exudates. (c) Chicken embryo inoculated with allantoic fluids of the aforementioned embryo showed necrotic foci on liver after the second passage.

DISCUSSION

Although ARV was firstly reported in Egypt since a relatively long time (Tantawi *et al.*, 1984) but no enough studies were directed toward such important virus. Additionally, the awareness about ARV and its recent impacts on Egyptian field is still unclear. This could be attributed to the subclinical tendency of most ARV infections beside their low morbidity and mortality rates in non-mixed infections (Rosenberger and Olson, 1997; Sterner *et al.*, 1989; van der Heide, L. 2000). Recently, new strains of ARV were emerged causing drastic economic drawbacks across Canada and USA (Ayalew *et al.*, 2017) which in turn draw the attention toward ARV. To enhance the knowledge of ARV in Egypt, the isolation and detection of ARV from chickens suffering from different ARV associated syndromes is considered an ultimate goal. Additionally, the information about the role of vertical transmission in the field spread of ARV is still so limited despite the fact that it is confirmed in the *in vivo* experiments (Menendez

et al., 1975; van der Heide and Kalbac, 1975). In this study, the isolation and molecular detection of ARV in different tissues derived from chicken suffered from arthritis and lower growth rate within Sharkia Province, Egypt was performed. Further isolation and molecular detection of ARV in ECEs randomly collected from a breeder flock was done to test whether the vertical transmission is involved in the spread of ARV among chicken flocks across Sharkia Province, Egypt or not?

ARV is included in many pathological conditions however only two, VA and RSS, constitute the major ARV associated disorders (Jones and Guneratne, 1984; Rosenberger *et al.*, 2003). Although arthritis in chicken is multifactorial dependent but VA was traditionally considered the major cause (Olson *et al.*, 1957). Most of ARV strains can cause VA but in some cases ARV was isolated in non-VA infected chickens (Jones and Guneratne, 1984; Sahu and Olson, 1975). In the same accordance, the clinical and postmortem examination of chickens under study revealed a number (n=12) of ARV infected chickens without any signs or lesions of arthritis (Fig. 1a). This confirms that not all ARV strains are arthrotropic in nature. The arthritis in all studied chickens appeared bilateral with marked swellings in both hock joints (Fig.1b). Similar lesions were obtained by the experimental infection of SPF chickens by an arthrotropic ARV strain but either unilateral or bilateral arthritis was observed (Jones and Guneratne, 1984). Although the signs and lesions in ARV-VA are not specific for ARV as they are almost the same as in case of *Mycoplasma synoviae* and *Staphylococcus aureus* infections but the lymphocytic inflammation is characteristic for ARV-VA (Hill *et al.*, 1989). In this study, tendons derived from arthritis affected chickens showed obvious infiltration of lymphocytes indicating that the disease is almost ARV related VA. Beside the characteristic arthritis lesions, additional marked lesions including pericarditis (Table 1) and lymphocytic depletion in the bursa of Fabricius (Fig. 1f) were observed in some of chicken that showed arthritis. It is common in ARV-VA infected birds to show other microscopic lesions in different organs e.g. liver, heart, spleen and bursa of Fabricius together with the pathognomonic arthritis lesions (Hill *et al.*, 1989; Roessler and Rosenberger, 1989; Tang *et al.*, 1987). Along with the clinical signs and lesions, the RT-PCR results confirmed the presence of ARV in 4/18 chickens suffered from arthritis indicating that the existed arthritis was almost ARV related.

MAS or RSS is associated with ARV infections. The most characteristic signs of MAS are stunted growth, poor feathering, diarrhea and increased lameness (Hieronymus *et al.*, 1983) while the MAS mostly associated lesions are enlarged lemon shaped proventriculus, decreased size gizzard, pancreatic atrophy and swollen and weak intestinal tracts (Page *et al.*, 1982). These signs and lesions were clearly observed in many of studied chicken (Table 1 and Fig. 1). In addition, the RT-PCR confirmed the presence of ARV in 3/18 chickens suffered from MAS indicating that ARV is the primary cause in such affected birds. Contrast to some chickens showed stunted growth, all chickens suffered from either poor feathering or diarrhea tested negative in RT-PCR for ARV (data not shown) suggesting other cause/s for such signs.

Since ARV persists in the oviduct of affected chickens for periods longer than other tissues (at least 258 days) (Kerr and Olson, 1969) so there is a great possibility for ARV transmission vertically. The vertical transmission could be also confirmed experimentally (Menendez *et al.*, 1975; van der Heide and Kalbac, 1975). In the same context, ARV was molecularly detected in 10% of ECEs collected from a breeder flock indicating that vertical transmission could be largely incriminated in the field spread of ARV in Egypt. Further studies are required to determine the potential role of vertical transmission on the spread and emergence of ARV in affected flocks.

For isolation of ARV, the yolk sac inoculation into ECEs is considered a highly sensitive method (Guneratne *et al.* 1982). All studied ARV-PCR positive samples from affected chickens

(n=7) and from ECEs derived from a breeder flock (n=10) were successfully isolated into ECEs using yolk sac inoculation route. One of most characteristic lesions of isolated ARV in ECEs is a yellow green like liver dotted with discrete necrotic foci (Deshmukh and Pomeroy, 1969). In this study, the same lesions were observed (Fig.2) in most of inoculated ECEs but after the second passage. Besides, a gelatinous material in a greenish allantoic fluid was found in some ECEs.

In conclusion, our data revealed the continuous circulation of ARV in the Egyptian field with the implication of vertical transmission in the spread of ARV infection. These results raise the concern toward ARV and its incrimination in retarded growth rate and arthritis among chicken flocks that consequently have great drawbacks on the poultry industry in Egypt.

ACKNOWLEDGMENTS

The authors would like to thank the Avian and Rabbit Medicine Department, Faculty of Veterinary Medicine, Zagazig University, Zagazig, Egypt.

AUTHOR DETAILS

¹Department of Virology, Faculty of Veterinary Medicine, Zagazig University, Zagazig, Egypt.

²Department of Avian and Rabbit Medicine, Faculty of Veterinary Medicine, Zagazig University, Zagazig, Egypt.

³Department of Pathology, Faculty of Veterinary Medicine, Zagazig University, Zagazig, Egypt.

RECEIVED: May 2018; **ACCEPTED:** June 2018; **Published:** July 2018

REFERENCES

- Abd el-samie, L.K. (2014):** Some causes of chicken's growth retardation in Sharkia, Egypt. *Assiut Vet. Med* 61: 144.
- Al Afaleq, A.I., Jones, R.C. (1990):** Localisation of avian reovirus in the hock joints of chicks after entry through broken skin. *Res Vet Sci* 48: 381-382.
- Al-Muffarej, S.I., Savage, C.E., Jones, R.C. (1996):** Egg transmission of avian reoviruses in chickens: comparison of a trypsin-sensitive and a trypsin-resistant strain. *Avian Pathol* 25: 469-480.
- Ayalew, L.E., Gupta, A., Fricke, J., Ahmed, K.A., Popowich, S., Lockerbie, B., Tikoo, S.K., Ojkic, D., Gomis, S. (2017):** Phenotypic, genotypic and antigenic characterization of emerging avian reoviruses isolated from clinical cases of arthritis in broilers in Saskatchewan. *Canada. Sci Rep.* 7(1): 3565.
- Benavente, J., Martínez-Costas, J. (2007):** Avian reovirus: structure and biology. *Virus Res* 123: 105-119.
- Bodelon, G., Labrada, L., Martínez-Costas, J., Benavente, J. (2001):** The avian reovirus genome segment S1 is a functionally tricistronic gene that expresses one structural and two nonstructural proteins in infected cells. *Virology* 290: 181-191.
- Deshmukh, D.R., Pomeroy, B.S. (1969):** Avian reoviruses. I. Isolation and serological characterization. *Avian Dis* 13: 239-243.
- Fahey, J.E., Crawley, J.F. (1954):** Studies On Chronic Respiratory Disease of Chickens III. Egg Transmission of A. Pleuropneumonia-Like Organism. *Can J Comp Med Vet Sci* 18: 67-75.
- Goldenberg, D., Pasmanik-Chor, M., Pirak, M., Kass, N., Lublin, A., Yeheskel, A., Heller, D., Pitcovski, J. (2010):** Genetic and antigenic characterization of sigma C protein from avian reovirus. *Avian Pathol* 39: 189-199.

- Guardado Calvo, P., Fox, G.C., Hermo Parrado, X.L., Llamas-Saiz, A.L., Costas, C., Martínez-Costas, J., Benavente, J., van Raaij, M.J. (2005):** Structure of the carboxy-terminal receptor-binding domain of avian reovirus fibre sigmaC. *J Mol Biol* 354: 137-149.
- Guneratne, J.R., Jones, R.C., Georgiou, K. (1982):** Some observations on the isolation and cultivation of avian reoviruses. *Avian Pathol* 11: 453-462.
- Hieronimus, D.R., Villegas, P., Kleven, S.H. (1983):** Identification and serological differentiation of several reovirus strains isolated from chickens with suspected malabsorption syndrome. *Avian Dis* 27: 246-254.
- Hill, J.E., Rowland, G.N., Steffens, W.L., Ard, M.B. (1989):** Ultrastructure of the gastrocnemius tendon and sheath from broilers infected with reovirus. *Avian Dis* 33: 79-85.
- Jones, R.C. (2000):** Avian reovirus infections. *Revue Scientifique et Technique-Office International des Epizooties*, 19(2), 614-619
- Jones, R.C., Georgiou, K. (1984):** Reovirus-induced tenosynovitis in chickens the influence of age at infection. *Avian Pathol* 13: 441-457.
- Jones, R.C., Guneratne, J.R. (1984):** The pathogenicity of some avian reoviruses with particular reference to tenosynovitis. *Avian Pathol* 13: 173-189.
- Jones, R.C., Kibenge, F.S. (1984):** Reovirus-induced tenosynovitis in chickens: the effect of breed. *Avian Pathol* 13: 511-528.
- Kerr, K.M., Olson, N.O. (1969):** Pathology of chickens experimentally inoculated or contact-infected with an arthritis-producing virus. *Avian Dis* 13: 729-745.
- Liu, H.J., Lee, L.H., Hsu, H.W., Kuo, L.C., Liao, M.H. (2003):** Molecular evolution of avian reovirus: evidence for genetic diversity and reassortment of the S-class genome segments and multiple cocirculating lineages. *Virology* 314: 336-349.
- Madbouly, H.M., El-Sawah A.A. (1999):** Isolation of reovirus from naturally infected turkeys and turkey poults in Egypt. *Beni-Suef, Vet.Med.J*, Vol.9, No.3-B, 513-525.
- Madbouly, H.M., El-Sawah A.A., Tamam, S.M. (2001):** An outbreak of avian reovirus in native breed broilers at El- Fayuom Governorate. *Beni-Suef, Vet.Med.J*, VolXI, No.(1)31-45.
- Madbouly, H.M., Hussein, A.S., Zaki, T.K., Ensaf, M.H. (2009):** Preparation of oil adjuvant Inactivated avian reovirus vaccines. 3rd Sci.Conf., 29 Jan.-1 Feb. 2009 Benha & Ras Sudr, Egypt. *Fac. Vet. Med.(Moshtohor), Benha Univ.*, 510-529.
- Madbouly, H.M., M.S. Saber; Amina, A.M. Nawar and Samah H. Mohamed (1997a):** Studies on the avian reoviruses in Egypt I- Isolation and identification of the virus. *Beni-Suef, Vet.Med.Res.*, Vol.VII, No.2, 29-45.
- Madbouly, H.M., Saber, M.S., Nawar, A.A.M., El-Sawy, A., Mohamed, S.H. (1997c):** Studies on the avian reoviruses in Egypt.Histopathological examination .*Beni-Suef, Vet.Med.Res.*, Vol.VII, No.2, 65-80.
- Madbouly, H.M., Saber, M.S., Nawar, A.A.M., Mohamed, S.H. (1997b):** Studies on the avian reoviruses in Egypt II-Pathogenesis of the virus.*Beni-Suef, Vet.Med.Res.*, Vol.VII, No.2, 47-63.
- Marquardt, J., Hermanns, W., Schulz, L.C., Leibold, W. (1983):** A persistent reovirus infection of chickens as a possible model of human rheumatoid arthritis (RA). *Zentralbl Veterinarmed B* 30: 274-282.
- Menendez, N.A., Calnek, B.W., Cowen, B.S. (1975):** Experimental egg-transmission of avian reovirus. *Avian Dis* 19: 104-111.
- Ni, Y., Kemp, M.C. (1995):** A comparative study of avian reovirus pathogenicity: virus spread and replication and induction of lesions. *Avian Dis* 39: 554-566.

- Olson, N.O., Shelton, D.C., Munro, D.A. (1957):** Infectious synovitis control by medication; effect of strain differences and pleuropneumonia-like organisms. *Am J Vet Res* 18: 735-739.
- Page, R.K., Fletcher, O.J., Rowland, G.N., Gaudry, D., Villegas, P. (1982):** Malabsorption syndrome in broiler chickens. *Avian Dis* 26: 618-624.
- Robertson, M.D., Wilcox, G.E. (1986):** Avian reovirus. *Vet Bull* 56:154–174.
- Roessler, D.E., Rosenberger, J.K. (1989):** In vitro and in vivo characterization of avian reoviruses. III. Host factors affecting virulence and persistence. *Avian Dis* 33: 555-565.
- Rosenberger, J.K., Olson, N.O. (1997):** Viral arthritis. In: B.W. Calnek, H.J. Barnes, C.W. Beard, L.R. McDougald, and Y.M. Saif. *Diseases of Poultry, Ames: Iowa State University Press; Ames* 10: 711–718.
- Rosenberger, J.K., Saif, Y.M., Barnes, H.J., Glisson, J.R., Fadly, A.M., McDougald, L.R., Swayne, D.E. (2003):** Reovirus infections. *Diseases of Poultry, Ames: Iowa State University Press* 11: 283-298.
- Rosenberger, J.K., Sterner, F.J., Botts, S., Lee, K.P., Margolin, A. (1989):** In vitro and in vivo characterization of avian reoviruses. I. Pathogenicity and antigenic relatedness of several avian reovirus isolates. *Avian Dis* 33: 535-544.
- Sahu, S.P., Olson, N.O. (1975):** Comparison of the characteristics of avian reoviruses isolated from the digestive and respiratory tract, with viruses isolated from the synovia. *Am J Vet Res* 36: 847-850.
- Schnitzer, T.J. (1985):** Protein coding assignment of the S genes of the avian reovirus S1133. *Virology* 141: 167-170.
- Schwartz, L.D., Gentry, R.F., Rothenbacher, H., van der Heide, L. (1976):** Infectious tenosynovitis in commercial White Leghorn chickens. *Avian Dis* 20: 769-773.
- Songserm, T., van Roozelaar, D., Kant, A., Pol, J., Pijpers, A., ter Huurne, A. (2003):** Enteropathogenicity of Dutch and German avian reoviruses in SPF white leghorn chickens and broilers. *Vet Res* 34: 285-295.
- Spackman, E., Day, J.M., Pantin-Jackwood, M.J. (2010):** Astrovirus, reovirus, and rotavirus concomitant infection causes decreased weight gain in broad-breasted white poults. *Avian Dis.* 54:16–21.
- Sterner, F.J., Rosenberger, J.K., Margolin, A., Ruff, M.D. (1989):** In vitro and in vivo characterization of avian reoviruses. II. Clinical evaluation of chickens infected with two avian reovirus pathotypes. *Avian Dis* 33: 545-554.
- Tang, K.N., Fletcher, O.J., Villegas, P. (1987):** The effect on newborn chicks of oral inoculation of reovirus isolated from chickens with tenosynovitis. *Avian Dis* 31: 584-590.
- Tantawi, H.H., Amina, N., Youssef, Y.I., Fawzia, M., Al-Abdulla, J.M., el-Batrawi, A., el-Ghawas, A., Nasser, A.A., Reda, I.M. (1984):** Infectious tenosynovitis in broilers and broiler breeders in Egypt. *Vet Res Commun* 8: 229-235.
- van der Heide, L. (2000):** The history of avian reovirus. *Avian Dis* 44: 638-641.
- van der Heide, L., Kalbac, M. (1975):** Infectious tenosynovitis (viral arthritis): characterization of a Connecticut viral isolant as a reovirus and evidence of viral egg transmission by reovirus-infected broiler breeders. *Avian Dis* 19: 683-688.
- Wickramasinghe, R., Meanger, J., Enriquez, C.E., Wilcox, G.E. (1993):** Avian reovirus proteins associated with neutralization of virus infectivity. *Virology* 194: 688-696.
- Xie, Z., Fadl, A.A., Girshick, T., Khan, M.I. (1997):** Amplification of avian reovirus RNA using the reverse transcriptase-polymerase chain reaction. *Avian Dis* 41: 654-660.
- Zaher, K., Mohamed, S. (2009):** Diagnosis of avian reovirus infection in local Egyptian chicks. *Global Veterinaria* 3: 227-229.

Cite this article as:

Amal A.M. Eid *et al.*, (2018): Comparative Studies on Evaluation of Different Avian Influenza Inactivated Vaccines under Local Conditions in Egypt., *J. of Virol. Sci.*, Vol. 4: 24-32, 2018.