

## Research Article



# Phylogenetic and Histopathological Characterization of Newcastle Disease Virus (VII.1.1) Recently Isolated from Naturally Infected Quails in Egypt

MOHAMED LEBDAH<sup>1</sup>, SAHAR ABD EL RAHMAN<sup>2\*</sup>, AHMED ATTIA<sup>3</sup>, REHAM KARAM<sup>2</sup>, NAGLAA FATHY SAEED AWAD<sup>1</sup>, MOHAMED IBRAHIM EL BAGOURY<sup>1</sup>

<sup>1</sup>Department of Avian and Rabbit Medicine, Faculty of Veterinary Medicine, Zagazig University, Zagazig, Sharkia, 44511, Egypt; <sup>2</sup>Department of Virology; Faculty of Veterinary Medicine, Mansoura University, 35516 El-Gomhoria Street, Mansoura, Egypt; <sup>3</sup>Department of Genetics, Faculty of Veterinary Medicine, Mansoura University, 35516 El-Gomhoria Street, Mansoura, Egypt.

**Abstract** | Newcastle disease (ND) as a devastating disease is a challenge of poultry industry not only in developing countries, but also all over the world. The pathogenesis of ND in quails is still poorly understood. The present study aimed to investigate the natural occurrence and pathological changes of ND in quails in Egypt. The diseased quails were collected from eleven flocks in Egypt exhibited respiratory, nervous signs and whitish green diarrhea in addition to egg abnormalities and lower production with mortalities. No characteristic gross lesions were observed except hemorrhages in brain, congested liver, spleen, brain and muscles besides greenish content of the gizzard. The histopathological examination of lung, brain, liver, and trachea of these diseased quails revealed non-suppurative encephalitis, perivascular cuffing, congestion of hepatic sinusoids, degenerative changes in the hepatic cells and interstitial lymphocytic aggregations in the liver and focal pneumonic areas in the lung. Pooled samples from the investigated quails were inoculated in specific pathogen free embryonated chicken eggs (SPF-ECEs). The dead embryos showed hemorrhages, congestion and dwarfism. The collected allantoic fluids were examined later by haemagglutination (HA) and haemagglutination inhibition (HAI) test. The allantoic fluids of 5 pooled samples expressed positive using specific Newcastle disease virus (NDV) antiserum. The NDV field isolates were confirmed by reverse transcription polymerase chain reaction (RT-PCR) and partial sequencing targeting F gene of amplicon size (362) bp containing the region <sup>112</sup>RRQKRF<sup>117</sup> motif, which is the determinant part of virus virulence. The sequenced isolate was grouped in class II genotype VII.1.1 with small distance from NDV strains in chickens and turkeys which is alarming for the potential transmission of NDVs from quails to other poultry species.

**Keywords** | Newcastle disease, Quails, RT-PCR, F gene, Pathological changes, Class II genotype VII.1.1

**Received** | January 01, 2022; **Accepted** | March 14, 2022; **Published** | June 18, 2022

**\*Correspondence** | Sahar Abd El Rahman, Department of Virology; Faculty of Veterinary Medicine, Mansoura University, 35516 El-Gomhoria Street, Mansoura, Egypt; **Email:** sahar\_virolog@mans.edu.eg

**Citation** | LebDAH M, El-Rahman SA, Attia A, Karam R, Awad NFS, El-Bagoury MI (2022). Phylogenetic and histopathological characterization of newcastle disease virus (VII.1.1) recently isolated from naturally infected quails in Egypt. *Adv. Anim. Vet. Sci.* 10(7):1481-1491.

**DOI** | <https://dx.doi.org/10.17582/journal.aavs/2022/10.7.1481.1491>

**ISSN (Online)** | 2307-8316



**Copyright:** 2022 by the authors. Licensee ResearchersLinks Ltd, England, UK.

This article is an open access article distributed under the terms and conditions of the Creative Commons Attribution (CC BY) license (<https://creativecommons.org/licenses/by/4.0/>).

## INTRODUCTION

The Japanese quails have quick growth rate, short life cycle, short hatching period, high fecundity rate and

high protein and quality meat (Owen and Dike, 2013; Gecgel et al., 2015; El-Katcha et al., 2015). During the last few decades, the Japanese quails were widely used as table and pet birds as well as they can be used as experimental

birds (Ratnamohan, 1985). In Egypt, the introduction and rearing of this table bird have appeared since hundreds of years because they are less expensive, good source of animal-derived protein (Darwish et al., 2018) and more disease resistant than chickens (Yusuf et al., 2016).

Japanese quails are prone to some viral diseases either naturally; avian influenza (Arya et al., 2018) and infectious bronchitis (Fadhilah et al., 2020) or experimentally including Newcastle disease (Sharawi et al., 2015), quail bronchitis (Singh et al., 2016), inclusion body hepatitis (Singh et al., 1995), egg drop syndrome-76 (Mohapatra et al., 2014), Marek's disease (Adedeji et al., 2019), avian leukosis (Zhang et al., 2019), avian encephalomyelitis (Fan et al., 2017), avian pox (Gülbahar et al., 2005) and reticuloendotheliosis (Carlson et al., 1974). Few of these disease conditions have been investigated extensively.

Newcastle disease is regarded as one of the most important contagious viral diseases affecting the poultry industry (Miller and Koch, 2013). It affects over 240 different avian species (OIE, 2012). It poses threat to both vaccinated and non-vaccinated birds and has challenged all the biosecurity measures. It is the most infectious disease after avian influenza (Shittu et al., 2016). In chickens, it is characterized mainly by respiratory, digestive and nervous manifestations (Mishra et al., 2000). It causes also high morbidity and mortality rates, decrease egg quantity and quality resulting in significant financial economic losses (Orsi et al., 2009; Yan et al., 2011). While, quails are either considered susceptible host for NDV infection producing mild disease (OIE, 2014; Mohamed and Abdel Hafez, 2016) or NDV carriers (Lima et al., 2004).

Newcastle disease is caused by Newcastle disease virus (NDV), a member of the genus *Orthoavula* viruses, subfamily *Avulavirinae*, family *Paramyxoviridae*, and order *Mononegavirales* (Amarasinghe et al., 2019). Avian paramyxoviruses (APMVs) in wild and domesticated birds have recently been classified into 15 serotypes (APMV-I to APMV-XV) (Thomazelli et al., 2017). The NDV is a single-stranded, enveloped, negative sense RNA virus (Alexander and Senne, 1998). Only virulent APMV-I serotype strains are responsible for the disease. According to pathogenicity indexes, there are five pathotypes of NDV; velogenic viscerotropic viruses, which cause high morbidity, high mortality and hemorrhages in intestinal tract; velogenic neurotropic viruses, which cause nervous signs, respiratory signs and high mortality rates; mesogenic viruses cause low mortality rates, if not complicated with other pathogens, respiratory and nervous signs; lentogenic viruses which are used as a vaccine and asymptomatic enteric NDVs also used as a vaccine since they do not cause any clinical signs (Alexander and Jones, 2001; Mazinga, 2011).

Virulent NDV has an intracerebral pathogenicity index (ICPI) of 0.7 or higher or multiple basic amino acids between 112 and 116 residues at the C terminus of the F2 protein and phenylalanine at residue 117 (OIE, 2012). According to the genetic characters, NDV strains are divided into two categories: class I and class II. Non-virulent strains isolated from waterfowl and shorebirds are typically found in Class I, which is made up of a single genotype (Diel et al., 2012). Class II is subdivided into 21 genotypes (I-XXI) and multiple subgenotypes (Dimitrov et al., 2019). The most widely distributed NDV strains in chickens and quails all over the world and also in Egypt is genotype VII (Bhuvaneswari et al., 2014; Miller et al., 2015; Ewies et al., 2017; Megahed et al., 2018).

The main source of NDV infection in chickens is avian species that carry and shed the virus (Chukwudi et al., 2012). Quails could be a risk factor for NDV transmission to other poultry species, resulting in great economic losses (Lima et al., 2004; Sharawi et al., 2015). There are few data about the natural infection of quails with NDV in Egypt. Therefore, the present study aimed to isolate the current circulating NDVs from quails in Egypt using serological and molecular characterization in addition to observe the pathological changes induced by these field viruses in naturally infected quails.

## MATERIALS AND METHODS

### HISTORY OF THE EXAMINED FLOCKS AND SAMPLES COLLECTION

Under complete aseptic conditions, 33 quails representing 11 commercial diseased flocks (3 quails/flock) of various ages and breeds were collected. The investigated flocks' sizes ranged from 2000-10000 birds. They were mainly layers. All the quail flocks were not vaccinated against ND. Before samples collection and viral isolation trials, the quails were subjected for clinical and postmortem examinations. From each quail (liver, spleen, lung, trachea and brain) were collected under aseptic condition. All the collected tissues were expressed as 11 pooled samples (3 quails /flock/1 pool/1sample). The pooled samples were homogenized in 10% tissue suspensions. The homogenates were centrifuged at 1000rpm/10min in cooling centrifuge then the supernatants were collected and aliquoted. The antibiotics (penicillin at 2000 IU/ml and streptomycin at 2 mg/ml) were added to the supernatants to inhibit bacterial contamination (Numan et al., 2008; OIE, 2012).

### ECE INOCULATION

Two hundred specific pathogen free embryonated chicken egg (SPF-ECE supplied by Kom Osheim SPF farm; El-Fayoum Governorate) were used for propagation and

isolation of NDV from quails after natural infection. The supernatants of tissue pools homogenates, control negative and control positive (LaSota strain- NDV-CEVAC NEW L, Batch No, 1110A1LN2M) were separately inoculated into SPF-ECEs at 9-11 days via allantoic cavity route (five eggs were used per each sample) for three successive passages (0.2ml/each). The SPF-ECEs were candled for up to 7 days. Deaths within 24 hours were discarded as non-specific deaths. Following that, the eggs containing dead embryos were collected and chilled at 4°C overnight. Then, the allantoic fluids were harvested aseptically and any lesions found in the embryos or chorioallantoic membrane (CAM) was investigated (Alexander, 1989; OIE, 2008).

#### HEMAGGLUTINATION AND HEMAGGLUTINATION INHIBITION TEST

All harvested allantoic fluids, control positive (LaSota strain) and control negative samples were examined for HA activity by slide and microtiter plate HA using 10% and 1% washed chicken red blood cells (RBCs) concentrations, respectively as previously performed (Anon, 1963; OIE, 2012). The positive HA isolates were examined later by HI test using specific-rabbit antisera against NDV obtained from Virology Department, Faculty of Veterinary Medicine, Mansoura University. Hemagglutination inhibition test (HIT) was conducted for determination the titre of NDV in HA positive allantoic fluids as previously described (Alexander, 1989).

#### REVERSE TRANSCRIPTASE POLYMERASE CHAIN REACTION

The manufacturer's instructions were followed to extract viral RNA from the positive HI allantoic fluids, control positive (LaSota strain) and control negative using the QIAamp-MinElut virus spin kit. The RT-PCR was used to detect velogenic and lentogenic NDV strains by amplification of a 362 bp fragment of the NDV F gene using primers (A+B) at annealing temperature 52°C and to differentiate velogenic and lentogenic NDV strains by amplification of a 254 bp fragment of the NDV F gene for velogenic NDV strains only using primers (A+C) at annealing temperature 45°C. The primers' sequences were A: 5'-TTGATGGCAGGCCTCTTGC-3', B: 5'-GGAGGATGTTGGC AGC ATT-3' and C: 5'-AGCGT(C/T)TCTGTCTCCT-3) (Kant et al., 1997). According to the manufacturer's instructions, a one-step RT-PCR kit (enzymotics, South Korea) was used. 10µl 2x reaction buffer, 4µl extracted RNA, 0.8µl enzyme, 2µl of forward and reverse primers were mixed then nuclease free water was finally added up to 20µl. Cycling condition began with reverse transcription at 45°C/10 minutes by one cycle then inactivation and initial denaturation at 95°C/10 minutes for one cycle. Later, denaturation at 95°C/30 seconds, annealing at 52°C/30 seconds for A+B primer pair and

45°C/30 seconds for A+C primer pair and elongation at 72°C/1 minutes by 40 cycles. Final elongation at 72°C/10minutes by one cycle. The RT-PCR products were electrophoresed on agarose gel according to (Vögtlin et al., 1999). The specific bands (362 bp F gene fragment) for five selected PCR positive samples (sharp bands) and control positive (LaSota strain) were used for DNA sequencing. The DNAs were extracted from the agarose gel according to Lee et al. (2012). The extracted DNA targeting F gene (362 pb) was submitted to MACROGEN clinical laboratory, Korea. The nucleotide sequences of 362bp DNA of NDV F gene were used for phylogenetic analysis using alignment by MEGA X and bioedit software.

#### HISTOPATHOLOGICAL EXAMINATION

Tissue specimens from the lung, brain, liver, and trachea were fixed in 10% buffer formalin for 24 hours, transferred to a 70% ethanol solution, fixed in paraffin and processed using traditional methods as described previously (Kim, 2018). Tissue sections of fixed lesions were stained with hematoxylin and eosin and then examined microscopically for any changes in quails' organs.

### RESULTS AND DISCUSSION

#### CLINICAL AND POSTMORTEM FINDINGS

In most of the investigated quails, neither the clinical signs nor the gross lesions are diagnostic for ND. Notably, in eleven non-vaccinated quail flocks, most of the clinically examined birds were apparently healthy with no clinical signs. Meanwhile, few diseased quails showed signs in the form of depression, anorexia, sneezing, torticollis (Figure 1A), opisthotonos (Figure 1B), paralysis of one or two legs and whitish green diarrhea (Figure 1C). Additionally, to our knowledge, this is the first study to show reproductive problems in naturally infected quails, including a 25% decrease in egg production, thin shell or shell-less eggs, loss of pigmentation and easily broken eggs (Figure 1D). The morbidity and mortality rates in the investigated flocks were ranged from 1-90%. The main postmortem lesions were congested liver, spleen, brain and muscles besides the greenish contents of the gizzard (Figure 2). Also, pneumonia, consolidation of lung and emaciation were observed in some flocks (Table 1).

#### VIRUS ISOLATION, HEMAGGLUTINATION AND HEMAGGLUTINATION INHIBITION TEST

All collected samples prepared from naturally infected quails were inoculated into SPF- ECEs for three passages with homogenate tissue suspensions samples. The dead embryos showed hemorrhages, congestion and dwarfism (Figure 3A). The positive HA allantoic fluids were used for HI test using known antirabbit hyperimmune serum. The HI results expressed 5 positive samples for NDV (Table 2).

**Table 1:** Clinical and Postmortem Examination of quails collected from infected flocks.

Flock No.	Age	Mortality	Flock/capacity	Clinical signs					Postmortem lesions	
				Resp. signs	Ano- rexia	Diar- rhea	Nervous signs	Decrease in egg production	Intestinal ulcer	Congested liver, muscles and brain
1	2M	90%	3000	+	+	+	-	+	-	+
2	3M	↓1%	12000	-	-	-	+	+	-	+
3	4M	↓1%	4000	mild+	-	+	-	+	-	+
4	1M	↑90%	5000	+	+	+	-	-	-	+
5	2M	5%	4000	+	-	-	-	-	-	+
6	3M	↓1%	5000	+	-	+	-	+up to 25%	-	+
7	2M	↓1%	4000	-	-	-	+	+up to 25%	-	+
8	5M	↓1%	8000	-	-	+	-	+up to 25%	-	+
9	4M	↓1%	6000	-	-	+	-	-	-	-
10	2M	↑90%	2000	-	+	+	-	+	-	+
11	3M	↑90%	4000	-	+	+	-	+	-	+

**Table 2:** Descriptive data and NDV detection steps of the examined quail flocks.

Sample No	Mortalities in inoculated SPF-ECEs in the third passage	Serological identification by			Molecular characterization by RT-PCR	
		HA	HA Titre	log 2 HI	362 Bp fragment	254 Bp fragment
1	1 after 24 h 4 after 48 h	+	5	-	-	-
2	2 after 72 h 3 after 96 h	+	4	+	+	-
3	3 after 48 h 2 after 72 h	+	5	+	+	+
4	5 after 24 h	+	6	-	-	-
5	5 after 72 h	+	4	-	-	-
6	2 after 48 h 3 after 96 h	+	5	+	+	+
7	3 after 48 h 2 after 96 h	+	4	+	+	+
8	4 after 72 h 1 after 96 h	+	5	+	+	+
9	5 after 48 h	-	Nd	Nd	-	-
10	5 after 24 h	+	5	-	-	-
11	5 after 72 h	+	6	-	-	-
Total	55	10		5	5	4
C+ve		+	10		+	+
C-ve		-	-	-	-	-

Nd, means not done

### DETECTION OF NDV BY RT-PCR

Five positive HI allantoic fluids were confirmed by conventional RT-PCR and showed clear bands at 362 and 254 bp of the F gene fragment using primers A and B for all NDV pathotypes and using primers A and C for virulent NDV strains, respectively. The results revealed that 5 samples out of 11 examined samples (5/11; 45.45%) were virulent NDV field isolates (Table 2).

### SEQUENCING AND PHYLOGENETIC ANALYSIS

On gel electrophoresis, five samples were chosen for DNA sequencing from RT-PCR positive samples (clear bands).

The obtained sequence targeting the F gene at 362 bp fragment was designated as quail/Egypt/Zagazig/2021 and was deposited in GenBank as accession number OK310497 (Table 4). In addition, the identified sequence was compared to reference strains from GenBank that belonged to class II sub-genotypes VII.1.1, VII.1.2, and VII.2 of NDV (F gene sequences) (Table 3). The isolated field strain was found in sub-genotype VII.1.1 with other Egyptian strains. The sequencing of the 362-bp F gene revealed that one isolate had the 112 RRQKRF 117 motif, which is characteristic of virulent strains.

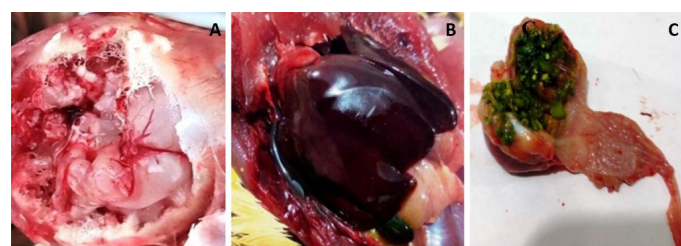


**Table 3:** Orthoavula viruses reference strains used in the phylogenetic tree.

Accession number	Strain	Year	% of nucleotides identity	Sub-genotype
OK310497	Quail/Egypt/Zagazig	2021	100%	VII 1.1
MW566177	Chicken/Egypt/QALUIBIA/NRC	2019	97.54%	VII 1.1
MG717683	quail/Egypt/SDU-2	2016	96.89%	VII 1.1
MN481243	Chicken/Egypt/ME4	2017	96.89%	VII 1.1
MH377309	turkey/isolate PHL255913	2016	96.89%	VII 1.1
MH377297	turkey/isolate PHL257758	2016	96.89%	VII 1.1
MH371065	turkey/isolate PHL245632	2016	96.89%	VII 1.1
KY075889	chicken/Egypt/Qualyobia26	2016	96.89%	VII 1.1
MW603771	Chicken/Egypt/KSH/VVTNRC	2021	96.89%	VII 1.1
MN481246	Chicken/Egypt/ME7	2016	96.58%	VII 1.1
MN481241	Chicken/Egypt/ME2	2017	96.58%	VII 1.1
MN481240	Chicken/Egypt/ME1	2016	96.58%	VII 1.1
MH377314.1	chicken/isolate PHL266018	2016	96.58%	VII 1.1
MH377313.1	chicken/isolate PHL265559	2016	96.58%	VII 1.1
MH377294.1	chicken/isolate PHL253817	2016	96.58%	VII 1.1
MG966505.1	chicken/Egypt/48Ob/NRC-CU	2014	96.58%	VII 1.1
KX686725.1	Egypt -GZ-339F	2015	96.58%	VII 1.1
KY075881.1	chicken/Egypt/Ismailia8	2016	96.58%	VII 1.1
MN481251.1	Chicken/Egypt/ME12	2014	96.27%	VII 1.1
MW580389.1	CHICKEN-EGY-ALEX-NRC	2020	96.27%	VII 1.1
MK495908.1	Chicken/Egypt/Qena/4	2012	98.7	VII 1.1
AY028995.1	China/CH-A7/96	1996	90.15%	VII 1.2
AF458010.1	chicken/China/JS-3/00	2000	90.15%	VII 1.2
AF140343	Chicken/China/LZ	1998	90.15%	VII 1.2
GQ338309	Pigeon/China/03/018	2003	90.15%	VII 1.2
KY747481	Chicken/Namibia/6196	2016	88%	VII.2
KY747482	Chicken/Namibia/6403	2016	87.69%	VII.2



**Figure 1:** Clinical signs in naturally infected quails 2 months age from Egypt: (A, B) Nervous signs including torticollis and opisthotonos; (C) Digestive disorder including whitish and greenish diarrhea; (D) Deterioration of egg including broken, thin shell and loss of pigmentation.

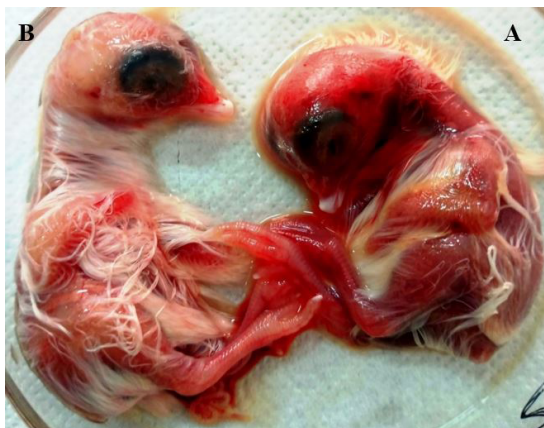

**Figure 2:** Post-mortem changes in naturally infected quails (2 months age) from Egypt: (A) Engorged blood vessels, congestion and hemorrhages in brain; (B) Severe congestion in the liver; (C) Greenish contents of the gizzard.

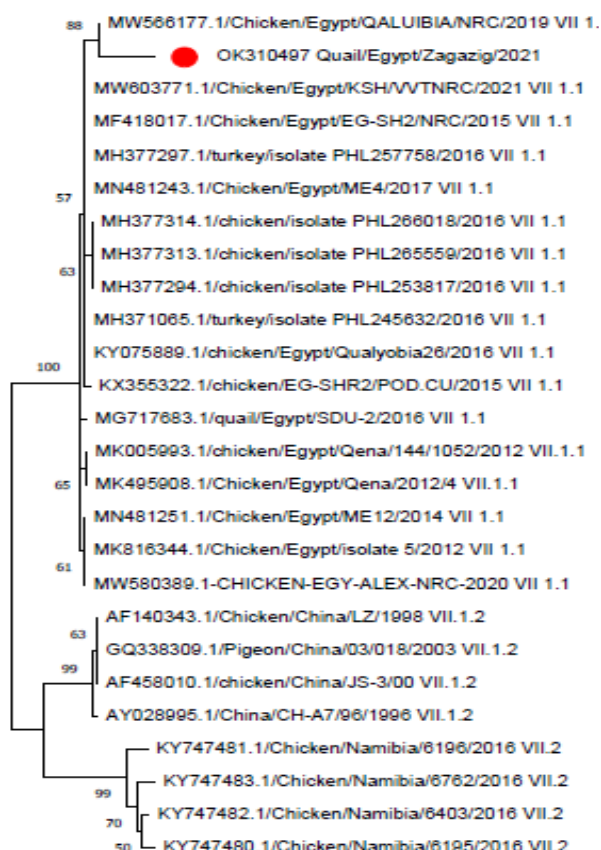
The isolated strain was closely related to strains of NDV sub-genotype VII 1.1 including the QALUIBIA/NRC/2019, ME4/2017, turkey/isolate PHL257758/2016, turkey/isolate PHL245632/2016 and EG-SH2/NRC (Table 3). The nucleotide sequence of the present strain quail/Egypt/Zagazig/2021 showed high identity percent as 97.54% with QALUIBIA/NRC/2019, then 96.89%



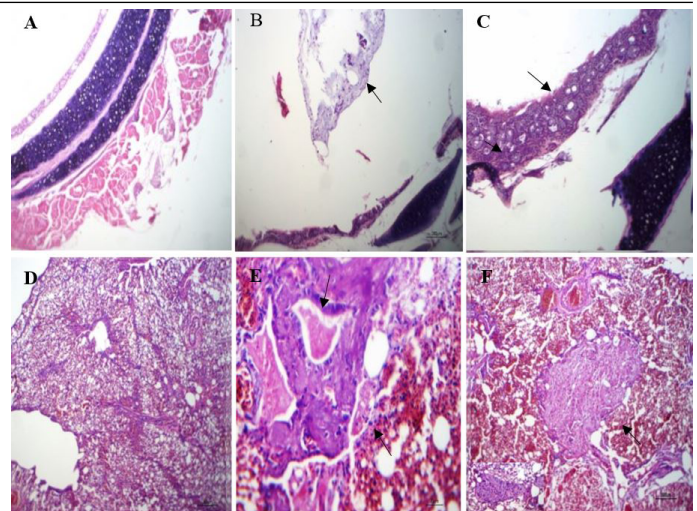
identity with the Egypt/ ME4/2017, turkey/ isolate PHL257758/2016, turkey/ isolate PHL245632/2016, EG-SH2/NRC, Qualyobia26/ 2016 and EGY-KSH-VVTNRC-2021 (Tables 3, 4, Figures 4, 5).



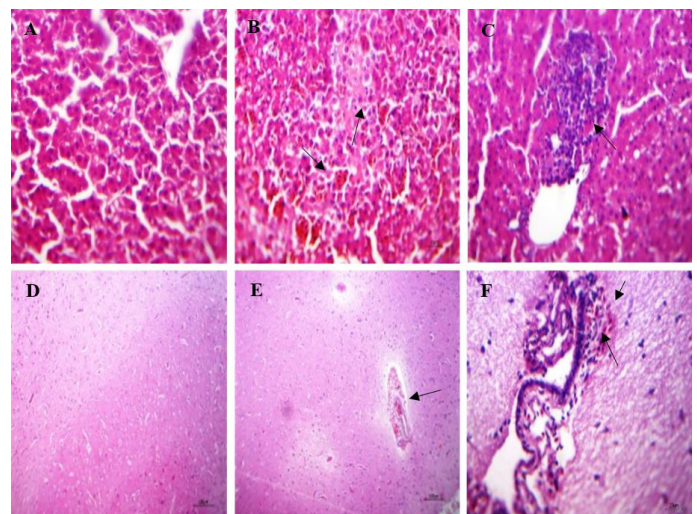
**Figure 3:** The inoculation of the supernatant of tissue suspension prepared from pooled organs of naturally infected quails into the allantoic cavities of 10-day-specific pathogen free-embryonated chicken eggs (A) Embryo showing congestion, dwarfism and sub-cutaneous hemorrhages on the head and legs and (B) The negative control embryo.



**Figure 4:** Phylogenetic analysis of NDV F gene fragment sequences through a bootstraps trail of 1000 was determined with the MEGA X using neighbor-joining method for tree construction. Our strain was labeled as red circle and was aligned with other strains of sub genotype.



**Figure 5:** Histopathological lesions in the trachea and lungs of naturally infected quails: (A) trachea of normal quail (non-infected) showing normal wall and lumen, (HE, x100); (B) trachea of infected quail with NDV showing mucus exudate inside tracheal lumen (arrow), (HE, x100); (C) trachea of infected quail with NDV showing thickened tracheal wall by leukocyte (arrow) and proliferative glands (arrow head), (HE, x400); (D) lung of normal quail showing normal pulmonary tissue, (HE, x100); (E) lung of infected quail with NDV showing bronchial exudate (arrow), necrosed muscles (arrow head) and sero fibrinous fluid in adjacent air vesicle, (HE, x400); (F) lung of infected quail with NDV showing focal pneumonic area fibroblasts, macrophages and giant cells within pulmonary exudate (arrow), (HE, x100).



**Figure 6:** Histopathological lesions in the liver and brain of naturally infected quails; (A) liver of normal quail showing normal hepatic parenchyma, (HE, x400); (B) liver of infected quails with NDV showing intense sinusoidal congestion, large area of coagulative necrosis containing erythrocytes apoptosis (arrow) and minute necrosis of the hepatic parenchyma, (HE, x400); (C) liver of infected quails with NDV showing interstitial lymphocytic aggregation, (HE, x400); (D) brain of normal quail showing apparently normal brain tissue, (HE, x100) (E) brain of infected quails with NDV showing perivascular hemorrhages in Virchow robin spaces and non-suppurative encephalitis. besides, hemorrhages in meninges, (HE, x100); (F) brain of infected quails with NDV showing sub meningeal lymphocytic infiltration, extra vasated erythrocytes and edema, (HE, x400).

**Table 4:** OK310497 Quail/Egypt/Zagazig and sub genotype type VII 1.1 - specific residue substitutions in the deduced F nucleotide sequence.

Strain / Position	35	43	47	94	104	153	196
Majority	T	A	T	A	G	T	C
MW566177.1/Chicken/Egypt/QALUIBIA/NRC	.	.	.	.	.	.	.
OK310497 Quail/Egypt/Zagazig	G	G	G	C	C	C	A
MG717683.1/quail/Egypt/SDU-2	.	.	.	.	.	.	.
MN481243.1/Chicken/Egypt/ME4	.	.	.	.	.	.	.
MH377309.1/turkey/isolate PHL2	.	.	.	.	.	.	.

The mark (.) means the same nucleotide.

**Table 5:** The first comparison of histopathological features between naturally infected quails with NDV VII and healthy quails.

Affected organ	Lesions	Healthy quail	Naturally infected quails
Brain	Non suppurative encephalitis	—	++
	Homorrhage and hyperemia in meninges	—	+++
	Degenerated neuron	—	++
	Encephalomalacia and gliosis	—	++
Liver	congestion of hepatic sinusoids	—	+++
	coagulative necrosis of the hepatic parenchyma	—	+
	portal cholestasis degenerative changes in the hepatic cells	—	++
	interstitial lymphocytic aggregation	—	++
Lung	focal pneumonic areas	—	++
	organization	—	++
	hemorrhage and hemosiderosis	—	+
Trachea	Tracheitis	—	++
	epithelial destruction	—	++

## HISTOPATHOLOGICAL CHANGES

The trachea of the naturally infected quails showed mucous exudate in the tracheal lumen admixed with a few leukocytes and erythrocytes (Figure 5B). Additionally, thickened tracheal wall (tracheitis), infiltration of leukocytes mainly lymphocytes, proliferative glands and partial epithelial destruction (Figure 5C). The lungs of the examined quails exhibited inflammatory exudate varied from sero-fibrinous to caseous with or without heterophils and erythrocytes in the bronchial lumen and peribronchial air vesicles together with hypertrophy and necrosis of the bronchial smooth muscles (Figure 5E). Focal pneumonic areas consisted of necrotic debris, living and degenerated heterophils were scattered within the lung tissues besides necrotic tissues invaded by fibroblasts together with macrophages and giant cells (organization) (Figure 5F).

The liver of the investigated quails showed intense congestion of hepatic sinusoids together with degenerative changes (micro steatosis), apoptosis and minute coagulative necrosis of the hepatic parenchyma (Figure 6B). Other birds had interstitial lymphocytic aggregation with various degenerative changes in the hepatic cells (Figure 6C). The quails with nervous signs had a picture of non-suppurative encephalitis, hemorrhages in meninges and Virchow robin spaces (perivascular) and perivascular edema (Figure

6E). Additionally, the mid brain mainly cerebellum had degenerated Purkinjean neurons along with meningeal blood vessels usually hyperemic with a few extravasated erythrocytes, lymphocyte and edema in sub meningeal tissues (Figure 6F).

## DISCUSSION

In the current work, few naturally infected quails revealed whitish green diarrhea, neurological signs. This result was compatible with Moustafa et al. (1983). Respiratory signs were mild in some farms and absent in others. This was in agreement with Abd-el-Latif et al. (2009) and to our knowledge, it is the first report to show reproductive disorders in the form of drop in egg production reached 25%, thin shell or shell-less eggs, loss of pigmentation and easily broken eggs in naturally infected quails with low mortality and morbidity not exceed 1%. Postmortem examinations revealed congested brain, liver, lung and spleen in addition to greenish content of the gizzard. There was absence of the pathognomonic lesions which are present in the chicken such as hemorrhage of proventriculus, ulcer of intestine and hemorrhage in cecal tonsils. These results were in accordance with Lima et al. (2004). Based on these findings, it could be concluded that APMV-I pathogenicity in quails differs from that in domestic



chickens. These findings come in agreement with [Abd-el-Latif et al. \(2009\)](#) who found, nervous manifestations and mild respiratory signs with 1.6% mortalities in a 3 week-old quail flock containing 5000 birds. Similarly, [Momayez et al. \(2007\)](#) found diarrhoea, nervous signs, morbidity of more than 10% and mortality of about 5% in a flock of 1500 quails aged 1 day, 3 weeks, 6 weeks, and 3-6 months in Tehran province, Iran, without NDV vaccination. [Czirjak et al. \(2007\)](#), on the other hand, reported that in a natural outbreak of ND, the morbidity and mortality rates were 100%. Also, [Lima et al. \(2004\)](#) found no clinical signs or mortality in experimentally infected quails.

The birds, submitted for histopathological examination in this study, showed microscopic changes in the brain including non-suppurative encephalitis, perivascular edema, degenerated neurons, and neuronophagia with early encephalomalacia besides gliosis. These results were in accordance with those of [Susta et al. \(2018\)](#). In addition to, thickened tracheal wall (tracheitis) by infiltrating leukocytes mainly lymphocytes and epithelial discontinuation were also recorded. This was in agreement with [Ayooob et al. \(2019\)](#).

Regarding to viral isolation, all collected samples were inoculated via allantoic cavity route in SPF-ECEs, NDV suspected samples caused congestion, hemorrhagic lesions and death of the embryo within 96 hours of inoculation ([OIE, 2012](#)). All of the samples came from flocks that had not been vaccinated against Newcastle. The HA titers for the tested allantoic fluids were low, indicating that the quails could be carriers for NDV and spread the virus to other poultry species, particularly domestic chickens, which are highly susceptible to NDV. This was consistent with the findings of [Sa'idu et al. \(2004\)](#), who found low HA titers in quails.

The results of the HI test for NDV detection were confirmed by the RT-PCR test and agreed with those of [Munir et al. \(2012\)](#). To identify, portray and pathotype the isolated NDVs, researchers used a molecular diagnostic technique called RT-PCR, which uses Taq polymerase enzyme and forward and reverse specific primers ([Tan et al., 2008](#)). Five isolates from extracted viral RNA from the allantoic fluid of 11 samples representing 11 quail flocks revealed five clear bands at the correct expected size (362 bp) for NDV on electrophoresis ([El-Bagoury et al., 2015](#)). The 362-bp fragment of the F gene, which is conserved in all NDVs pathotypes, was amplified using the A+B primer set for preliminary NDV identification ([Kant et al., 1997](#)). The NDV characterization and surveillance are currently carried out using reverse transcriptase polymerase chain reaction (RT-PCR) amplification of the partial coding region of the F gene, followed by sequencing and phylogenetic analysis of the fusion protein gene cleavage

site ([Khan et al., 2010](#)). The pathogenicity of NDV is initially determined by the amino acid sequence of the fusion protein cleavage site and the cellular protease that cleaves the fusion proteins ([Nagai et al., 1976](#)).

It was critical to pathotype and genotype the circulating virus in these flocks. The OIE defines Newcastle disease as an infection of birds caused by a virus (NDV) of the avian paramyxovirus serotype 1 (APMV-1) that meets one of the virulence criteria listed below: The virus has an intracerebral pathogenicity index (ICPI) of more than 0.7 in day-old chicks or at least three basic amino acids between residues 112 and 117, particularly arginine (R) or lysine (K). The OIE defined virulent NDV strains as mesogenic and velogenic strains that met the OIE criteria ([Miller and Koch, 2013](#)).

To characterize NDV strains, most laboratories and researchers now use genome sequence phylogenetic analysis. Because of the importance of the F gene in determining virulence, the first studies focused on partial F gene sequences ([Aldous et al., 2003](#); [Collins et al., 2007](#); [Diel et al., 2011](#)). The molecular virulence determination is sufficient with a partial fusion protein of 274 base pairs (bp) in length surrounding the site where the F0 precursor is cleaved into F1 and F2 fragments ([OIE, 2009](#)). According to the genome length and F gene sequence within APMV-1, NDV isolates are divided into two classes: class I (nine genotypes) and class II (twenty-one genotypes) ([Dimitrov et al., 2019](#)). The identified strain in the present study (quail/Egypt/Zagazig/2021) is clustered in class II, genotype VII and sub genotype VII 1.1 with other Egyptian strains. The Egyptian NDV sub genotype VII.1.1 strains isolated from chickens and turkeys in various Egyptian provinces are strikingly similar to our sequenced strain. This was done in line with the findings of [Radwan et al. \(2013\)](#), who found that sub genotype VII 1.1 is the most common NDV sub genotype in Egypt. The antigenic and genetic comparison of the isolated NDV strain from quails to strains from chickens and turkeys could indicate a possible role of quail and wild birds in disease transmission ([Brown and Bevins, 2017](#)). Analysis of the quails' strain isolated from Egypt revealed that they are somewhat divergent, with 3.73% pairwise distance between the quail/Egypt/SDU-2/2016 (VII.1.1) and our isolate quail/Egypt/Zagazig/2021. These findings showed that Egyptian quail-bird-origin NDV strains can infect commercial poultry, highlighting the need for biosecurity assessments, vaccination, and ongoing surveillance, as well as revised vaccine approaches. The findings revealed a significant rate of mutation among circulating NDVs in recent years.



In conclusion, sub-genotype VII.1.1 strains of NDV are the currently circulating strains among quails' flocks in Egypt. Phylogenetically, NDVs in quails are closely related to NDV in chickens and turkeys which carry the virulent motif of F protein cleavage site 112 RRQKRF 117 reflecting the high possibility of virus exchange between different avian species. Unfortunately, there is no vaccination against NDV in quail flocks in Egypt. Therefore, the biosecurity and proper vaccination with newly isolated mutated viruses against NDV is recommended. Further large-scale surveillance is required to identify the development of the NDV in quails and use the appropriate vaccination.

## ACKNOWLEDGEMENTS

The authors gratefully acknowledge Prof. Dr. Adel Zaghloul, the Department of Surgery, Anesthesiology and Radiology, Faculty of Veterinary Medicine, Mansoura University, Egypt, and Dr. Tamer Abdullatif, Department of Avian and Rabbit Medicine, Faculty of Veterinary Medicine, Zagazig University, for technical and scientific support.

## AUTHOR'S CONTRIBUTION

All authors contributed equally.

## CONFLICT OF INTEREST

The authors have declared no conflict of interest.

## REFERENCES

Abd-el-Latif NMR, El-Tarabili, MMA, El-Shahiedy, MSM, Hammouda MSM (2009). Studies on Newcastle disease virus in quails. Ph.D. thesis, Virology, Faculty of Veterinary Medicine, Suez Canal University.

Adedeji AJ, Akanbi OB, Luka PD, Abdu P (2019). Natural outbreak of Marek's disease in indigenous chicken and Japanese quail (*Coturnix coturnix japonica*) in Jos, Plateau State, Nigeria. *Open Vet. J.*, 9(2): 151- 156. <https://doi.org/10.4314/ovj.v9i2.10>

Aldous EW, Mynn JK, Banks J, Alexander DJ (2003). A molecular epidemiological study of avian paramyxovirus type 1 (Newcastle disease virus) isolates by phylogenetic analysis of a partial nucleotide sequence of the fusion protein gene. *Avian Pathol.*, 32(3): 239-257. <https://doi.org/10.1080/030794503100009783>

Alexander DJ (1989). Newcastle Disease. In: (eds. H.G. Purchase, L.H. Arp, C.H. Domermuth and J.E. Pearson). A laboratory manual for the isolation and identification of avian pathogens, 3<sup>rd</sup> eds, Kennett Square, PA: American Association of Avian pathologists, pp. 114-120.

Alexander DJ, Jones RC (2001). Paramyxoviridae. In: Poultry

diseases, (eds. F. Jordan, M. Pattison, D. Alexander and T. Faragher). 5<sup>th</sup> Edition., W.B. Saunders. London. pp. 257-267.

Alexander DJ, Senne DA (1998). Newcastle disease and other avian paramyxoviruses. In: (eds. Swayne DE, Glisson JR, Jackwood MW). A Laboratory Manual for the Isolation, Identification and Characterization of Avian Pathogens. 4<sup>th</sup> ed. Kennett Square, IA: American Association of Avian Pathologists, pp. 156-163.

Amarasinghe GK, Ayllón MA, Bào Y, Basler CF, Bavari S, Blasdel KR, Briese T, Brown PA, Bukreyev A, Balkema-Buschmann A, Buchholz UJ, Chabi-Jesus C, Chandran K, Chiapponi C, Crozier I, de Swart R, Dietzgen RG, Dolnik O, Drexler JF, Dürrwald R, Dundon WG, Duprex WP, Dye JM, Easton AJ, AR Fooks, Formenty PBH, Fouchier RAM, Freitas-Astúa J, Griffiths A, Hewson R, Horie M, Hyndman TH, Jiang D, Kitajima EW, Kobinger GP, Kondō H, Kurath G, Kuzmin IV, Lamb RA, Lavazza A, Lee B, Lelli D, Leroy EM, Li J, Maes P, Marzano SL, Moreno A, Mühlberger E, Netesov SV, Nowotny N, Nyland A, Økland AL, Palacios G, Pályi B, Pawęska JT, Payne SL, Prosperi A, Ramos-González PL, Rima PK, Rota P, Rubbenstroth D, Shi M, Simmonds P, Smither SK, Sozzi E, Spann K, Stenglein MD, Stone DM, Takada A, Tesh RB, Tomonaga K, Tordo N, Towner JS, Hoogen B, Vasilakis N, Wahl V, Walker PJ, Wang L, Whitfield AE, Williams JV, Zerbini FM, Zhāng T, Zhang YZ, Kuhn JH (2019). Taxonomy of the order Mononegavirales: Arch. Virol., 164: 1967-1980. <https://doi.org/10.1007/s00705-019-04247-4>

Anon (1963). Methods for the Examination of poultry biologics national academy of science national research council Washington D.C. publication 705 (2<sup>nd</sup> ed).

Arya K, Gupta R, Saxena VL (2018). Quail survey: Elaborative information and its prospects. *Res. J. Life Sci. Bioinf. Pharm. Chem. Sci.*, 4(4): 209.

Ayoob MF, Nizamani ZA, Kamboh AA, Ayoob, M, Vistro WA, Baloch A (2019). Pathology of induced Velogenic Viscerotropic Newcastle Disease (VVND) in Japanese Quail and Myna. *Pak. J. Zool.*, 53(2): 1-7.

Bhuvaneswari S, Tirumurugan KG, Jones JC Kumanan K (2014). Complete genome sequence of a Newcastle disease virus from a *Coturnix coturnix japonica* (Japanese Quail) covey in India. *Genome Announc.*, 2(3): e00374-e00314. <https://doi.org/10.1128/genomeA.00374-14>

Brown VR, Bevins SN (2017). A review of virulent Newcastle disease viruses in the United States and the role of wild birds in viral persistence and spread. *Vet. Res.*, 48: 68. <https://doi.org/10.1186/s13567-017-0475-9>

Carlson, HC, Seawright GL, Pettit JR (1974). Reticuloendotheliosis in Japanese quail. *Avian Pathol.*, 3: 169-175. <https://doi.org/10.1080/03079457409353829>

Chukwudi OE, Chukwuemeka ED, Mary U (2012). Newcastle disease virus shedding among healthy commercial chickens and its epidemiological importance. *Pak. Vet. J.*, 32: 354-356.

Collins MS, Franklin S, Strong I, Meulemans G, Alexander DJ (2007). Antigenic and phylogenetic studies on a variant Newcastle disease virus using anti-fusion protein monoclonal antibodies and partial sequencing of the fusion protein gene. *Avian Pathol.*, 27: 90-96. <https://doi.org/10.1080/03079459808419279>

Czirjak GA, Kobolkuti LB, Cadar D, Ungvari A, Niculae

- M, Bolfa P (2007). An outbreak of Newcastle disease in Japanese quail (*Coturnix coturnix japonica*). Bull. USAMV-CN., 64: 589-589.among healthy commercial chickens and its epidemiological importance. Pak. Vet. J., 32: 354-356.
- Darwish WS, Atia AS, Khedr MHE, Eldin WFS (2018). Metal contamination in quail meat: residues, sources, molecular biomarkers, and human health risk assessment. Environ. Sci. Pollut. Res. Int., 25(20): 20106-20115.
- Diel DG, Susta L, Garcia SC, Killian ML, Brown CC, Miller PJ, Afonso CL (2011). Complete genome and clinicopathological characterization of a virulent Newcastle disease virus isolated from poultry in South America. J. Clin. Microbiol., 50: 378-387.
- Diel DG, da Silva LH, Liu H Wang Z, Miller PJ, Afonso MC(2012). Genetic diversity of avian paramyxovirus type 1: proposal for a unified nomenclature and classification system of Newcastle disease virus genotypes. Infect. Genet. Evol., 12(8): 1770-1779.
- Dimitrov KM, Abolnik C, Afonso CL, Albina E, Bahl J, Berg M, Briand FX, Brown IH, Choi KS, Chvala I, Diel DG, Durr PA, Ferreira HL, Fusaro A, Gil P, Goujgoulova GV, Grund C, Hicks JT, Joannis TM, Torchetti MK, Kolosov S, Lambrecht B, Lewis NS, Liu H, Liu H, McCullough S, Miller PJ, Monne I, Muller CP, Munir M, Reischak D, Sabra M, Samal SK, Servan de Almeida R, Shittu I, Snoeck CJ, Suarez DL, Van Borm S, Wang Z, Wong FYK (2019). Updated unified phylogenetic classification system and revised nomenclature for Newcastle disease virus. Infect. Genet. Evol., 74: 103917. <https://doi.org/10.1016/j.meegid.2019.103917>
- El-Bagoury GF, El-Adaway SF, El-Habbab AS, El-Mahdy, SS (2015). Isolation, identification and pathotyping of Newcastle disease virus from chickens in Egypt. Benha Vet. Med. J., 29(1): 196-204. <https://doi.org/10.21608/bvmj.2015.31819>
- El-Katcha MI, Soltan M, Ramdan SS, El Naggar MK, El-Shobokshy SA (2015). Growth performance, blood biochemical changes, carcass traits and nutrient digestibility of growing Japanese quail fed on various dietary protein and calcium levels. Alex. J. Vet. Sci., 44(1): 38-53. <https://doi.org/10.5455/ajvs.171987>
- Ewies SS, Ali A, Tamam SM, Madbouly HM (2017). Molecular characterization of Newcastle disease virus (genotype VII) from broiler chickens in Egypt. Beni-Suef Univ. J. Basic Appl. Sci., 6(3): 232-237.
- Fadhilah AS, Kai TH, Lokman HI, Yasmin NAR, Hafandi A, Hasliza AH, Tengku Rinalfi TA, Hezmee MNM (2020). Molecular and pathogenicity of infectious bronchitis virus (Gamma coronavirus) in Japanese quail (*Coturnix japonica*). Poult. Sci., 99(6): 2937-2943. <https://doi.org/10.1016/j.psj.2020.01.026>
- Fan L, Li Z, Huang J, Yang Z, Xiao S, Wang X, Dang R, Zhang S (2017). Dynamic distribution and tissue tropism of avian encephalomyelitis virus isolate XY/Q-1410 in experimentally infected Korean quail. Arch. Virol., 162(11): 3447-3458. <https://doi.org/10.1007/s00705-017-3504-0>
- Gegel U, Yilmaz I, Gurcan EK, Karasu S, Dulger GC (2015). Comparison of fatty acid composition between female and male Japanese quail meats. J. Chem. , 2015, Article ID 569746, 8 pages. <https://doi.org/10.1155/2015/569746>
- Gülbahar MY, Çabalar M, Boynukara B (2005). Avipoxvirus infection in quails. Turk. J. Vet. Anim. Sci., 29: 449-454.
- Kant A, Koch G, Van Roozelaar DJ, Balk F, Huurde AT (1997). Differentiation of virulent and non-virulent strains of Newcastle disease virus within 24 hours by polymerase chain reaction. Avian Pathol., 26: 837-849. <https://doi.org/10.1080/03079459708419257>
- Khan TA, Rue CA, Rehmani SF, Ahmed A, Wasilenko JL, Miller PJ, Afonso CL (2010). Phylogenetic and biological characterization of Newcastle disease virus isolates from Pakistan. J. Clin. Microbiol., 48: 1892-1894. <https://doi.org/10.1128/JCM.00148-10>
- Kim S (2018). Bancroft's theory and practice of histological techniques, 7<sup>th</sup> Edition. Churchill Livingstone, Elsevier, England, pp. 254-279.
- Lee PY, Costumbrado J, Hsu CY, Kim YH (2012). Agarose Gel Electrophoresis for the separation of DNA Fragments. J. Vis. Exp., 62: Le3932. <https://doi.org/10.3791/3923>
- Lima FS, Satin E, Paulillo AC, Doretto L, Barbosa de Mordes VM, Hurrino RP (2004). Japanese quail (*Coturnix coturnix japonica*) as Newcastle disease virus carrier. Int. J. Sci., 3: 383-484. <https://doi.org/10.3923/ijps.2004.483.484>
- Mazinga H (2011). Review on viral diseases of chickens reported in Ethiopia. J. Infect. Dis. Immun., 4(1): 1-9. <https://doi.org/10.5897/JIDIX11.001>
- Megahed MM, Eid AAM, Mohamed W, Hassanin O (2018). Genetic characterization of Egyptian Newcastle disease virus strains isolated from flocks vaccinated against Newcastle disease virus, 2014-2015. Slov. Vet. Res., 55(suppl 20): 17-29.
- Miller PJ, Haddas R, Simanov L Lublin A, Rehmani SF, AbdulWajid, , Bibi T, Khan TA, Yaqub, T., Setiyaningsih, S., and Afonso, C.L (2015). Identification of new sub-genotypes of virulent Newcastle disease virus with potential panzootic features. Infect. Genet. Evol., 29: 216-229. <https://doi.org/10.1016/j.meegid.2014.10.032>
- Miller PJ, Koch G (2013). Newcastle disease. In: Diseases of poultry (eds. Swayne, D.E., Glisson, J.R., McDougald, L.R., Nolan, L.K., Suarez, D.L., Nair, V.L.). 13<sup>th</sup> edition. Ames, IA: Wiley-Blackwell in partnership with the American Association of Avian Pathologists. pp. 89-107, 120-130.
- Mishra S, Kataria JM, Verma KC, Shah RI (2000). Response of chickens to infection with Newcastle disease virus isolated from guinea fowl. Trop. Anim. Hlth. Prod., 32: 277-284. <https://doi.org/10.1023/A:1005260806046>
- Mohamed MA, Abdel Hafez MS (2016). The susceptibility of Japanese quails to the infection with chicken originated newcastle disease virus. J. Adv. Vet. Res., 6(1): 37-43.
- Mohapatra N, Kataria JM, Chakraborty S, Dhama K (2014). Egg drop syndrome-76 (EDS-76) in Japanese quails (*Coturnix coturnix japonica*): An experimental study revealing pathology, effect on egg production/quality and immune responses. Pak. J. Biol. Sci., 17(6): 821-828. <https://doi.org/10.3923/pjbs.2014.821.828>
- Momayez R, Gharakhani P, Pourbakhsh SA, Toroghi R, Shoushtari AH, Banani M (2007). Isolation and pathogenicity identification of avian paramyxovirus serotype 1 (Newcastle disease) virus from a Japanese quail flock in Iran. Arch. Razi Inst., 62(1): L 39-44.
- Moustafa MMA, Saad FE, Saber MS, Amin AA (1983). Studies on Newcastle in quails. Ph.D. thesis, Poultry Diseases, Faculty of Veterinary Medicine, Cairo University.
- Munir S, Hussain M, Farooq U, ZabidUllah, Jamal Q, Afreen M, Bano K, Khan, J, Ayaz, S, Kim KY, Anees M (2012). Quantification of antibodies against poultry haemagglutinating viruses by haemagglutination inhibition

- test in Lahore. Afr. J. Microbiol. Res., 6(21): 4614-4619. <https://doi.org/10.5897/AJMR12.585>
- Nagai Y, Klenk H-D, Rott R (1976). Proteolytic cleavage of the viral glycoproteins and its significance for the virulence of Newcastle disease virus. Virology, 72: 494-508. [https://doi.org/10.1016/0042-6822\(76\)90178-1](https://doi.org/10.1016/0042-6822(76)90178-1)
- Numan M, Siddique M, Shahid MA, Yousaf MS (2008). Characterization of isolated avian influenza virus. J. Vet. Anim. Sci., 1: 24-30. <https://doi.org/10.1159/000151612>
- OIE (2008). OIE World Organization for Animal Health. Manual of Diagnostic Tests and Vaccines for Terrestrial Animals. 6<sup>th</sup> ed. Paris.
- OIE (2009). Manual of diagnostic tests and vaccines for terrestrial animals: Mammals, birds and bees. Biological Standards Commission, Vol. 1, Part 2, Chapter 2.3.14. OIE, Paris. 576-589.
- OIE (2012). Newcastle disease, Biological Standards Commission, Manual of diagnostic tests and 921 vaccines for terrestrial animals: mammals, birds and bees, 7<sup>th</sup> Ed.
- OIE (2014). Animal Health Australia. Disease strategy: Newcastle disease (Version 3.3). Australian Veterinary Emergency Plan (AUSVETPLAN), Edition 3, Agriculture Ministers' Forum, Canberra, ACT.
- Orsi MA, Doretto JL, Reischak D, da Silva LH, Spilki DR, Buzinaro MG, Arns CW (2009). Newcastle disease virus vaccine strains: Immunogenicity is not influenced by ICPI. Braz. J. Poult. Sci., 11: 129-133. <https://doi.org/10.1590/S1516-635X2009000200009>
- Owen OJ., Dike UA (2013). Japanese quail (*Coturnix coturnix japonica*) husbandry: A means of Increasing Animal Protein Base in Developing Countries. J. Environ. Issues Agric. Dev. Count., 5(1): 1-4.
- Radwan MM, Darwish SF, El-Sabagh IM, El-Sanousi AA, Shalaby MA (2013). Isolation and molecular characterization of Newcastle disease virus genotypes II and VII d in Egypt between 2011 and 2012. Virus Genes, 47(2): 311-316. <https://doi.org/10.1007/s11262-013-0950-y>
- Ratnamohan N (1985). The management of Japanese quail and their use in virological research: A review. Vet. Res. Commun., 9: 1-14. <https://doi.org/10.1007/BF02215123>
- Sa'idu L, Tekdek LB, Abdu PA (2004). Prevalence of Newcastle disease antibodies in domestic and semi-domestic birds in Zaria, Nigeria. Vet. Arhiv., 74: 309-317.
- Sharawi S, El-Habbab AS, Zaied HM, Khodeir MH (2015). Experimental infection of quail by NDV and its immune response to vaccination. Benha Vet. Med. J., 29(2): 218-224. <https://doi.org/10.21608/bvmj.2015.31712>
- Shittu I, Joannis TM, Odaibo GN, Olaleye OD (2016). Newcastle disease in Nigeria: epizootiology and current knowledge of circulating genotypes. Virus, 27(4): 329-339. <https://doi.org/10.1007/s13337-016-0344-6>
- Singh A, Bekele AZ, Patnayak DP, Jindal N, Porter RE, Mor SK, Goyal SM (2016). Molecular characterization of quail bronchitis virus isolated from Bobwhite quail in Minnesota. Poult. Sci., 95: 2815-2818. <https://doi.org/10.3382/ps/pew217>
- Singh A, Oberoi MS, Singh B (1995). Pathogenicity in quail's inclusion body hepatitis virus (avian adenovirus-1) for Japanese quails and broiler chicks. Vet. Res. Commun., pp. 545-551. <https://doi.org/10.1007/BF01839342>
- Susta L, Segovia D, Olivier, Dimitrov KM, Shittu I, Marcano V, Miller PJ (2018). Newcastle disease virus infection in quail. Vet. Pathol., 55(5): 682-692. <https://doi.org/10.1177/0300985818767996>
- Tan LT, Xu HY, Wang YL, Qin ZM, Sun L, Liu WJ, Cui ZZ (2008). Molecular characterization of three new virulent Newcastle disease virus variants isolated in China. J. Clin. Microbiol., 46: 750-753. <https://doi.org/10.1128/JCM.01587-07>
- Thomazelli LM, de Araújo J, Fabrizio T, Walker D, Reischak D, Ometto T, Barbosa CM, Petry MV, Richard J. Webby RJ, Durigon EL (2017). Novel avian paramyxovirus (APMV-15) isolated from a migratory bird in South America. PLoS One, 12(5): e0177214. <https://doi.org/10.1371/journal.pone.0177214>
- Vögtlin A, Bruckner L, Ottiger HP (1999). Use of polymerase chain reaction (PCR) for the detection of vaccine contamination by infectious laryngotracheitis virus. Vaccine, 17: 20-21, 2501-2506. [https://doi.org/10.1016/S0264-410X\(99\)00068-7](https://doi.org/10.1016/S0264-410X(99)00068-7)
- Yan Z, Du Y, Zhao Q, Fan R, Guo W, Ma R, Wang X, Zhu R (2011). Mucosal immune responses against live Newcastle disease vaccine in immunosuppressed chickens. Pak. Vet. J., 31: 280-286.
- Yusuf MS, El Nabiti AS, Cui H (2016). Effects of NENP vs LELP diets on some laying and reproductive performance parameters of Japanese quail's hens. J. Adv. Agric. Technol., 3(2): 132-135. <https://doi.org/10.18178/joaat.3.2.132-135>
- Zhang Z, Hu W, Li B, Chen R, Shen W, Guo H, Guo H, Li H (2019). Comparison of viremia, cloacal virus shedding, antibody responses and pathological lesions in adult chickens, quails, and pigeons infected with ALV-A. Sci. Rep., 9(3027): 1-9. <https://doi.org/10.1038/s41598-019-39980-y>