

Case Report



An Outbreak of Parasitic Infection Due to Nutritional Deficiency in Goats

MUHAMMAD HARIS RAZA FARHAN^{1*}, QAMAR IQBAL¹, TARIQ JAMIL¹, MUHAMMAD FAYAZ², ABDUL KABIR^{2,3}, EID NAWAZ², MARJAN ALI², SHUMAILA MANZOOR²

¹Faculty of Veterinary Science, University of Agriculture, Faisalabad, Pakistan- 38000; ²National Veterinary Laboratory, Islamabad, Pakistan- 44000; ³Department of Veterinary Microbiology, Sindh Agriculture University, Tandojam-Pakistan- 70060.

Abstract | Nutritional management of animals has a direct effect on the health status of the herd. The unavailability of important nutrients can affect the immune system of the animals increasing their susceptibility to different infections including parasitic infestation. A referral clinical examination was carried out on a small ruminant farm with a mixed population of sheep and goats. History taken from the farm owner revealed the mortality of 8 animals within the duration of 14 days following a pattern of anorexia, no fever, emaciation, recumbency, and ultimately death. A detailed physical and clinical examination of animals revealed signs of dehydration, emaciation, anorexia, nutritional stress, and high fever in animals. Tick infestation was found on the skin of animals while *Babesia* was found in the blood smears of some animals. Pox-like lesions were also found on the skin of some goats.

Keywords | Parasitic infections, *Babesia*, Malnutrition, Worm infestation, Stress


Received | May 24, 2022; **Accepted** | June 18, 2022; **Published** | June 30, 2022

***Correspondence** | Muhammad Haris Raza Farhan, Faculty of Veterinary Science, University of Agriculture, Faisalabad, Pakistan; **Email:** Harisraza524@gmail.com

Citation | Farhan MHR, Iqbal Q, Jamil T, Fayaz M, Kabir A, Nawaz E, Ali M, Manzoor S (2022). An outbreak of parasitic infection due to nutritional deficiency in goats. Res J. Vet. Pract. 10(2): 19-23.

DOI | <http://dx.doi.org/10.17582/journal.rjvp/2022/10.2.19.23>

ISSN | 2308-2798



Copyright: 2022 by the authors. Licensee ResearchersLinks Ltd, England, UK.

This article is an open access article distributed under the terms and conditions of the Creative Commons Attribution (CC BY) license (<https://creativecommons.org/licenses/by/4.0/>).

INTRODUCTION

Malnutrition is one of the major risk factors for illness and different infections including parasitic infections. It affects both pregnant and young animals by causing morbidity and mortality due to different reasons. There is a direct relationship between malnutrition or lack of nutrition and the death of animals sometimes leading to abortion in pregnant animals. Enterotoxaemia, pregnancy toxemia, urinary calculi, and other several diseases are associated with nutritional management (Oetzel and Garrett, 1988). Being an agriculture-based country, Pakistan has a large population of livestock including cattle, sheep, goats, camels, and buffaloes. The sheep and goat populations are estimated to be about 31.6 million and 80.3 million respectively according to the economic survey of Pakistan 2020-21. The sheep and goat population contributed

to milk production by producing 41 and 991 thousand Tonnes of milk respectively, during the year 2020-21 (Pakistan Economic Survey, 2021). Sheep and goat production in Pakistan is being carried out mainly under nomadic and transhumant systems. However, commercial goat farming is also started in Pakistan and gaining huge popularity among goat farmers (Abubakar and Munir, 2014). Huge production and economic losses are faced by goat farmers due to the infestation of ticks as it leads to severe emaciation and a decline in milk production by goats. An appropriate tick control program should be implemented and ensured in developing countries including Pakistan in order to control tick infestations (Bansal, 2005). The frequent use of the same chemicals for the control of ticks is the major constraint in tick control because ticks are developing resistance against these chemicals. This chemical resistance of ticks is becoming the major contributing factor

to the failure of tick control programs in many areas (Bianchi et al., 2003). The impact of ticks on animals includes skin damage, wound development, irritation, and most importantly bloodsucking which leads to anemia in animals (Mkwanazi et al., 2021). Ticks play an important role as a vector for tick-borne diseases including babesiosis. The disease mechanism of babesiosis is associated with hemolytic anemia which occurs due to the destruction of erythrocytes either directly by the parasite itself or as a consequence of immune response against these parasites (Furlanello et al., 2005). Different species are classified on basis of their morphology. Fever, vascular hemolysis leading to anemia, hemoglobinuria, and jaundice are characteristic findings in the case of babesiosis (Solano-Gallego et al., 2016). In this case report, a clinical examination was carried out on an extensive goat farm for the mixed type of infections due to ticks (ectoparasites) and nutritional stress. Blood and fecal samples were collected from clinically and sub-clinically ill animals on the farm after complete physical examination. Blood samples were examined by making blood smears and fecal samples were examined for parasites under the microscope by simple floatation technique.

Table 1: Clinical signs and no. of animals affected

Clinical signs/ Findings	%/ No. of animals showing signs
Pox like lesions	15 animals (25%)
Pale mucous membranes	11 animals (18%)
Tick infestation	11 animals (18%)
Red urine	7 animals (15%)
Trichostrongylus spp. larvae in the fecal smears	3 animals (6%)
Ostertagia spp. eggs in the fecal smears	4 animals (8%)

MATERIALS AND METHODS/CASE PRESENTATION

A referral clinical examination was carried out on a small ruminant farm having 48 non-descript goats and 12 sheep located in the village “Chara Pani” near Murree, Pakistan on 31st March 2022. The history included mortality of 8 animals within 2 weeks following a pattern of anorexia, severe emaciation, mild form of diarrhea, and eventually death. History revealed deworming of animals with Nilzan® two weeks before the occurrence of clinical signs and morbidity. PPR vaccination was carried out after 7 days of deworming followed by ETV vaccination which was done after an interval of 10 days. The farm was reported to have complaints including morbidity of 35-40% (21-24 animals) with signs of severe anemia, emaciation, anorexia, rough hair coat, weight loss, dehydration, and mild diarrhea. The farm owner claimed to have no history

of temperature in animals. While maintaining sterile conditions, blood samples and fecal samples were collected from the clinically suspected sheep and goats. Blood samples were taken from the jugular vein in sterile vacutainers having anticoagulants in them. For fecal examination, fecal samples from the rectum were taken and preserved in sterile containers.

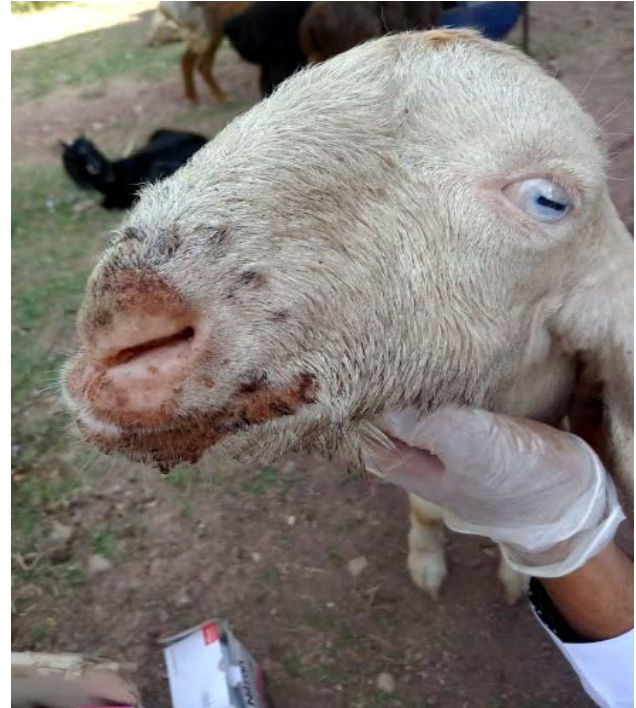

Figure 1: Pox like lesions in goat




Figure 2: Red urine

RESULTS AND DISCUSSIONS

Physical and clinical examination of animals revealed the occurrence of high fever (107°F and 105°F) in examined



Figure 3: Infestation of ticks

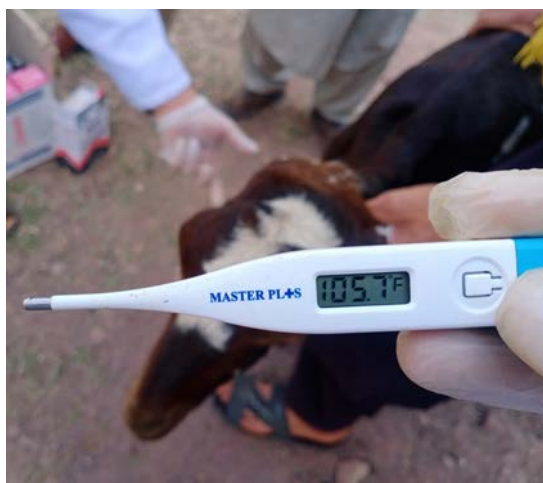

Figure 4: Fever (temperature 105.7°F)

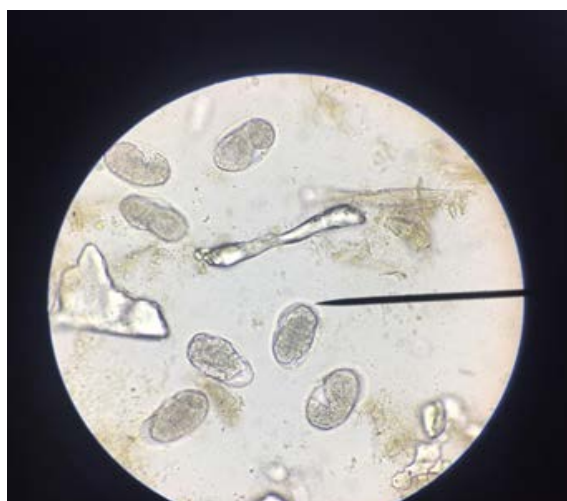

Figure 5: Oocytes of *Trichostrongylus*

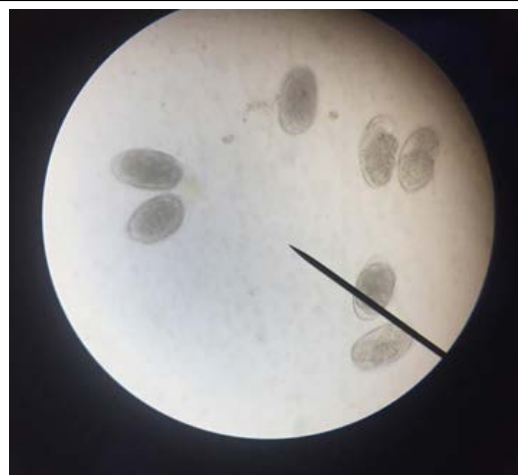


Figure 6: Oocytes of *Trichostrongylus*

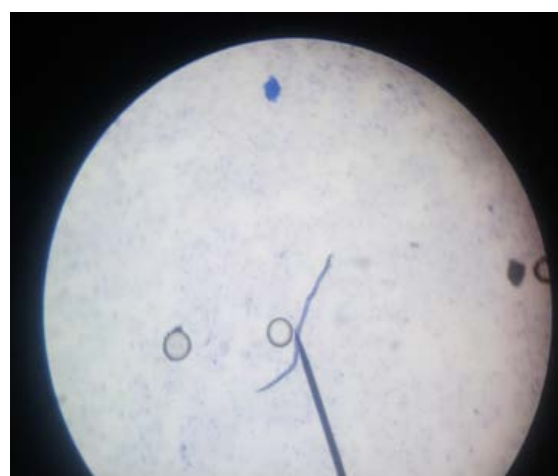

Figure 7: Larvae of *Trichostrongylus*

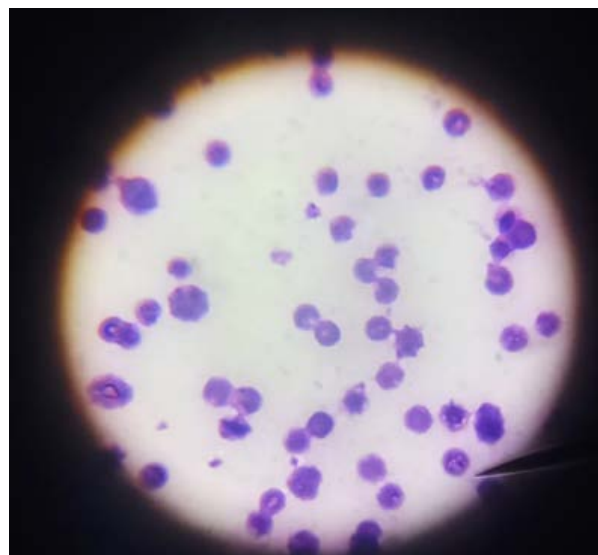


Figure 8: *Babesia* in blood smear

animals. The presence of goat pox was suspected in more than 25% of animals (15 animals) based on the pox lesions present near the oral and nasal regions which may relate to reduced feed intake of the goats (Hamdi et al., 2021).

Pale conjunctival membranes and heavy tick infestation were also found in about 18% of sheep and goats (11 animals) during complete body examination, which can be considered the major contributing factor towards the development of anemia. Similar findings were reported in a study by Ofukwu and Akwuobu et al. (2010). The goat with a history of severe emaciation, anemia, lateral recumbency, and red urine (hematuria) was found positive for babesiosis after making a blood smear. The above-mentioned clinical findings are the same which were discussed in another study. Nutritional stress due to malnutrition and ectoparasite infestations were the major causes of morbidity and mortality on the farm.

The fecal examination was carried out using simple floatation technique and larvae of trichostrongylus spp. were identified in 3 fecal smears when examined under the microscope. Moreover, the fecal examination also revealed the presence of eggs of ostertagia spp in 4 fecal samples. The nutritional status of the animals at the farm was not appropriate which imposed nutritional stress on the animals. The animals were fed once a day a small amount of fresh fodder and no concentrate was offered to them. This nutritional stress was known to be the main cause of poor body condition scoring of the animals at the farm leading to poor immune status and ultimately exposing the sheep and goats to increased ecto- and endo-parasitic infestations. Similar immune-related effects of malnutrition were observed and discussed by Paul et al. (2016).

Sheep and goat pox are considered important diseases of sheep and goats respectively due to the huge economic losses caused by them. The causative agent of goat pox falls into the genus *Capripoxvirus* (CaPV), in the subfamily *Chordopoxvirinae* and the family *Poxviridae* (King et al., 2016). The transmission of goat pox can occur either by contaminated respiratory droplets when they come in direct contact with animals or through indirect contact with vectors and contaminated environments (Sprygin et al., 2019). Depending upon the virulence of the viral isolate, the morbidity rate ranges between 10% and 85% while mortality rates range between 5% to 10% (Bhanuprakash et al., 2006). Goat pox is associated with signs like high fever and anorexia in the infected goats indicated by Pham et al. (2020) which were also observed in the goats examined in this report. The pox-like lesions were observed around the oral and nasal cavities in the present goats and similar pock lesions were found in another case report (Barua et al., 2017). Ticks are responsible for the transmission of *Babesia* and more than 100 spp. of *Babesia* are found to be affecting domestic animals. The clinical signs such as red urine, emaciation, and severe anemia were found in examined in 7 goats and these clinical signs for babesiosis are in accordance with the signs described by Taylor et al. (2007).

ACKNOWLEDGEMENTS

We are very thankful to the National Veterinary Laboratory Islamabad (NVL), Ministry of Food Security and Research (MNFSR), Pakistan for providing us the opportunity to conduct this case report. We are very grateful to Dr. Muhammad Abubakar (Senior Scientific Officer, NVL) for his kind guidance during the whole study.

CONFLICT OF INTERESTS:

The authors have no conflict of interest.

NOVELTY STATEMENT

According to our knowledge, no other farm report has been published particularly from this area to date. It is the first report from this area describing the impact of nutritional deficiency in causing parasitic infection outbreak in goats.

AUTHORS CONTRIBUTION

Farhan MHR, Iqbal Q., and Jamil T., wrote the report. Nawaz E., and Ali M., assisted in performing diagnostic tests in Laboratory. Manzoor S. and Kabir A. assisted in proofreading and editing the farm report.

REFERENCES

- Abubakar M., Munir M. (2014). Peste des petits ruminants virus: an emerging threat to goat farming in Pakistan. *Transbound. Emerg. Dis.* 61: 7-10. <https://doi.org/10.1111/tbed.12192>
- Bansal G. C. (2005). Bovine theileriosis in India: an overview. *Proc. Nat. Acad. Sci India.* 75: 134-143.
- Barua N., Sutradhar B. C., Chowdhury S., Al A., Sabuj M., Torab A., Sen A. (2017). A case report on management of goat pox of a doe in Rangamati, Chittagong. *J. Biomed. Multidiscipl. Res.*, 1(1): 31-36.
- Bhanuprakash V., Indrani B. K., Hosamani M., Singh R. K. (2006). The current status of sheep pox disease. *Comparative immunology, microbiology and infectious diseases*, 29(1): 27-60. <https://doi.org/10.1016/j.cimid.2005.12.001>.
- Bianchi M. W., Barré N., Messad S. (2003). Factors related to cattle infestation level and resistance to acaricides in *Boophilus microplus* tick populations in New Caledonia. *Vet. Parasitol.*, 112(1-2): 75-89. [https://doi.org/10.1016/S0304-4017\(02\)00415-6](https://doi.org/10.1016/S0304-4017(02)00415-6)
- Furlanello T., Fiorio F., Caldin M., Lubas G., Solano-Gallego L. (2005). Clinicopathological findings in naturally occurring cases of babesiosis caused by large form *Babesia* from dogs of northeastern Italy. *Vet. Parasitol.*, 134(1-2): 77-85. <https://doi.org/10.1016/j.vetpar.2005.07.016>
- Hamdi J., Bamouh Z., Jazouli M. et al (2021). Experimental infection of indigenous North African goats with goatpox virus. *Acta Vet. Scand.* 63: 9. <https://doi.org/10.1186/s13028-021-00574-2>

- King, A. M., Lefkowitz, E., Adams, M. J., & Carstens, E. B. (Eds.). (2011). *Virus taxonomy: ninth report of the International Committee on Taxonomy of Viruses* (Vol. 9). Elsevier.
- Mkwanazi M. V., S. Z. Ndlela, M. Chimonyo (2021). "Indigenous knowledge to mitigate the challenges of ticks in goats: A systematic review." *Vet. Anim. Sci.* 13 (2021): 100190. <https://doi.org/10.1016/j.vas.2021.100190>
- Oetzel, Garrett R (1988). "Protein-energy malnutrition in ruminants." *The Veterinary Clinics of North America. Food Anim. Pract.* 4.2: 317-329. [https://doi.org/10.1016/S0749-0720\(15\)31051-3](https://doi.org/10.1016/S0749-0720(15)31051-3)
- Ofukwu R, Akwuobu C (2010). Aspects of epidemiology of ectoparasite infestation of sheep and goats in Makurdi, North Central, Nigeria. *Tanzania. Vet. J.* 27: 36-42. <https://doi.org/10.4314/tvj.v27i1.62766>
- Pakistan Economic Survey (2020-21). https://www.finance.gov.pk/survey/chapters_21/02-Agriculture.pdf
- Paul B. T., Biu A. A., Ahmed G. M., Mohammed A., Philip M. H., Jairus Y. (2016). Point prevalence and intensity of gastrointestinal parasite ova/oocyst and its association with Body Condition Score (BCS) of sheep and goats in Maiduguri, Nigeria. *J. Adv. Vet. Parasitol.*, 3(3): 81-88. <https://doi.org/10.14737/journal.jap/2016/3.3.81.88>
- Pham T.H., Lila M.A.M., Rahaman N.Y.A., Lai H.L.T., Nguyen L. T., Van Do K., Noordin M. M. (2020). Epidemiology and clinico-pathological characteristics of current goat pox outbreak in North Vietnam. *BMC Vet. Res.*, 16(1): 1-9. <https://doi.org/10.1186/s12917-020-02345-z>
- Solano-Gallego L., Sainz Á., Roura X., Estrada-Peña A., Miró G. (2016). A review of canine babesiosis: the European perspective. *Parasit. Vectors.*, 9(1): 1-18. <https://doi.org/10.1186/s13071-016-1596-0>
- Sprygin A., Pestova Y., Wallace D. B., Tuppurainen E., Kononov A. V. (2019). Transmission of lumpy skin disease virus: A short review. *Virus Res.* 269: 197637. <https://doi.org/10.1016/j.virusres.2019.05.015>
- Taylor M. A., Coop R. L., Wall R. L. (2007). *Veterinary parasitology* (3rd ed.) Oxford: Blackwell Publishing, 553-555.